

Original Research Article

A comparative study of functional outcome of external fixation and volar plating in unstable distal radius fractures

Anil Kumar Mishra, Ajay Deep Sud, Manish Prasad*, Rajiv Kaul, Chander Mohan Singh

Department of Orthopaedics, Armed Forces Medical College, Pune, Maharashtra, India

Received: 08 December 2018

Revised: 15 January 2019

Accepted: 17 January 2019

***Correspondence:**

Dr. Manish Prasad,

E-mail: monu60@gmail.com

Copyright: © the author(s), publisher and licensee Medip Academy. This is an open-access article distributed under the terms of the Creative Commons Attribution Non-Commercial License, which permits unrestricted non-commercial use, distribution, and reproduction in any medium, provided the original work is properly cited.

ABSTRACT

Background: Distal radius fractures are amongst the most common injuries seen in the emergency department. It is imperative to restore the anatomy as much as possible in order to restore wrist function. Identifying a fracture as 'unstable' is critical in predicting the final outcome of treatment. The present study compares two primary modalities of treatment: external fixation and volar plating in terms of the functional outcome post-surgery. Aim of the study was to compare the functional outcome of fixation of unstable distal radius fractures by external fixation to that of volar plating by the Disabilities of the Arm, Shoulder and Hand (DASH) scoring system and analysis of recovery of grip strength and range of motion. Settings and design: Hospital-based; randomized control trial.

Methods: 80 patients presenting with unstable distal radius fractures were randomized into two groups of 40 each. One group received external fixation and the second received open reduction with volar plate fixation as the primary intervention. DASH scores were obtained and compared at specified time intervals following surgery.

Results: The results of our study show a better improvement in the mean DASH scores at 3, 6 and 12 months in the volar plating group as compared to the external fixation group.

Conclusions: Volar plating, with its definitive advantage of direct fracture visualization, has an overall better functional outcome with greater postoperative wrist motion and a lower incidence of complications.

Keywords: Unstable, Distal radius fractures, External fixation, Volar plating, Functional outcome, DASH score

INTRODUCTION

Distal radius fractures constitute 14% of all extremity injuries and 20% of all fractures treated in the emergency department.¹ They occur as a result of high or low energy trauma resulting in significant injury and impairment of function of the upper extremity. Intra-articular distal radius fractures are particularly difficult to treat and are more prone to an unsatisfactory functional outcome and early degenerative changes if accurate articular surface reconstruction is not achieved. Emphasis has thus shifted to restore the anatomy as much as possible by a method that does not compromise function.

Distal radial fractures are broadly classified based on their alignment and stability into (a) articular versus non-articular, (b) reducible versus irreducible and (c) stable versus unstable.

Fracture stability may be defined as the inability to resist displacement after an anatomical reduction. Irreducible or unstable fractures require stabilization by surgical means. Lafontaine et al. suggested several risk factors associated with fracture re-displacement after an initial satisfactory reduction, the presence of three or more indicating a high likelihood of fracture collapse namely: (a) dorsal angulation greater than 20°, (b) dorsal comminution, (c)

intra-articular involvement, (d) associated fracture of the ulna and (e) age over 60 years.²

Other parameters that are of paramount importance in predicting the development of post-traumatic osteoarthritis include restoration of articular congruity, axial compression of >2 mm and dorsal angulation >15°, associated intra-carpal lesions and intra-articular step-off >1 mm.³⁻⁶

A number of treatment options exist to counteract the loss of reduction in unstable distal radius fractures in which maintenance of anatomic reduction is a prime requisite. These include percutaneous pinning with casting, external skeletal fixation and open reduction and internal fixation (ORIF). We have limited our study to extra-articular or minimally articular unstable distal radius fractures and their management by either external fixation or volar plating. Fractures were deemed unstable if they had displaced after initial treatment with closed reduction and splinting or if three or more of Lafontaine's criteria were met.⁷

External skeletal fixation, with or without augmentation of K wires, has been long used for the treatment of unstable extra-articular and selected intra-articular distal radius fractures. It uses the principle of 'ligamentotaxis' for reduction and restoration of articular congruity. It is an effective modality of treatment, a number of studies reporting favourable results with its use.⁸⁻¹²

Open reduction and internal fixation with volar locking plates is the most common method of treatment used for unstable extra-articular fractures. The fixed angle locking device adds extra rigidity to the fracture site by acting as a single unit, thus preventing early collapse and malunion. Many studies have shown effective union and low complication rates with the use of these plates.^{7,13-16}

METHODS

The study was a randomized control, parallel group trial carried out over a period of two years from 2016 to 2018, conducted in the department of orthopaedics, Armed Forces Medical College, Pune. The trial was registered with Clinical Trials Registry India. The inclusion criteria were patients with: (a) unstable distal radius fractures-as described by Lafontaine et al.² (b) extra-articular and simple articular fractures-AO/OTA (Orthopaedic Trauma Association) type A2, A3, B1 and C1, and (c) age between 18 and 60 years. Patients with open fractures of distal radius, associated fractures of distal ulna, distal radio-ulnar joint (DRUJ) and carpal bones, pathological fractures of the distal radius due to primary tumour or bony metastasis, associated co-morbid conditions like uncontrolled diabetes mellitus, altered consciousness, immuno-compromised states and associated vascular injuries around the wrist were excluded from the study. From a review of previous literature, the calculated sample size for the purpose of the study was 40 each for

external fixation and volar plating.⁷ Allocation was done using sealed, blank, numbered envelopes containing the treatment assigned. The patients were aware of the selected treatment option prior to the surgery. Due to the obvious nature of the intervention and residual scars, the study was only partially blinded. The surgeons were not involved in the collection of the study data.

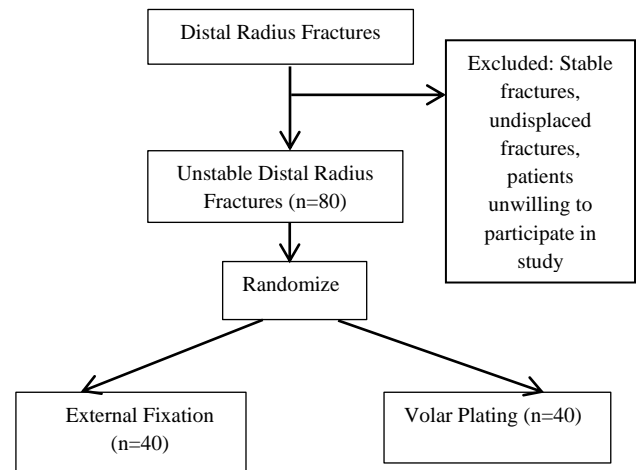


Figure 1: Randomization flow chart.

Study tools

A complete history taking and physical examination was carried out in all patients. Standard radiographs were obtained at the time of presentation (AP and lateral views) and fractures were classified according to the AO/OTA classification. All displaced fractures were initially managed with closed reduction and splinting. Radiological parameters including radial height, inclination, ulnar variance and volar tilt were measured on post reduction radiographs. Patients were reviewed at one week and re-assessed both clinically and radiologically for maintenance of reduction. Surgery was performed if the reduction was lost or if the fracture was unstable according to Lafontaine's criteria of instability.² Following randomization, patients were allotted to either of two groups A or B.

In Group A, we performed bridging external fixation using the universal mini external fixator system (UMEX) frame or the modular external fixator for distal radius with or without supplemental K wires. In group B, we have performed an open reduction internal fixation using 3.5 mm titanium locking compression plates (LCP) for distal radius.

Surgical technique for bridging external fixation

With the patient supine with the affected arm on the side table and fluoroscopic image intensifier in position, a preliminary reduction was performed for gross alignment of fracture fragments. A 2 cm longitudinal incision was given at the level of the mid radial shaft about 10 cm

proximal to the radial styloid and a minimum of 3 cm from the most proximal fracture line in order to avoid damage to the superficial branch of radial nerve (SBRN) which has an unpredictable course and is susceptible to damage from a blind procedure. The interval between the extensor carpi radialis brevis and longus muscles was used, such that the fixator lay in an oblique plane in relation to the horizontal plane of the forearm. After soft tissue retraction, two 4 mm Schanz pins were inserted manually across two cortices of the shaft parallel to each other after pre-drilling. A 1.5 cm longitudinal incision was made in the oblique plane over the second metacarpal distal to the flare of the metacarpal base. The extensor tendon and first dorsal interosseous muscle were reflected to allow exposure of the metacarpal shaft. With the metacarpophalangeal joint in a flexed position, two 3 mm Schanz pins were drilled across two cortices at an angle of 30-40° with the horizontal plane. Bi-cortical purchase of all pins was confirmed with fluoroscopy. The external fixator frame was first loosely applied to the pins; reduction was achieved by a combination of longitudinal traction, ulnar deviation, and dorsal or volar translation of the carpus relative to the shaft of the radius (Agee's manoeuvre).^{17,18} Pressure over the radial styloid was applied to achieve the radial length and inclination. Additional K wires were used in some cases to fix individual fracture fragments directly in order to prevent secondary displacement and also to obviate the need for extremes of positioning. Distraction of the carpus and radio-carpal joint was checked, and traction adjusted to ensure that the carpus was not over distracted. The K-wire pins were bent and cut and left out of the skin for easy removal at a later stage. The K wires were usually removed at 4 weeks and the fixator at 6 weeks.

Surgical technique for volar plating

With the patient placed supine and the arm extended on the hand table, a tourniquet was applied over the upper arm and inflated to 240 mm Hg. The approach used was a modified Henry's approach between the radial artery and FCR tendon. The FCR tendon was mobilized by incising the sheath and retracted in an ulnar direction. An incision was made in the floor of the tendon sheath exposing the flexor pollicis longus (FPL), which along with the median nerve was swept ulnarly by blunt dissection. The transverse muscle fibres of pronator quadratus were then released by an inverted 'L' shaped incision over the muscle and elevated subperiosteally from the radius in a volar direction. Reduction was done by longitudinal traction on the fingers by the assistant and volar flexion of the wrist. Each fragment was identified, disimpacted, and levered into position with the help of a narrow periosteal elevator. The flat palmar surface of the distal radius was used to apply the plate which was provisionally held in position with one screw in the oblong hole of the plate. Care was taken not to place the plate distal to the watershed line. The plate was secured after final positioning under fluoroscopic guidance using locking head screws which provide a relatively stiffer,

fixed angle construct. The pronator quadratus was not routinely closed to prevent fibrosis and restriction of motion.

Postoperatively for both groups, passive ranges of motion (ROM) exercises were initiated immediately which progressed to active ROM exercises for fingers, elbow, forearm and shoulder. Wrist physiotherapy was initiated at 6 weeks with strengthening exercises at 2 months.

Primary outcome

Disabilities of the Arm, Shoulder and Hand (DASH) score: A patient-reported outcome measure consisting of a 30 item questionnaire for upper extremity function based on a 100 point scale, with 0 indicating no disability and 100 points indicating maximum disability.⁷ A meaningful difference in the DASH score was estimated to be 10 points.^{19,20}

Secondary outcomes

Measurement of wrist dorsiflexion and volar flexion and radio-ulnar deviation, as well as forearm supination and pronation, was done using a goniometer. Forearm supination/pronation was assessed with patients arms by the side and elbow flexed to 90°. Grip strength was measured using a hand held dynamometer.²¹ The range of motion and grip strength were calculated as a percentage value of the contralateral uninjured side as these ratios are more sensitive for detecting changes.²² Values were also adjusted so as to reflect 10% greater strength for the dominant hand.²³

Statistical analysis

Data analysis was performed by using SPSS (Statistical package for social sciences) version 20.0. Significance was set at $p < 0.05$. All analyses were done using the intention to treat principle.

RESULTS

Demographic characteristics: No significant differences were observed in the mean age (in years), sex distribution, dominant side (handedness) and affected side between the two groups.

Primary outcome

There was a significant difference between mean DASH scores at 3 months ($p \leq 0.001$), 6 months ($p \leq 0.001$) and 12 months ($p \leq 0.001$) between the two groups with better scores obtained in the volar plating group.

Secondary outcomes

The percentage recovery of grip strength was higher in the volar plating group at 6 months ($p < 0.001$) and 12 months ($p < 0.001$). There was a significant difference in

mean dorsiflexion and volar flexion at 6 months ($p < 0.001$) and at 12 months ($p < 0.001$) between the two groups. There was a significant difference in mean radial deviation between the groups at 3 months ($p < 0.001$) but the differences were not significant at 6 and 12 months. There was a significant difference in mean ulnar deviation ($p < 0.001$) between the groups at 3 and 6 months but not at 12 months. Mean supination and pronation were significantly different at 3 months ($p < 0.001$) but not at 6 and 12 months. There was a significant difference between VAS scores at 3 and 6 months but not at 12 months. However, there was no significant difference in the proportion of complications in the two groups.

Table 1: Demographic characteristics.

	External fixation (n=40) Mean (SD)	Volar plating (n=40) Mean (SD)	Total	P value
Age (years)	38.35 (11.79)	36.95 (10.23)	80	0.572
Sex				
Male	32	31	63	0.999
Female	8	9	17	
Dominant hand				
Left	5	11	16	0.162
Right	35	29	64	
Affected side				
Left	13	22	35	0.071
Right	27	18	45	

Table 2: The disabilities of arm, shoulder and hand score (DASH).

	External Fixation (n=40)		Volar Plating (n=40)		P value	Favouring
	Mean	SD	Mean	SD		
Baseline	75.68	5.09	74.85	4.26	0.434	
3 months	23.90	4.28	16.30	3.35	<0.001	Volar plating
6 months	12.48	2.47	6.98	2.52	<0.001	Volar plating
12 months	4.40	2.09	1.00	1.75	<0.001	Volar plating

Table 3: Recovery of mean grip strength at 3, 6 and 12 months.

Grip Strength	External fixation (n=40)		Volar plating (n=40)		P value	Favouring
	Mean	SD	Mean	SD		
3 months	49.53	6.99	70.03	2.95	0.434	
6 months	73.40	5.61	87.93	4.07	<0.001	Volar plating
12 months	88.70	3.62	94.05	1.92	<0.001	Volar plating

Table 4: Pain scores assessment on Visual Analogue Scale (VAS).

VAS	External fixation (n=40)			Volar plating (n=40)			P value
	Min	Max	Median	Min	Max	Median	
3 months	2	5	4	1	3	2	<0.001
6 months	0	2	2	0	1	0	<0.001
12 months	0	0	0	0	0	0	-

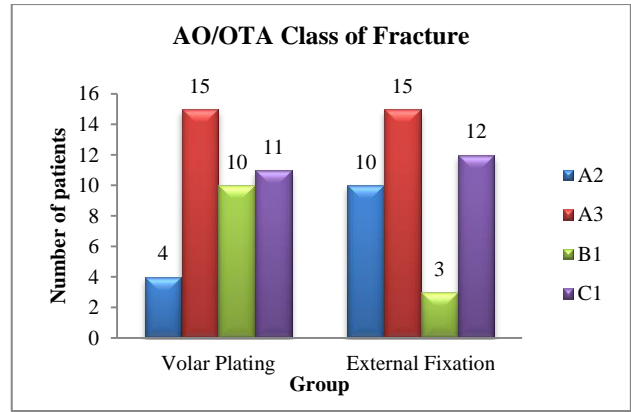


Figure 2: Distribution of class of fracture (AO/OTA classification) between the two groups.

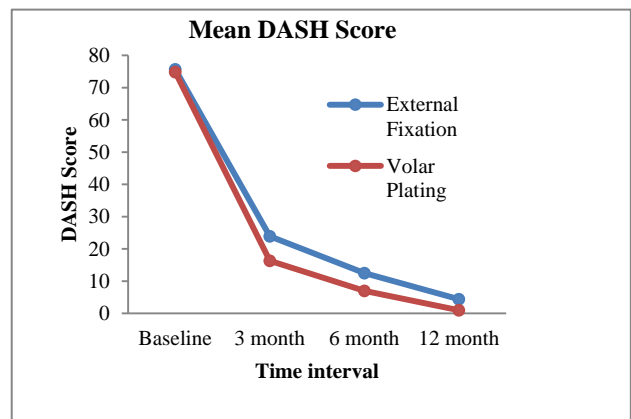


Figure 3: Mean DASH score graph.

Table 5: Range of motion analysis at 3, 6 and 12 months.

	External Fixation		Volar Plating		P Value	Favouring
	Mean	SD	Mean	SD		
3 months						
Dorsiflexion	39.88	3.30	41.13	2.11	0.048	Volar Plating
Volar flexion	43.63	4.08	44.88	3.49	0.145	
Radial deviation	10.13	2.65	12.50	2.53	<0.001	Volar Plating
Ulnar deviation	19.75	1.94	22.63	2.53	<0.001	Volar Plating
Supination	70.13	3.10	71.38	2.26	0.043	Volar Plating
Pronation	75.75	2.67	77.63	2.53	0.002	Volar Plating
6 months						
Dorsiflexion	67.50	4.24	71.88	2.45	<0.001	Volar Plating
Volar flexion	72.75	4.52	78.75	2.19	<0.001	Volar Plating
Radial deviation	17.25	2.52	18.13	2.45	0.119	
Ulnar deviation	29.75	1.94	32.75	2.52	<0.001	Volar Plating
Supination	79.38	1.67	79.88	0.79	0.093	
Pronation	88.13	2.70	89.13	1.92	0.061	
12 months						
Dorsiflexion	78.30	2.62	80.00	0.00	<0.001	Volar Plating
Volar flexion	86.38	3.39	89.13	1.92	<0.001	Volar Plating
Radial deviation	23.50	2.32	24.00	2.03	0.308	
Ulnar deviation	42.73	3.10	43.75	2.19	0.092	
Supination	80.75	2.67	82.00	4.05	0.108	
Pronation	89.75	1.10	89.88	0.79	0.562	

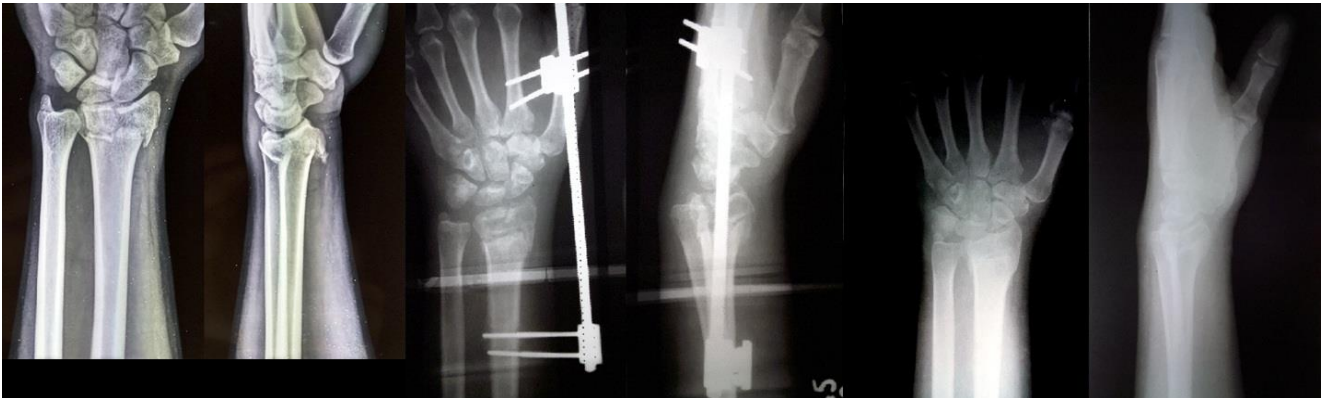

Figure 4: Pre OP, immediate post OP and 6 months post OP X-rays-external fixation.

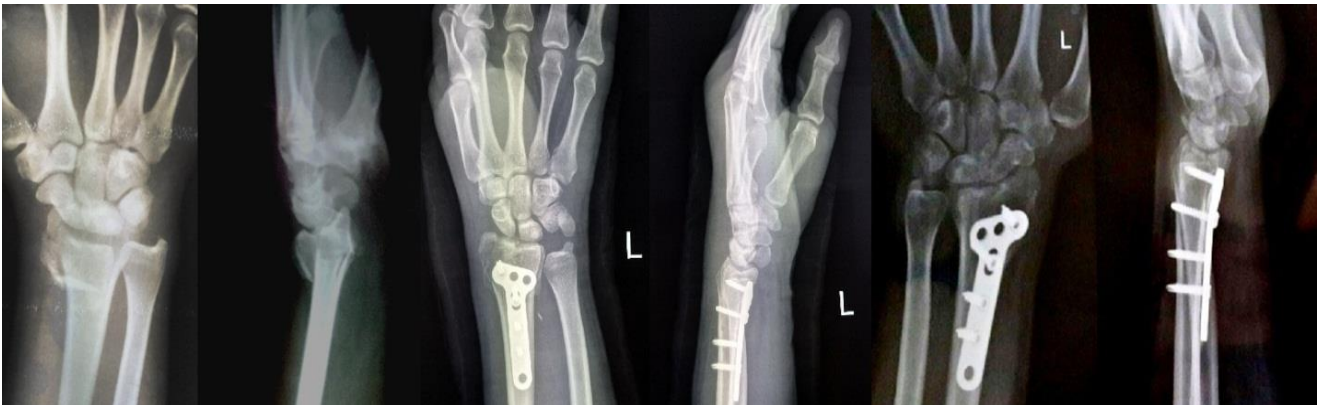

Figure 5: Pre OP, immediate post OP and 6 months post OP X-rays-volar plating.

Table 6: Post-operative complications in both groups.

Complication	Group		Total
	External fixation	Volar plating	
Stiffness	3	2	5
Superficial pintract infection	3	0	3
Surgical site infection	0	2	2
CRPS	1	0	1
Extensor tendon irritation	0	1	1
Loss of reduction	1	0	1

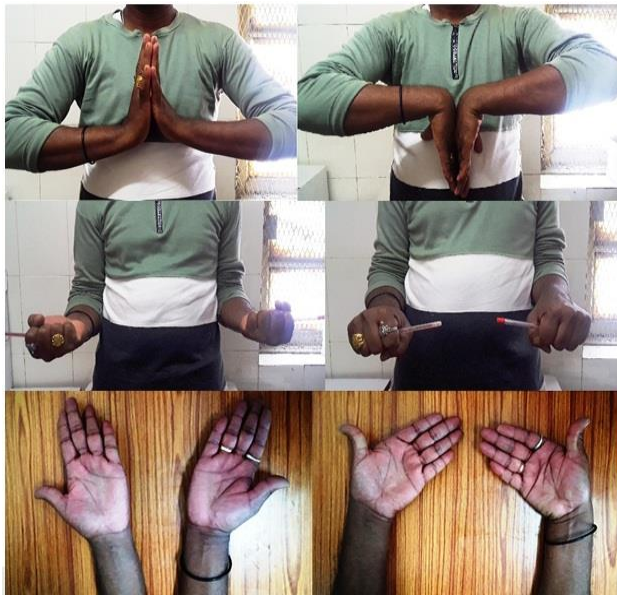

Figure 6: Range of motion (ROM) at 1 year following external fixation.



Figure 7: Range of motion (ROM) at 1 year following volar plate fixation.

DISCUSSION

Both bridging external fixation and open reduction and volar plating are currently being performed for the fixation of unstable distal radius fractures. There are several advantages and disadvantages of both the methods. External fixation is a relatively simpler yet effective means of achieving length and maintaining the reduction in the desired position by using the principle of ligamentotaxis. The intact joint capsule and ligaments transmit the forces of distraction to the bony fragments thereby maintaining the reduction and preventing a late collapse of the fracture fragments. The addition of supplemental K wires increases the stability of the construct and prevents secondary displacement of the fracture fragments. However, the procedure is limited by its inability to directly reduce and align the intra-articular fragments thereby precluding its use in complex intra-articular fractures. It is also ineffective in achieving and maintaining the reduction in shear fractures involving the dorsal or volar rim (Barton fractures). Complications of this procedure include pin site infections, superficial radial nerve neuropathy, over distraction leading to finger pain and stiffness and arthritic changes in the radio-carpal joint.²⁴

Open reduction and internal fixation has the definitive advantage of direct visualization of fracture fragments resulting in a better reduction and an earlier resumption of wrist movements. Barriers to reduction such as small comminuted fragments and soft tissue interposition can also be addressed. However, the procedure is associated with its own complications such as tendonitis and tendon ruptures, median nerve neuropathy, surgical site infections and hardware complications.²⁴

In a similar study conducted by Wilcke et al, 33 patients were randomized to volar plating and 30 to external fixation. The patients in the volar plating group had a significantly better DASH score than those in the external fixation group at 3 and 6 months, but at 12 months the differences reduced and were no longer significant.¹³ The grip strength and range of motion were also better in the volar plating group but the differences decreased with time. In another study by Wei et al comparing the subjective functional outcome following fixation of unstable distal radius fractures by external fixation, volar plating and radial column plating, the mean DASH score

at the end of 3 months was significantly higher in the volar plating group than the other two groups. However, the mean DASH score at 6 months and 12 months for the volar plating group was not significantly different from either of the other two groups.⁷ The percentage of grip strength recovered was significantly higher in the external fixation group at 6 months than the internal fixation group. No significant differences were found in the range of motion analysis between the groups. Pain scores recorded on VAS did not show any significant differences.

In another recent study conducted by Venkatesh Gupta et al comparing bridging external fixation with volar plating for unstable, comminuted distal radius fractures, it was concluded that volar fixation results in a quicker recovery of wrist function with better DASH scores and a greater post-operative range of motion as compared to the external fixation group at 1 year.²⁵ Pain scores were not significantly different for the two groups.

A meta-analysis by Walenkamp et al showed a better functional outcome of unstable distal radius fractures treated with volar plating as compared to external fixation with better DASH scores in the plating group at 3, 6 and 12 months.²⁶ For secondary outcomes such as grip

strength and range of motion, no significant differences were obtained. In a meta-analysis by Wang et al., significantly better DASH scores were reported at 3, 6 and 12 months for ORIF as compared to external fixation.²⁷ Grip strength was significantly better for the ORIF group at 3 months but at 6 and 12 months the difference was not significant. Range of motion analysis showed better volar flexion at 6 months, dorsiflexion at 3 and 6 months and supination at 3 months for volar plating. Another recent meta-analysis by Li Hai et al revealed that volar locked plating resulted in significantly lower DASH score as compared to external fixation at 3, 6 and 12 months following surgery.²⁸ Furthermore, dorsiflexion, supination and grip strength were found to be significantly better with volar plating. A meta-analysis by Wei et al showed significantly better DASH scores and forearm supination for ORIF as compared to external fixation. However, recovery of grip strength was significantly better with external fixation.¹⁵ A meta-analysis by Eposito et al suggested significantly lower DASH scores and reduced infection rates for ORIF as compared to external fixation. There were no significant differences in the range of motion, grip strength and complication rates other than infection in the two modalities.¹⁶

Table 7: Mean DASH scores of external fixation and volar plating in various studies.

Study by:	External fixation			Volar plating			P value				
	Sample size (n):	3 months	6 months	1 year	Sample size (n):	3 months	6 months	1 year	3 months	6 months	1 year
1. Wilcke et al. ¹³	30	27	14	11	33	9	6	7	<0.001	0.008	0.1
2. Wei et al. ⁷	22	29	11	18	12	7	6	4	0.028	-	0.025
3. Venkatesh Gupta et al. ²⁵	14	-	-	23	16	-	-	9	-	-	0.015
4. Egol et al. ¹¹	38	25.4	32.6	17.2	39	19.5	25.0	13.0	0.10	0.06	0.15
5. Our study	40	23.9	12.48	4.40	40	16.30	6.98	1.00	<0.001	<0.001	<0.001

Similar to the above studies, the results of our study show a better improvement in the mean DASH scores at 3, 6 and 12 months in the volar plating group as compared to the external fixation group. The percentage recovery of grip strength was significantly higher in the volar plating group at 12 months. The improvement in the range of dorsiflexion and volar flexion was significantly different in the two groups at 12 months, with better recovery in the volar plating group. There was a significant difference in the VAS scores at 3 and 6 months between the two groups with lower VAS scores in the volar plating group. Incidence of complications was lower in the volar plating group as compared to the external fixation group but the difference was not significant. These results suggest that volar plating is more effective in terms of achieving a better subjective outcome with the added advantage of low rates of complications as compared to external fixation for unstable distal radius fractures.

Limitations of the study: This study had several limitations. Firstly, we recruited only those many patients as we deemed necessary for detecting a change in the primary outcome, the DASH score. Blinding could not be done due to the obvious nature of the intervention. Furthermore, the period of follow up was kept limited to 12 months. A longer follow up would have been more appropriate in evaluating potential complications like development of arthritis of the wrist joint. Lastly, radiological assessment, although done at every follow up, was not included as a part of the study.

CONCLUSION

There exist a number of factors that influence the stability of a distal radius fracture. Identifying these factors is the most critical step, that may often be missed, which ultimately predicts the outcome of treatment. Since these fractures have a high propensity to re-displace following

a conservative trial of closed reduction and casting, they should be preferably stabilized surgically. Both external fixation with or without additional K wires and open reduction and volar plating are an effective means of achieving fracture union along with restoration of wrist function. Volar plating, with its definitive advantage of direct fracture visualization, has an overall better functional outcome with greater postoperative wrist motion and a lower incidence of complications. The fixed angle locking plates provide a stiffer construct thereby minimizing the chances of fracture displacement. External fixation, although a simpler, less expensive and minimally invasive procedure, fails to meet up to the versatility provided by volar plates in terms of their applicability to a wide range of fracture patterns and their effectiveness in enabling immediate postoperative motion. Hence, volar plating is definitely the preferred treatment option in the management of unstable distal radius fractures.

Funding: No funding sources

Conflict of interest: None declared

Ethical approval: The study was approved by the institutional ethics committee

REFERENCES

- Jupiter JB. Current concepts review: fractures of the distal end of the radius. *J Bone Joint Surg Am.* 1991;73(3):461-9.
- Lafontaine M, Delince P, Hardy D, Simons M. Instability of fractures of the lower end of the radius: apropos of a series of 167 cases. *Acta orthopaedica belgica.* 1989;55(2):203-16.
- Gartland J, Evaluation of healed Colles' fractures. *J Bone Joint Surg Am.* 1984;33:747-9.
- Trumble TE, Schmitt SR, Vedder NB. Factors affecting functional outcome of displaced intra-articular distal radius fractures. *J Hand Surg Am.* 1994;19(2):325-40.
- Lindau T, Arner M, Hagberg L. Intraarticular lesions in distal fractures of the radius in young adults: a descriptive arthroscopic study in 50 patients. *J Hand Surg Am.* 1997;22(5):638-43.
- Baratz ME, Des Jardins JD, Anderson DD, Imbriglia JE. Displaced intra-articular fractures of the distal radius: The effect of fracture displacement on contract stresses in a cadaver model. *J Hand Surg Am.* 1996;21(2):183-8.
- Wei DH, Raizman NM, Bottino CJ, Jobin CM, Strauch RJ, Rosenwasser MP. Unstable distal radial fractures treated with external fixation, a radial column plate, or a volar plate. A prospective randomized trial. *J Bone Joint Surg Am.* 2009;91(7):1568-77.
- Kapoor H, Agarwal A, Dhaon B. Displaced intra-articular fractures of distal radius: a comparative evaluation of results following closed reduction, external fixation and open reduction with internal fixation. *Injury.* 2000;31(2):75-9.
- Kreder H, Hanel D, Agel J, McKee M, Schemitsch E, Trumble T, et al. Indirect reduction and percutaneous fixation versus open reduction and internal fixation for displaced intra-articular fractures of the distal radius: a randomised, controlled trial. *J Bone Joint Surg Am.* 2005;87(6):829-36.
- Shukla R, Jain RK, Sharma NK, Kumar R. External fixation versus volar locking plate for displaced intra-articular distal radius fractures: a prospective randomized comparative study of the functional outcomes. *J Orthop Traumatol.* 2014;15(4):265-70.
- Egol K, Walsh M, Tejwani N, McLaurin T, Wynn C, Paksima N. Bridging external fixation and supplementary Kirschner-wire fixation versus volar locked plating for unstable fractures of the distal radius: a randomised, prospective trial. *J Bone Joint Surg Am.* 2008;90(9):1214-21.
- Navarro CM, Ahrengart L, Törnqvist H, Ponzer S. Volar locking plate or external fixation with optional addition of K-wires for dorsally displaced distal radius fractures: a randomized controlled study. *J Orthop Trauma.* 2016;30(4):217-24.
- Wilcke MK, Abbaszadegan H, Adolphson PY. Wrist function recovers more rapidly after volar locked plating than after external fixation but the outcomes are similar after 1 year: A randomized study of 63 patients with a dorsally displaced fracture of the distal radius. *Acta orthopaedica.* 2011;82(1):76-81.
- Walenkamp MM, Bentohami A, Beerekamp MSH, Peters RW, van der Heiden R, Goslings JC, et al. Functional outcome in patients with unstable distal radius fractures, volar locking plate versus external fixation: a meta-analysis. *Strategies in Trauma and Limb Reconstruction. Strategies Trauma Limb Reconstr.* 2013;8(2):67-75.
- Wei DH, Poolman RW, Bhandari M, Wolfe VM, Rosenwasser MP. External fixation versus internal fixation for unstable distal radius fractures: a systematic review and meta-analysis of comparative clinical trials. *J Orthop Trauma.* 2012;26(7):386-94.
- Esposito J, Schemitsch EH, Saccone M, Sternheim A, Kuzyk PR. External fixation versus open reduction with plate fixation for distal radius fractures: a meta-analysis of randomised controlled trials. *Injury.* 2013;44(4):409-16.
- Agee JM. Distal radius fractures. Multiplanar ligamentotaxis. *Hand clinics.* 1993;9(4):577-85.
- Agee JM, Szabo RM, Chidgey LK, King FC, Kerfoot C. Treatment of comminuted distal radius fractures: an approach based on pathomechanics. *Orthopedics.* 1994;17(12):1115-22.
- Hunsaker FG, Cioffi DA, Amadio PC, Wright JG, Caughlin B. The American academy of orthopaedic surgeons outcomes instruments: normative values from the general population. *JBJS.* 2002;84(2):208-15.
- Gummesson C, Atroshi I, Ekdahl C. The disabilities of the arm, shoulder and hand (DASH) outcome

- questionnaire: longitudinal construct validity and measuring self-rated health change after surgery. *BMC musculoskeletal disorders*. 2003;4(1):11.
21. Mathiowetz V, Weber K, Volland G, Kashman N. Reliability and validity of grip and pinch strength evaluations. *J Hand Surg*. 1984;9(2):222-6.
 22. MacDermid JC, Richards RS, Donner A, Bellamy N, Roth JH. Responsiveness of the short form-36, disability of the arm, shoulder, and hand questionnaire, patient-rated wrist evaluation, and physical impairment measurements in evaluating recovery after a distal radius fracture. *J Hand Surg*. 2000;25(2):330-40.
 23. Petersen P, Petrick M, Connor H, Conklin D. Grip strength and hand dominance: challenging the 10% rule. *Am J Occup Ther*. 1989;43(7):444-7.
 24. Richard MJ, Wartinbee DA, Miller M, Leversedge FJ, Riboh J, Ruch DS. Comparative analysis of the complication profile following palmar plating versus external fixation of fractures of the distal radius. *Clinic Rhinol*. 2010;1(1):1-7.
 25. Venkatesh Gupta SK, Mandapalli P. Comparative Study between Bridging External Fixation vs Volar Plating (Ellis-T Plate) for Comminuted Fracture of the Distal End Radius. 2015: 20-4.
 26. Walenkamp MM, Bentohami A, Beerekamp MS, Peters RW, van der Heiden R, Goslings JC, et al. Functional outcome in patients with unstable distal radius fractures, volar locking plate versus external fixation: a meta-analysis. *Strategies Trauma Limb Reconstr*. 2013;8(2):67-75.
 27. Wang J, Yang Y, Ma J, Xing D, Zhu S, Ma B, et al. Open reduction and internal fixation versus external fixation for unstable distal radial fractures: a meta-analysis. *Orthop Traumatol Surg Res*. 2013;99(3):321-31.
 28. Li-hai Z, Ya-nan W, Zhi M, Li-cheng Z, Hong-da L, Huan Y, et al. Volar locking plate versus external fixation for the treatment of unstable distal radial fractures: a meta-analysis of randomized controlled trials. *J Surg Res*. 2015;193(1):324-33.

Cite this article as: Mishra AK, Sud AD, Prasad M, Kaul R, Singh M. A comparative study of functional outcome of external fixation and volar plating in unstable distal radius fractures. *Int J Res Orthop* 2019;5:326-34.