

## Original Research Article

# Results of distal femur fractures managed by blade plate 95° at Brazzaville teaching hospital

Monka Marius\*, Bouhelo-Pam Kevin, Ohoya Etsaka Terence Olivier,  
Ngatsé Oko Albert, Moyikou Armand

Department of Trauma-Orthopedics, CHU-Brazzaville Teaching Hospital, Congo

**Received:** 10 July 2018

**Revised:** 28 August 2018

**Accepted:** 30 August 2018

**\*Correspondence:**

Dr. Monka Marius,

E-mail: [mar\\_monka@yahoo.fr](mailto:mar_monka@yahoo.fr)

**Copyright:** © the author(s), publisher and licensee Medip Academy. This is an open-access article distributed under the terms of the Creative Commons Attribution Non-Commercial License, which permits unrestricted non-commercial use, distribution, and reproduction in any medium, provided the original work is properly cited.

### ABSTRACT

**Background:** The objective of the study was to report the anatomical and functional results of distal femur fractures treated by blade plate 95° AO at CHU-Brazzaville.

**Methods:** This is a retrospective study of patients operated by blade plate for distal femur fractures between January 2012 and December 2016. Fourteen out of seventeen patients operated by blade plate met the inclusion criteria. Fractures of the distal femur were divided according to Chiron's classification. The anatomical and functional results were evaluated according to the analysis criteria of the SOFCOT 1988 round table.

**Results:** Of the 14 patients in our study, 8 were men and 6 were women. The average age was 35 (range 18 to 54). The fractures were consecutive to a road accident (n=13) and a fall in a gutter in 1 case. Bone healing was achieved in all our patients. The reduction was anatomic in 13 patients and in 1 patient there was a 10° angulation of the recurvatum type. According to the criteria of the SOFCOT 1988 round table, the results at the average follow-up of 12 months were judged very good in 7 patients, good in 3 patients, average in 1 patient and bad in 3 patients..

**Conclusions:** The results of our study confirm the performance of blade plate fixation in fractures of the distal femur. However, the other implants constitute a therapeutic arsenal of complex epiphyseal fractures of the distal femur, which should benefit trauma-orthopedics surgery wards for the management of all varieties of fractures of the distal femur.

**Keywords:** Distal femoral fractures, Blade plate, Brazzaville teaching hospital

### INTRODUCTION

Distal femur fractures, usually less encountered, located between the knee joint line and the line passing nine to fifteen centimeters above the knee, represent 4-6% of femoral fractures.<sup>1-4</sup> Their severity is related to the risk of repercussions on the function of the knee (stiffness, osteoarthritis) and the surgical necessity, to restore the anatomy of the femur and the articular profile when it is altered. To meet these specifications, surgical treatment remains the method of choice, along with early rehabilitation of the knee joint. New implants have been

proposed to treat these fractures, depending on age and various anatomical forms.<sup>5-8</sup>

The purpose of our work was to report the anatomical and functional results of these fractures managed by blade plate 95° AO (Association for the study of Osteosynthesis) with CHU-Brazzaville.

### METHODS

We designed a retrospective study of patients operated by blade plate, for fracture of the distal femur at Brazzaville

Teaching Hospital. Between January 2012 and December 2016, seventeen patients were operated by plate slide.

**Patients**

Patients with incomplete medical records and those with a follow-up of less than 6 months were excluded from the study. Fourteen patients were selected. Fractures of the distal femur were divided according to the Chiron classification because of its simplicity.<sup>9</sup> Data were collected and analyzed using windows excel.

**Surgical technique and postoperative care**

The intervention was performed in all patients under spinal anesthesia. A second-generation cephalosporin was administered for prophylaxis (cefuroxime 1.5 g per day intravenous) for 48 hours. After supine installation on an orthopedic table, a popliteal support was placed to correct the recurvatum tendency of the femur. The procedure was performed without the image intensifier. The ipsilateral iliac crest was systematically included in the operative field.

The approach was posterolateral without articular opening. After exposure and reduction of the fracture, the fixation was done according to the AO technique. A guide pin was placed accordingly as to respect the direction of the overlying femur and the angle 95° of the blade plate, 1.5 cm from the spacing line. After drilling the condylar mass with a conductive chisel, the plate was held by at least 4 cortical screws above the fracture site.

A cortico-cancellous graft was taken from the ipsilateral iliac crest in case of comminution, and affixed to the bone defect.

Postoperative care consisted in early mobilization by passive and active assisted knee rehabilitation the day after the intervention, with progressive strengthening of the periarticular musculature.

**Evaluation methods**

Anatomical and functional evaluation was performed by assessing the clinical and radiological results. For this, we used the analysis criteria of the round table of the SOFCOT of 1988.<sup>10</sup>

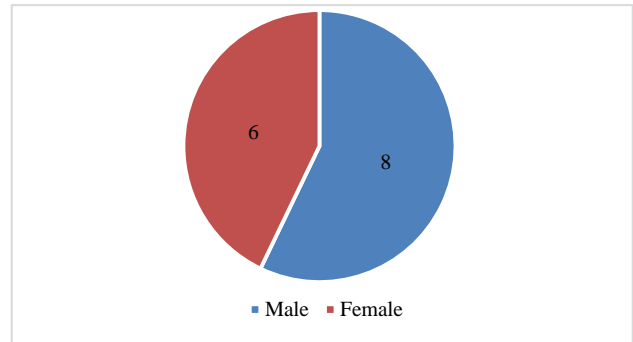
**RESULTS**

During this study period, 1,048 patients were hospitalized in our hip fracture department. Of these, 24 patients had fractures of the distal femur (2.3%) of all femur fractures.

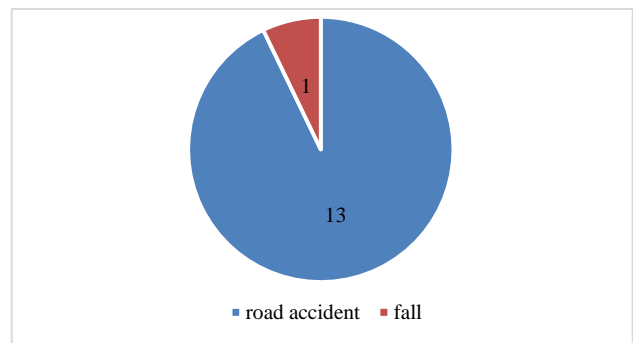
The plate slide was used in 17 patients, 70.8% of the cases. Fourteen of the 17 files were exploitable.

Figure 1 indicates patient distribution according to sex. Their average age ranged from 18 to 54 years. (35 mean)

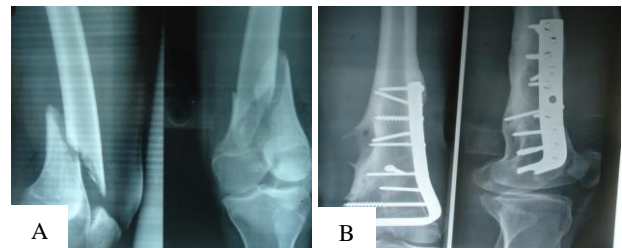
Figure 2 indicates patient distribution according to etiology. The fractures were the result of a road accident (n=13) and a fall in a gutter (n=1).



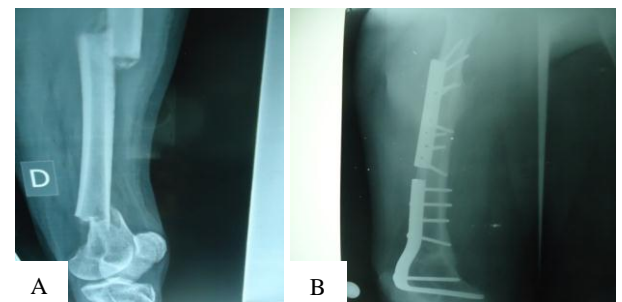**Figure 1: Patient distribution according to sex.**



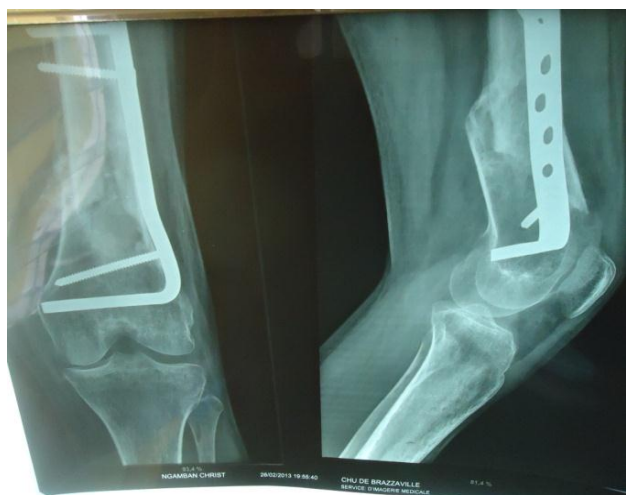**Figure 2: Patient distribution according to etiology.**



**Figure 3 (a and b): Supra and intercondylar fracture Chiron Group I4 before and after osteosynthesis blade plate 95° AO.**



**Figure 4 (A and B): Double fracture of the femur (supracondylar and diaphyseal) before and after double osteosynthesis by blade plate 95° AO and right plate AO.**



**Figure 5: Vicious recurvatum of 10° after osteosynthesis per blade plate 95° AO.**

Table I shows the distribution of the fourteen fractures according to the Chiron classification.<sup>9</sup>

**Table 1: Distribution of 14 fractures of the distal femur according to the Chiron classification.**

| Fracture groups   | Number    |
|-------------------|-----------|
| Chiron Group I1   | 2         |
| Chiron Group I2   | 4         |
| Chiron Group I4   | 1         |
| Chiron Group III1 | 1         |
| Chiron Group II2  | 6         |
| <b>Total</b>      | <b>14</b> |

No vasculo-nervous complication was observed at admission. The left side was 8 times and the right side 6 times.

The average operative time was 21 days with extremes ranging from 14 to 35 days.

From an anatomical point of view, bone healing was achieved in all our patients (Figures 2 and 3). The reduction was anatomic in 13 patients and in 1 patient there was a recurvatum-type 10° angulation (Figure 4). The average consolidation time was 4 months with extremes of 3 months and 7 months.

Functionally, there were 4 cases of knee stiffness with articular amplitudes between 60° and 90° and 3 cases with a flexion limitation of 40°. On the other hand, the articular amplitudes of the knee were normal in 7 patients.

Based on the 1988 SOFCOT roundtable criteria, results at the mean 12-month follow-up were rated very good in 7 patients, good in 3 patients, average in 1 patient, and poor in 3 patients.

## DISCUSSION

Our study is retrospective and monocentric with a reduced sample. However the study population is homogeneous, because all our patients were operated by a single technique although the choice of the surgical technique of fractures of the distal femur is not unequivocal.

We chose the 95° AO plate blade for the treatment of these 14 fractures of the distal femur because this material is available in our context and does not require the use of the image intensifier. For Marco et al, the plate blades offer excellent fixation and have the greatest resistance to angulation and torsion forces.<sup>11</sup> However, different fixation materials are used by other authors to stabilize fractures of the distal femur of various anatomical types.<sup>6,12-14</sup> The condylar plates and the plate screws are used by some authors in the epiphyseal fractures of the distal femur.<sup>6-8,12,15</sup> On the other hand, others use retrograde nails in fractures of the distal femur, especially in overlying fractures with total knee arthroplasty.<sup>16-18</sup> For Kim et al, retrograde nail with or without acrylic cement, appears to be a good surgical option for treating fractures of the distal femur on porous bone.<sup>16</sup> For these authors, the distal locking has a major impact on the anchoring of the implant in the porous bone and the acrylic cement prevents tearing of the locking screw. Antegrade nails are also used in simple supra-condylar fractures.<sup>7,17</sup>

The main complications found in the literature are knee stiffness, varus deformities, especially in supra- and inter-condylar fractures.<sup>6,13</sup> In our study, joint stiffness was related to delayed therapy and inadequate knee rehab. Other studies report cases of pseudarthrosis and infection of the knee, especially after surgery with joint opening.<sup>17,18</sup>

Functional rehabilitation is a fundamental therapeutic supplement in the postoperative management of patients because obtaining an anatomical reduction without postoperative rehabilitation does not always imply good management.

## CONCLUSION

The results of our study confirm the performance of plaque plate fixation in fractures of the distal femur, classified as group I and group II of Chiron. However, this material is not an ideal implant for the stabilization of comminuted epiphyseal fractures of the distal femur. The other implants (screws-plates, condylar plates and retrograde or antegrade nails) constitute a therapeutic arsenal of the complex epiphyseal fractures of the distal femur, which should benefit trauma-orthopedics surgery wards in the management of all other varieties of these fractures.

*Funding: No funding sources*

*Conflict of interest: None declared*

*Ethical approval: The study was approved by the institutional ethics committee*

## REFERENCES

1. Batchlor E, Heal C, Kimberly Haladyn J, Drobetz H. Treatment of distal femur fractures in a regional Australian hospital. *World J Orthop.* 2014;5(3):379-85.
2. Stover M. Distal femoral fractures current treatment results and problems. *Injury.* 2001;32 suppl 3:SC3-S13.
3. Kolmert L, Wulff K. Epidemiology and treatment of distal femoral fractures in adults. *Acta Orthop Scand.* 1982;53(6):957-62.
4. Martinet O, Cordey J, Harder Y, Maier A, Buhler M, Barraud GE. The épidemiology of fractures of the distal femur? *Injury.* 2000;31 Suppl 3:C62-3.
5. Foster MC, Komarsamy B, Davison JN. Distal femoral fractures a review of fixation methods. *Injury.* 2006;37:97-108.
6. Chun-Jui Weng, Chi-Chuan Wu, Kuo-Fun Feng et al. Comparison of supra-intercondylar and supracondylar femur fractures treated with condylar buttress plates. *BMC Musculoskelet Disord* 2016;17:413.
7. Ehlinger M, Ducrot G, Adam P, Bonnemet F. Distal femur fractures. Surgical techniques and a review of the literature. *Orthop Traumatol: Surg Res.* 2013;99:353-360
8. Vandebussche E, LeBaron M, Ehlinger M, Flecher X, Pietu G, SOFCOT. Blade-Plate fixation for distal femoral fractures: A case-control study *Orthop Traumatol: Surg and Res.* 2014;100:555-60.
9. Chiron P. Teaching Conferences SOFCOT. 1995;1(52):147-66.
10. Asencio G. Fractures of the distal femur. Round table of the SOFCOT. *Rev Chir Orthop* 1988;75(suppl.1):168-83.
11. Andrade MAP, Rodrigues AS, Mendonça CJ, Portela LGS. Fixation of supracondylar femoral fracture:a biomechanical analysis comparing 95° blade plates and dynamic condylar screws(DCS). *Rev Bras Orthop.* 2010;45(1):84-8.
12. Liang B, Ding Z, Shen J, Zhai W, Kang L, Zhou L, et al. A distal femoral supra-condylar plate: biomechanical comparison with condylar plate and first clinical application for treatment of supracondylar fracture. *Int Orthop.* 2012;36(8):1673-9.
13. Sié Essoh JB, Mobiot CA, Traoré A, Lambin Y. Distal femoral fractures treated with condylar buttres plate in a West African hospital. *J Clin Orthop Trauma.* 2012;3(2):98-102.
14. Henderson CE, Lujan T, Bottlang M Fitzpatrick DC, Madey SM, Marsh JL. Stabilization of distal femur fractures with intramedullary nails and locking plates: differences in callus formation. *Lowa Orthop J.* 2010;30:61-8.
15. Pascarella R, Bettuzzi C, Bosco G, Leonetti D, Dessì S, Forte P, et al. Results in treatment of distal fractures using polyaxial locking plate. *Strategies. Trauma Limb Reconstr.* 2014;9(1):13-8.
16. Kim J, Kang SB, Nam K, Rhee SH, Won JW, Han HS. Retrograde intramedullary nailing for distal femur fracture with osteoporosis. *Clin Orthop Surg.* 2012;4(4):307-12.
17. Kumar A, Jasani V, Butt MS. Management of distal femoral fractures in elderly patients using retrograde titanium supracondylar nails. *Injury Int J.* 2000;31:169-73.
18. Handolin L, Pajarinen J, Lindahl J, Hirvensalo E. Retrograde intramedullary nailing in distal femoral fractures-Results in a series of 46 consecutive operations. *Injury Int J.* 2004;35:517-22.

**Cite this article as:** Marius M, Kevin BP, Olivier OET, Albert NO, Armand M. Results of distal femur fractures managed by blade plate 95° at Brazzaville teaching hospital. *Int J Res Orthop* 2018;4:810-3.