

## Original Research Article

# Results of bridging LCP along with corticocancellous autogenous bone graft and calcium hydroxyapatite blocks in gap nonunion of long bones

Ankur Agarwal\*

Department of Orthopaedics, SSPHPGTI, Noida, Uttar Pradesh, India

**Received:** 17 June 2018

**Revised:** 17 July 2018

**Accepted:** 19 July 2018

**\*Correspondence:**

Dr. Ankur Agarwal,

E-mail: [drankur@gmail.com](mailto:drankur@gmail.com)

**Copyright:** © the author(s), publisher and licensee Medip Academy. This is an open-access article distributed under the terms of the Creative Commons Attribution Non-Commercial License, which permits unrestricted non-commercial use, distribution, and reproduction in any medium, provided the original work is properly cited.

### ABSTRACT

**Background:** High-energy trauma is an important cause of compound fractures of long bones that in turn results into bone gap due to bone loss or high comminution with resultant displacement of minute fracture fragments and hence non-union. Bone resorption or surgical excision for infection or tumour also leads to gap non-unions.

**Methods:** Forty-one patients having fracture of long bones of extremities with a bone gap of upto 2 inches were enrolled and were treated with autogenous bone grafting and calcium hydroxyapatite (CHA) blocks along with fixation by a locked compression plate (LCP) and plaster slab. The average follow-up period was ten months. One patient was excluded from the study due to drop out from follow up.

**Results:** In 23 (57.5%) patient's radiological union occurred by 24-26 weeks. In 16 (40%) patients, radiological union was seen between 26-28 weeks, while in one (2.5%) patient union was seen at 30 weeks. Also, it was seen that smaller the length of gap, the faster was the union. Excellent results were seen in the majority of 25 patients (62.5%), good results in 11 patients (27.5%), fair results in 3 patients (7.5%) and poor outcome in 1 patient (2.5%). Also, it was seen that smaller the gap size, better was the outcome.

**Conclusions:** The technique of bridge plating using internal fixator i.e. LCP along with autogenous corticocancellous bone graft and CHA blocks is a fairly good technique to treat gap non unions. It has its own advantages of avoiding complications associated with large external frame constructs. However, larger gap size limits the usefulness of this technique.

**Keywords:** Gap nonunion, Calcium hydroxyapatite, Locked compression plating, Corticocancellous bone grafting

### INTRODUCTION

Bone defects or gaps in long bones can arise because of various causes. Open fractures can result in bone gaps due to bone loss. Bone loss may occur from extrusion of fragments at the time of injury or during debridement of an open fracture when devitalized segments of bone are removed, thereby creating a defect. In cases of blunt trauma, most skeletal defects are created at the time of debridement, but in cases of penetrating trauma due to gunshot or blast injuries, extrusion of bone fragments can occur at the time of injury. High energy trauma and

gunshot injuries can also result in high degree of comminution and thus, bone defects. Systems for classification of open fractures do take some account of bone loss, but are not entirely representative because of consideration of many factors. Bone resorption as in atrophic nonunion or excision for infections (sequestrum) and tumours can also result in bone defects.<sup>1,2</sup>

Usually, bone loss is described by its anatomical location in the bone as being diaphyseal, metaphyseal or articular. The extent of the defect can be considered in terms of the length of bone involved. These defects can range from

few millimetres to several inches. Also, the defect can be partial or segmental circumferential loss. Those involving upto more than 50% of the circumference can heal spontaneously but often require additional treatment to restore normal volume and strength. Segmental defects of greater than 2 cm are unlikely to heal spontaneously following skeletal stabilisation alone. Although these considerations are important, other factors also influence the prognosis. Bone loss in certain anatomical locations has a more favourable prognosis due to better blood supply and corresponding osteogenic potential.<sup>3</sup> The degree of soft-tissue injury will have a substantial influence on the subsequent rate of healing. The age of the patient, the presence of chronic disease and tobacco usage may alter the potential of bone defects to heal. The way in which these fractures are treated will have a substantial influence on quality of the osteogenic response and final outcome.<sup>4</sup> Whereas shortening by acute docking can be done for small gaps of few millimetres or few centimetres in some cases, it may not be desirable in many circumstances. Various methods have been tried by various researchers to bridge these bone defects, thus, created.

The aims and objectives of this study was to assess the results of surgically treating gaps in long bones by use of bridge LCP along with corticocancellous autogenous bone graft and CHA blocks..

## METHODS

A prospective interventional study was conducted at Sarojini Naidu Medical College and Hospital, Agra from June 2005 to March 2008. Ethical approval was taken from the research ethics / postgraduate thesis approval committee of the institute.

### Inclusion criteria

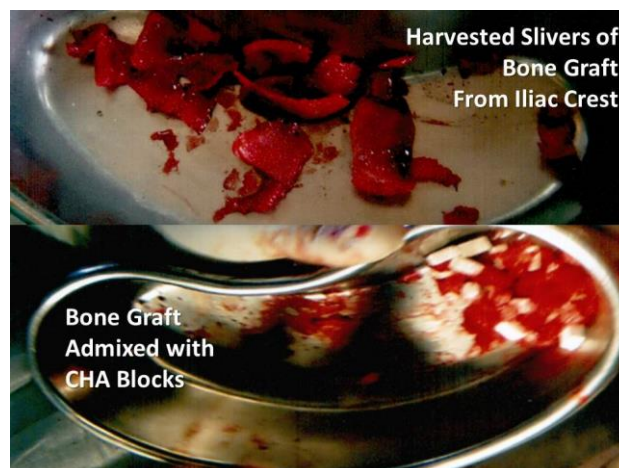Inclusion criteria was all adult patients (>18 years age) attending outpatient department of orthopaedics with a bone gap/defect involving the diaphysis of long bone.

### Exclusion criteria

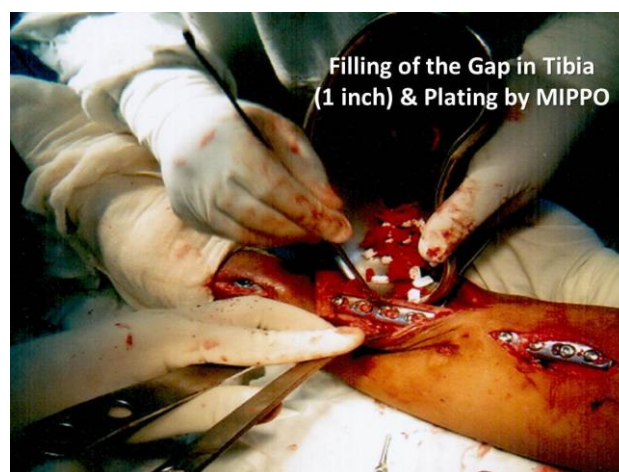
Exclusion criteria were bone defect more than two inches, chronic osteomyelitis of involved bone with active infection, bone defects with unhealed wound, bone void due to resection of epiphyseal end of long bone and patients with generalized skeletal disease/dysplasia. Forty-one patients were enrolled after prior informed consent to be a part of the study. Patient data was stored as per decided proforma.

Patients having bone defect as a result of bone loss due to open fractures were first managed so as to allow healing of wound by means of primary closure, delayed primary closure or skin flap. Provisional fracture stabilization and maintenance of length of bone was done by application of

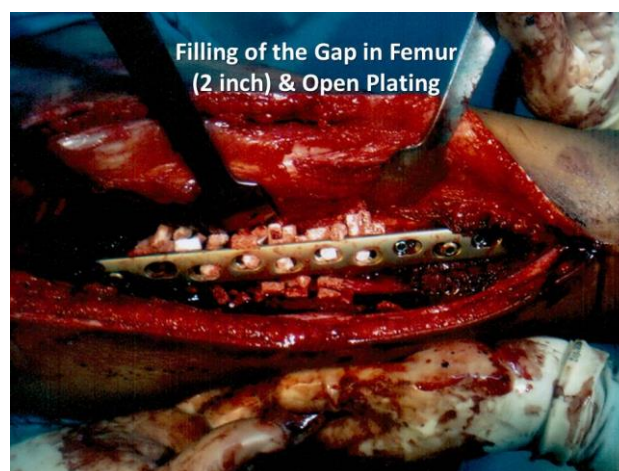plaster in case of open grade I/II fractures and application of external fixator in case of open grade III fractures.



**Figure 1: Autologous bone graft & CHA blocks.**



**Figure 2: Filling of gap in tibia (1 inch) and plating by MIPPO.**



**Figure 3: Filling of the gap in femur (2 inch) and open plating.**



**Figure 4: Calcium hydroxyapatite blocks.**

All the patients were treated in single stage by open reduction and internal fixation by bridging LCP. Iliac crest corticocancellous bone graft was harvested preferably from the ipsilateral side to reduce side morbidity (Figure 1). The gap was filled long chips (slivers) of autogenous iliac crest bone graft admixed with 1 pack (20 blocks of 1 cm×0.5 cm×0.5 cm) of CHA (Figures 2, 3). CHA is prepared from bovine bones. It is sterilized by gamma radiation and is easily available commercially (Figure 4). Calcium hydroxyapatite has been long used as a bone graft substitute.<sup>5</sup>

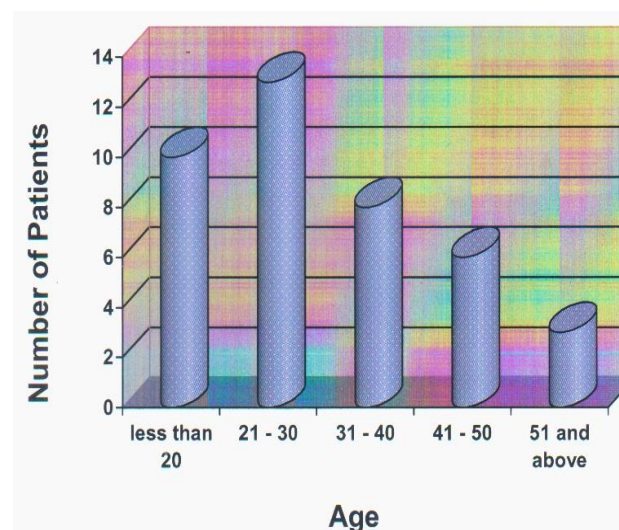
The surgical wound was closed over a negative suction drain which was removed after 48 to 72 hours. Patients were allowed non weight bearing walking with the help of axillary crutches or four post walker in case of lower limb surgery after drain removal. Patients were discharged on 5<sup>th</sup> or 6<sup>th</sup> postoperative day after conversion of intravenous antibiotics to oral antibiotics. Stitches were removed at 2 weeks post op. The operated limb was supported in a light plaster slab for initial 6 weeks. Further follow up was done at 6 weeks postop, 12 weeks postop, and thence, at successive 4 weekly intervals till complete fracture union. Average follow up period was 10 months. Full weight bearing without support or unrestricted use of upper limb depending upon the operated part was permitted only after fracture union and consolidation. Radiographs and clinical photographs were taken at each follow up along with clinical details as per proforma decided.

One patient was lost from follow up and was excluded from the analysis of results of the study.

## RESULTS

In this series, age range of the patients was from 18 years to 65 years. The highest number of patients was in third decade (Figure 5). Out of 40 cases, 34 patients were

males and six were females, male:female ratio being 6:1 approximately (Figure 6). Out of the total of 40 patients, in 37 patients (92.5%) lower limb was involved, whereas upper limb was involved in three cases (7.5%). Tibia was involved in maximum number of cases i.e. 24 (60%). Femur was involved in 13 patients (32.5%), humerus in two (5%) and ulna in 1 case (2.5%). We did not have any of the patients with gap nonunion of radius. Middle third of the shaft was involved in maximum number of cases i.e. 18 (45%), proximal third in 12 (30%) and distal third in 10 (25%) cases. In majority of cases 29 (72.5%), the cause of bone-gap was either a road traffic accident or a pedestrian accident and rest 11 (15%) of the injuries were either by gun shot or physical assault. Thus, in 35 (87.5%) cases the cause of bone gap was injury (Figure 7). In 5 (12.5%) cases the bone gap was due to excision of bone segment. Segmental removal of bone was done for benign growth (four cases) or sequestered bone (one case). Of the benign growths, three cases were of aneurysmal bone cyst and one case was of chondromyxoid fibroma. Out of 40 patients in the study, 35 patients had injury, all of which were of open fractures. Two cases (6%) were of Gustilo Anderson open grade I fractures, three (9%) were open grade II fractures, while 16 (45%) were open grade IIIa fractures, and 14 (40%) were open grade IIIb fractures. The remaining five patients had either tumour removal or sequestrectomy. In majority of the cases 27 (67.5%) had a gap size less than an inch. Remaining had a gap size between one to two inches (Figure 8). Out of 35 patients who were injured, in one patient definitive surgery was carried out within 2 weeks post injury, in 18 patients between 2-4 weeks post injury, in 16 patients in 4-6 weeks post injury. Four patients who were operated for excision of tumour, definitive procedure was done in same sitting as excision; while in one patient in which necrosed sequestered bone was excised, the definitive procedure was deferred for 6 weeks till there was no sign of active infection.



**Figure 5: Age wise distribution of patients.**

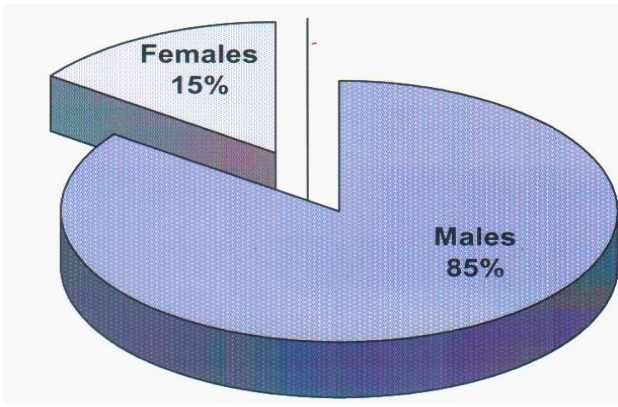


Figure 6: Sex wise patient distribution.

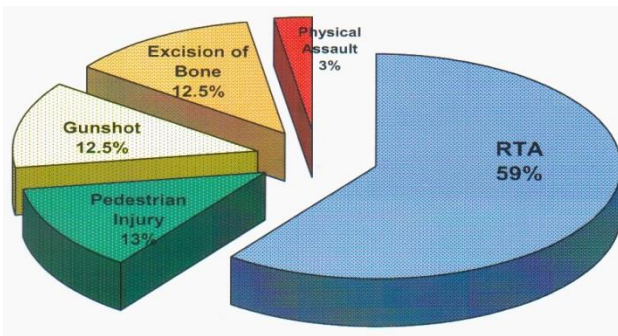


Figure 7: Cause of initial injury/bone gap.

Immediate complications like vascular injury, nerve injury, anaphylactic reaction to CHA were not observed in any of the cases. Excessive drainage collection in suction drain was seen in all the cases. For upper limb

cases, plaster slab was removed at second follow up ie. six weeks and active range of motion exercises started. Toe touch walking with four post walker or axillary crutches was started when sufficient bridging callus formation was seen radiologically. In 18 (45%) patients this was started at 16-20 weeks and at 20-24 weeks in 17 (42.5%) patients. Full weight bearing and unrestricted use of upper limbs was permitted only after radiological union was seen in at least 3 cortices in two perpendicular views. This varied between 24-30 weeks. In 23 (57.5%) patients radiological union occurred by 24-26 weeks (Figure 9). In 1 patient (2.5%) union was seen at 30 weeks (Figure 10). In remaining patients 16 (40%), radiological union was seen between 26-28 weeks. Also, it was seen that smaller the length of gap, the faster was the union (Table 1).

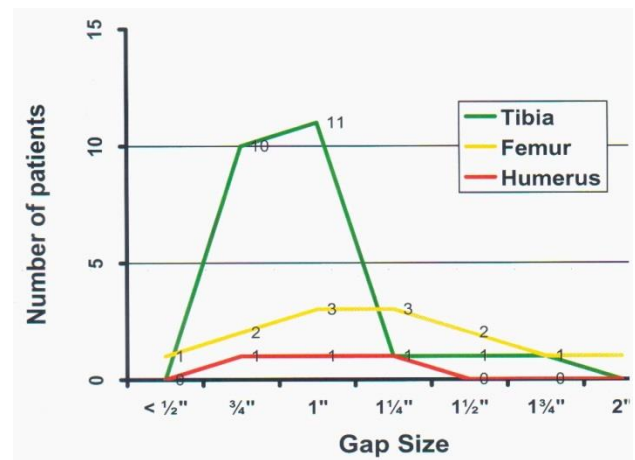


Figure 8: Patient distribution as per bone gap size.

Table 1: Results based on average union time of fracture.

Results	Average bone gap size	Average union time	Number of patients	Percentage
Excellent	0.5 inch	24 weeks	25	62.5
Good	1 inch	26 weeks	11	27.5
Fair	1.5 inch	28 weeks	3	7.5
Poor	2 inch	30 weeks	1	2.5

Slight bending of the plate was seen in one patient. None of the patient showed any angulation or other deformity or limb length discrepancy. Nearby joint stiffness was seen in 16 patients of which three cases were of humerus and 13 cases of femur (with slight extensor lag). All the patients regained full range of motion after a physiotherapy regime by the time of last follow up. Excellent results were seen in the majority of 25 patients (62.5%), good results in 11 patients (27.5%), fair results in 3 patients (7.5%) and poor outcome in 1 patient (2.5%). Also, it was seen that smaller the gap size, better was the outcome.

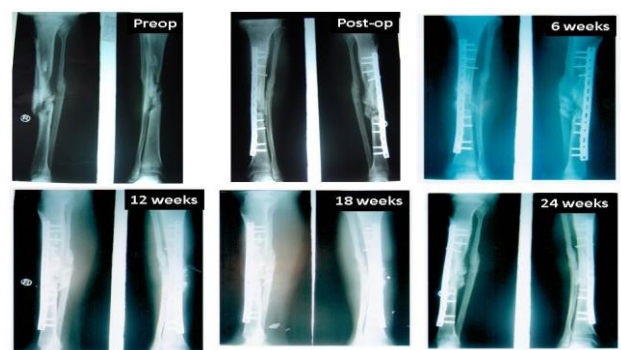
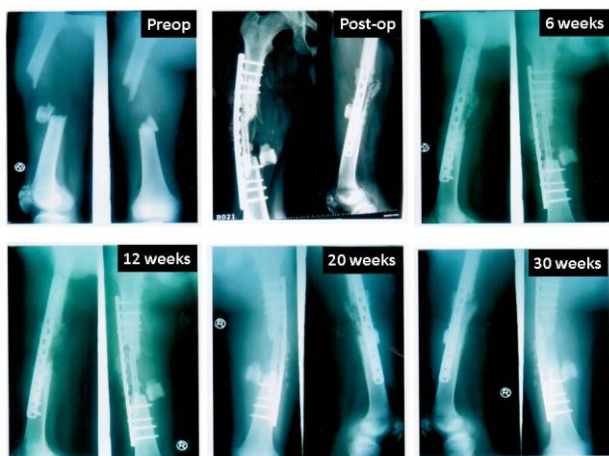

Figure 9: Radiographs of a patient with a bone gap ~1 inch.



**Figure 10: Radiographs of a patient with a bone gap ~2 inch.**

## DISCUSSION

Various methods have been tried to manage these gap non unions. Ilizarov in Russia had been pioneering the treatment of bony deformities, nonunions and bone lengthening by his technique of ring fixators. He described the mechanism of distraction osteogenesis and bone transport.<sup>6</sup> Paley et al treated tibial gap non unions with Ilizarov technique.<sup>7</sup> This has been tried successfully over decades to treat gap non unions. Green et al treated segmental bone defects by same method.<sup>8</sup> Abdel et al and Naggar et al treated massive bone defects using the same technique.<sup>9,10</sup> Thus, ilizarov technique has been used successfully over several years to treat bone defects in long bones. It has advantages of being able to treat large defects and permits early partial weight bearing. But it has some disadvantages of pin tract infection and scars; bulky and unsightly metallic construct to be carried, painful distraction process, trophic changes in the skin, soft tissue transfixation, etc.<sup>11</sup>

Various researchers treated bone defects based on same principle of distraction osteogenesis using modification of ilizarov frame, hybrid ring fixator, monorail fixator and AO tubular fixator.<sup>12-14</sup> Monorail or rail road fixator retains the advantages of ilizarov technique by permitting early partial weight bearing and ease of treating larger bone defects. It has additional advantages over ilizarov in being less bulky and a relative ease of application.<sup>15</sup>

Various methods have been tried to treat gap non unions in special situations. Masquelet described induction of bio membrane followed by autologous bone grafting with or without use of nail or plate implant for fixation was described in 1986. It is easy, reproducible method to treat the segmental bone loss in long and other bones also. It is a two stage technique.<sup>16</sup> In first stage, antibiotic impregnated cement spacer is placed in the gap and uninfected soft tissue cover is attempted. The second phase of autologous bone grafting is performed after average time of 7 (4-10) weeks of first surgery. This is

technically non demanding. Homologous bone grafting was fairly popular in 1960s particularly in children. The best survival of any type of allografts are said to be from a twin. The second best option is usually the mother. The paternal graft is the least favourable option. The fibula has been widely used to reconstruct long bone defects because of its structural characteristics and low donor site morbidity. This technique was done in situations where autologous fibula could not be harvested as in cases of osteogenesis imperfecta.<sup>17</sup> Allografts have been used in conjunction with bone morphogenic protein (BMP) or autografts in nonunion with bone deficiency. They are an alternative to arthroplasty in bone loss around a joint, especially in young individuals who are not candidates of arthroplasty.<sup>18</sup> Natrajan et al demonstrated use of customized megaprosthesis for massive bone loss in tumours around joints.<sup>19</sup> Miller et al treated defects in radius using autologous non vascularized free fibular grafts. Spira et al used iliac crest block grafts with intramedullary nails to treat forearm bone defects. Enneking et al used cortical bones to bridge segmental skeletal defects.<sup>20-22</sup> Matsushita et al described a novel chipping and lengthening method to treat delayed and nonunions with shortening or bone loss. It involved extraperiosteal exposure of fracture site, stabilization with an implant followed by chipping of fracture ends by using an osteotome parallel to long axis of bone without removal of attached soft tissues to the bone chips. Khan et al used the same technique with addition of autologous cancellous graft in gaps less than 4 cm.<sup>23,24</sup>

Huntington described a method to treat tibial gap non unions by medialisation of ipsilateral segment of fibula to bridge the gap and augmentation of junctions with autologous bone graft. Tuli et al used ipsilateral fibula to bridge gap non unions in tibia in one or two stage, using whole length except the epiphyseal ends. Catagni carried out medialisation of shaft of fibula to bridge the tibial gap nonunion using ilizarov frame.<sup>25-27</sup> In 1956, Nicoll described a method of treating gap non unions by filling the defect left by excision of dead bone with cancellous bone from the anterior iliac crest, securing the graft by a plate and screws. In 1980 Grace and Eversman modified Nicoll's technique by using a corticocancellous graft, fixed by a plate, in 18 patients with segmental defects caused by gunshot wounds or automobile accidents. Their six poor results were related to infection. Similarly, Hansis, Duffner and Weller successfully treated all but one of 131 pseudo-arthroses of the radius or ulna, but recommended this treatment only in the absence of infection.<sup>28-30</sup>

Ring et al treated humerus gap non unions using special technique of wave plate osteosynthesis.<sup>31</sup> In this technique, the dynamic compression plate or limited contact dynamic compression plate was contoured to stand away from the bone near the fracture site.<sup>32</sup> The use of plates for internal fixation gains more and more importance and acceptance due to the introduction of new implants offering the possibility to lock the screw head

with the plate. With this new plate generation i.e. locked compression plate (LCP), different fixation concepts can be considered and in addition the indication for plating is spread out to the diaphyseal segment of bone. The use of locking head screws is advantageous from the biological point of view. Such an internal fixator does not compress the periosteum and thus reduces the amount of avascularity of the bone cortex adjacent to the plate. Using plates as internal fixators with locking head screws has the advantage that a certain distance is present under the implant. This enables the cortex underneath the plate to form bone callus allowing faster and stronger bone healing.<sup>33</sup>

Ryoichi et al treated infected long bone defects associated with open fractures using LCP and autogenous cancellous bone graft.<sup>34</sup> Keating et al summarized various methods of management of gap non unions along with their advantages and disadvantages and various situations in which the method can be best used.<sup>4</sup> New designs of plates, such as locking compression plates and minimally invasive systems, are now available and may have an advantage over conventional plates in managing gap non unions in combination with bone grafting. However, it is best suited for gap non unions of size <6 cms over which the stability may be severely compromised and outcome affected. Our results conform to this finding wherein radiological union was seen in 24-26 weeks in patients (57.5%) with gap less than 1 inch and 26-28 weeks in patients (40%) where the gap was more than 1 inch but less than 2 inches.<sup>35</sup> In 1 patient (2.5%) wherein the gap was 2 inches, fibula was used additionally as a strut graft along with autologous corticocancellous iliac crest bone graft and calcium hydroxyapatite blocks, which broke when the plate bent. At 16 weeks follow up, plaster slab had to be given to augment stability by LCP. The fracture ultimately united at 30 weeks.

## CONCLUSION

The technique of bridge plating using internal fixator i.e. LCP along with autogenous corticocancellous bone graft along with calcium hydroxyapatite blocks is a fairly good technique to treat gap non unions. It has its own advantages of avoiding complications associated with large external frame constructs. However, larger gap size limits the usefulness of this technique.

## ACKNOWLEDGEMENTS

Prof. R. K. Goyal, Former Head, Department of Orthopaedics, SN Medical College, Agra and my thesis guide without whom this study would not be possible.

Prof. K. K. Pruthi, Former Head, Department of Orthopaedics, SN Medical College, Agra and my thesis chief guide who is a lighthouse and inspiration to all young orthopaedic surgeons and a surgeon par excellence.

*Funding: No funding sources*

*Conflict of interest: None declared*

*Ethical approval: The study was approved by the institutional ethics committee*

## REFERENCES

1. Farmanullah A, Khan MS, Awais SM. Evaluation of Management of Tibial Non-Union Defect with Ilizarov Fixator. *J Ayub Med Coll Abbottabad.* 2007;19(3):14-7.
2. Atesalp AS, Basbozkurt M, Erler K, Sehirlioglu A, Tunay S, Solakoğlu C, Gür E. Treatment of Tibial Bone Defects with the Ilizarov Circular External Fixator in High Velocity Gunshot Wounds. *International Orthopaedics.* 1998;22(6):343-7.
3. Shasha N, Krywulak S, Backstein D, Pressman A, Gross AE. Long-term followup of fresh tibial osteochondral allografts for failed tibial plateau fractures. *J Bone Joint Surg Am.* 2003;85(2):33-9.
4. Keating JF, Simpson AH, Robinson CM. The management of fractures with bone loss. *J Bone Joint Surg Br.* 2005;87(2):142-50.
5. Sadat-Shojai M. *Hydroxyapatite: inorganic nanoparticles of bone.* 1st Ed. Tehran: Iranian Students Book Agency (ISBA); 2010.
6. Ilizarov GA. The tension-stress effect on the genesis and growth of tissues. *Clin Orthop Relat Res.* 1989;(239):263-85.
7. Paley D, Catagni MA, Argnani F, Villa A, Benedetti GB, Cattaneo R. Ilizarov treatment of tibial nonunions with bone loss. *Clin Orthop Relat Res.* 1989;241:146-65.
8. Green SA, Jackson JM, Wall DM, Marinow H, Ishkanian J. Management of Segmental Defects by the Ilizarov Intercalary Bone Transport Method. *Clin Orthop Relat Res.* 1992;280:136-42.
9. Abdel-Aal AM. Ilizarov bone transport for massive tibial bone defects. *Orthopedics* 2006;29(1):70-4.
10. Naggar L, Chevalley F, Blanc CH, Livio JJ. Treatment of large bone defects with the Ilizarov technique. *J Trauma.* 1993;34(3):390-3.
11. Paley D. Problems, Obstacles and complications of limb lengthening by Ilizarov technique. *Clin Orthop.* 1990;250:81-104.
12. Charalambous CP, Akimau P, Wilkes RA. Hybrid monolateral-ring fixator for bone transport in post-traumatic femoral segmental defect: a technical note. *Arch Orthop Trauma Surg.* 2009;129:225-6.
13. Kocaoglu M, Eralp L, Rashid HU, Sen C, Bilsel K. Reconstruction of segmental bone defects due to chronic osteomyelitis with use of an external fixator and an intramedullary nail. *J Bone Joint Surg Am.* 2006;88:2137-45.
14. Raschke MJ, Mann JW, Oedekoven G, Claudi BF. Segmental transport after unreamed intramedullary nailing: preliminary report of a "Monorail" system. *Clin Orthop Relat Res.* 1992;282:233-40.
15. Arora S, Batra S, Gupta V, Goyal A. Distraction osteogenesis using a monolateral external fixator for

- infected non-union of the femur with bone loss. *J Orthop Surg (Hong Kong)*. 2012;20(2):185-90.
16. Masquelet AC, Fitoussi F, Beguet, Muller GP. Reconstruction of the long bone by the induced membrane and spongy autograft. *Ann Chirp Plast Esthet*. 2000;45:346-53.
  17. Tamaki S, Ichinohe T, Matsuo K, Hamajima N, Hirabayashi N, Dohy H. Superior survival of blood and marrow stem cell recipients given maternal grafts over recipients given paternal grafts. *Bone Marrow Transplant*. 2001;28(4):375-80.
  18. Johnson EE, Urist MR, Finerman GA. Resistant nonunions and partial or complete segmental defects of long bones: treatment with implants of a composite of human bone morphogenetic protein (BMP) and autolyzed, antigen-extracted allogeneic (AAA) bone. *Clin Orthop*. 1992;277:229-37.
  19. Natarajan MV, Govardhan RH, Williams S, Raja Gopal TS. Limb salvage surgery for pathological fractures in osteosarcoma. *International Orthopaedics*. 2000;24(3):170-2.
  20. Miller RC, Phalen GS. The repair of defects of the radius with fibular bone grafts. *J Bone Joint Surg Am*. 1947;29:629-36.
  21. Spira E. Bridging of bone defects in the forearm with iliac graft combined with intramedullary nailing. *J Bone Joint Surg Br*. 1954;36:642-6.
  22. Enneking WF, Eady JL, Burchardt H. Autogenous cortical bone grafts in the reconstruction of segmental skeletal defects. *J Bone Joint Surg Am*. 1980;62:1039-58.
  23. Matsushita T, Watanabe Y. Chipping and lengthening technique for delayed unions and nonunions with shortening or bone loss. *J Orthop Trauma*. 2007;21(6):404-6.
  24. Khan AS, Shoaib M, Khan J, Darain H, Arsh A. Outcome of Chipping Method in Complex Non-Union of Long Bones. *JIMDC*. 2017;6(3):121-4.
  25. Huntington TW. VI. Case of Bone Transference: Use of a Segment of Fibula to Supply a Defect in the Tibia. *Ann Surg*. 1905;41(2):249- 51.
  26. Tuli SM. Tibialization of the fibula: a viable option to salvage limbs with extensive scarring and gap nonunions of the tibia. *Clin Orthop Relat Res*. 2005;431:80-4.
  27. Catagni MA, Camagni M, Combi A, Ottaviani G. Medial fibula transport with the Ilizarov frame to treat massive tibial bone loss. *Clin Orthop Relat Res*. 2006;448:208-16.
  28. Nicoll EA. The treatment of gaps in long bones by cancellous insert grafts. *J Bone Joint Surg Br*. 1956;38-B:70-82.
  29. Grace TG, Eversman WW Jr. The management of segmental bone loss associated with forearm fractures. *J Bone Joint Surg Am*. 1980;62:1150-5.
  30. Hansis M, Duffner F, Weller S. Surgical treatment of aseptic forearm shaft pseudarthrosis. *Aktuelle Traumatol*. 1989;19:192-5.
  31. Ring D, Jupiter JB, Quintero J, Sanders RA, Marti RK. Atrophic ununited fractures of the humerus with a bony defect: treatment by wave-plate osteosynthesis. *J Bone Joint Surg Br*. 2000;82:867-71.
  32. Brunner CF, Weber BG. Special techniques in internal fixation. Telger TC, translator. New York: Springer; 1982. Blatter G, Weber BG. Wave plate osteosynthesis as a salvage procedure. *Arch Orthop Trauma Surg*. 1990;109:330-3.
  33. Gautier E. Concepts of Bridge Plating using AO Locked Compression Plate. *AO Dialogue* 2. 2009: 24-27.
  34. Kawakami R, Konno S, Ejiri S, Hatashita S. Surgical treatment for infected long bone defects after limb-threatening trauma: application of locked plate and autogenous cancellous bone graft. *Fukushima J Med Sci*. 2015;61(2):141-8.
  35. Klemm KW, Borner M. Interlocking nailing of complex fractures of the femur and tibia. *Clin Orthop Relat Res*. 1986;(212):89-100.

**Cite this article as:** Agarwal A. Results of bridging LCP along with corticocancellous autogenous bone graft and calcium hydroxyapatite blocks in gap nonunion of long bones. *Int J Res Orthop* 2018;4:702-8.