

Original Research Article

Surgical management of mallet finger with extension block pinning

Mohammed Sadiq, Vikrant Kulkarni*

Department of Orthopaedics, ESIC Medical College, Gulbarga, Karnataka, India

Received: 09 April 2018

Revised: 06 May 2018

Accepted: 08 May 2018

***Correspondence:**

Dr. Vikrant Kulkarni,

E-mail: drvikrantkulkarni49@gmail.com

Copyright: © the author(s), publisher and licensee Medip Academy. This is an open-access article distributed under the terms of the Creative Commons Attribution Non-Commercial License, which permits unrestricted non-commercial use, distribution, and reproduction in any medium, provided the original work is properly cited.

ABSTRACT

Background: Various surgical and nonsurgical treatments have been described in the management of mallet finger. The purpose of this study is to evaluate the effectiveness of extension block pinning in the management of displaced mallet finger fractures.

Methods: We conducted a retrospective study in which extension block pinning was done for displaced Mallet finger fractures. We included 10 patients in our study who were treated between 2016 and 2018. Fractures were classified according to Wehbe and Schnieder's classification. All the procedures were done using ring block anaesthesia. Postoperative radiographic assessment was done at each follow up at 15 days interval. Wires were removed after radiologic confirmation of fracture healing. Assessment of the outcome was done using Crawford's criteria.

Results: According to Wehbe and Schnieder's classification IIB type was the most common. All fractures involved more than 30% of articular surface. Average operative time was 30 mins. Congruent anatomical reduction was achieved in all the patients (intra-articular step off less than 1 mm). Average healing time of the fractures was 40 days. Seven out of the ten patients had excellent results. No wire related complications were seen in our patients.

Conclusions: Extensor block pinning when performed accurately is an easy, economical and effective technique in treatment of mallet fingers.

Keywords: Surgical management, Mallet finger, Extension block pinning

INTRODUCTION

Mallet finger is an avulsion of the extensor tendon from the base of the distal phalanx.¹ When associated with avulsion of a bony fragment it is called a bony mallet finger. Sudden forceful flexion of the distal interphalangeal joint (DIP) or axial loading is the most common mechanism of injury.² Surgical management of mallet finger with restoration of joint surface is recommended by several authors to prevent degenerative arthritis, loss of movements and poor cosmetic outcomes.^{3,4} Surgery is indicated when the fracture involves of more than 30% of the articular surface or there is palmar subluxation of the distal phalanx.⁵

Extension block pinning was first described by Ishiguro et al.⁶ It is an indirect reduction technique with a wire passed into the dorsal aspect of the DIP joint and then extending the distal phalanx to achieve anatomic reduction. In the present study our aim is to study the effectiveness of extension block pinning in achieving anatomical reduction and prevention of extension deficit. We intend to assess the effectiveness of the procedure in terms operative time, time required for fracture healing, correction of the deformity, range of motion and any complications.

METHODS

This study was conducted at ESIC Medical College and hospital, Gulbarga, Karnataka. Ten patients who visited

our outpatient department between May 2016 and February 2018 were included in our study. The inclusion criteria for extension block pinning were: mallet finger involving more than one third of the articular surface of the distal phalynx with or without palmar subluxation. Preoperative radiograph was used to assess the above parameters. Fractures were classified according to the Wehbe and Schnieder classification.⁷

Table 1: Wehbe and Schnieder classification of mallet finger fractures.

| Type | Description | Subtype | Articular involvement |
|------------|---------------------------------|---------|-----------------------|
| I | No DIP subluxation | A | <1/3 |
| II | DIP joint subluxation | B | 1/3-2/3 |
| III | Epiphyseal and physeal injuries | C | >2/3 |

All the procedures were performed under digital ring block anaesthesia under C-Arm guidance. The distal interphalangeal joint (DIP) was fully flexed and 0.9 mm k wire was inserted into the head of the middle phalynx proximal to the avulsed fragment. The direction of k wire is at 40 to 45° to the joint line. The avulsed fragment is reduced by fully extending the DIP joint. And after confirming complete anatomical reduction of the fragment a transfixing 0.9 mm k wire is passed from the tip of the distal phalynx across the DIP joint. The k wires

are cut close to the skin and simple dressing applied. We do not use any form of splintage in the postoperative period. Only oral antibiotics were given for 5 days. First inspection of the surgical site was done after 10 days. Thereafter patients were followed every 15 days once. X-rays were repeated at 4 weeks after the surgery and every 15 days once thereafter. Patients were followed up till 3 months postoperatively.

Table 2: Crawford criteria for postoperative evaluation of mallet finger fracture.

| | |
|------------------|-----------------------------------------------------------|
| Excellent | Full DIP joint extension and full flexion, no pain |
| Good | 0 – 10 deg of extension deficit, full flexion, no pain |
| Fair | 10-25 deg of extension deficit, any flexion loss, no pain |
| Poor | More than 25 deg of extension loss, or persistent pain |

Radiographs were repeated at interval of 15 days. Wires were kept till radiological union was confirmed by presence of trabeculae or sclerosis and no fracture gap. After confirming radiological union the wires were removed and full active range of motion (ROM) exercises were started. Crawford’s criteria were used to assess the outcome in each patient.⁸ Any complications associated with the procedure were also recorded. Fischer’s exact test was performed to assess a correlation between the type of fracture and the postoperative extensor deficit.

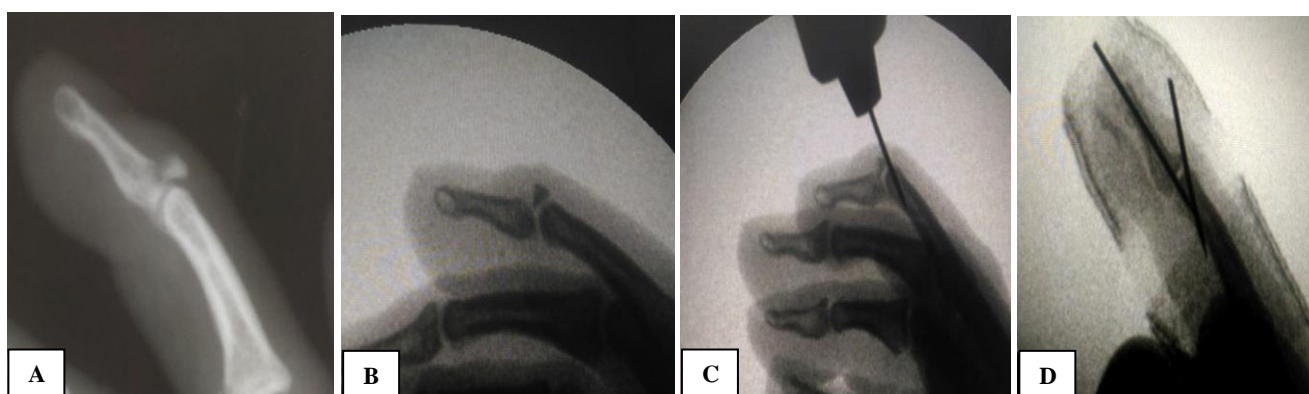


Figure 1: Intraoperative imaging showing the technique of extension block pinning used in our study.

RESULTS

Fall resulting in sudden forceful flexion of the DIP due to fall was the most common cause followed by sports (cricket) injuries. One patients had a direct injury at work place. According to Wehbe and Schnieder’s classification IIB type was the most common. All fractures involved more than 30% of articular surface. Average operative time was 30 mins. Congruent anatomical reduction was

achieved in all the patients (intrarticular step off less than 1 mm). Average healing time of the fractures was 40 days.

Seven out of the 10 patients had excellent results according to the Crawford’s criteria. Three patients had good results. None had fair or poor results. No pinsite complications were noted. Patients were followed up till 3 months and none had a recurrence of the deformity.

A two tailed Fischer’s exact test was performed to assess the correlation between the type of fracture and the postoperative extension deficit. No statistically

significant difference was seen between the different groups of fractures.

Table 3: Patient demographic details.

| Pt no. | Age/ Sex | Mode of injury | Wehbe and Schnieder type | Operative time | Fracture healing time | DIP extension deficit | Complications |
|--------|----------|-------------------|--------------------------|----------------|-----------------------|-----------------------|---------------|
| 1. | 23/M | Sports | IIB | 30 min | 30 days | Nil | Nil |
| 2. | 25/M | Work place injury | IIB | 35 mins | 45 days | 7 deg | Nil |
| 3. | 30/M | Fall from bike | I C | 25 mins | 45 days | Nil | Nil |
| 4. | 26/M | Sports injury | IIB | 30 mins | 30 days | 5 deg | Nil |
| 5. | 35/F | Fall | IIC | 35 mins | 45 days | 7 deg | Nil |
| 6. | 29/M | Fall | IIB | 25 mins | 30 days | Nil | Nil |
| 7. | 28/F | Fall | I C | 25 mins | 45 days | Nil | Nil |
| 8. | 31/M | Sports injury | II C | 30 mins | 45 days | Nil | Nil |
| 9. | 27/F | Sports | IC | 35 mins | 30 days | Nil | Nil |
| 10. | 33/M | Fall | IIB | 30 mins | 45 days | Nil | Nil |

Table 4: Post operative outcomes.

| | |
|------------------------------------------------------------------------------------------------------------------|---------------------------------------|
| Mean age | 29 years |
| Male: female ratio | 2.3: 1 |
| Most common mode of injury | Fall |
| Most common type according to Wehbe and Schnieder’s classification | Type II B |
| Average operative time | 30 mins |
| Average fracture healing time | 40 days |
| Post-operative outcome according to Crawford’s criteria | Excellent: 70% |
| | Good: 30% |
| | Fair: 0 |
| | Poor: 0 |
| Fischer’s exact test to assess the correlation between type of fracture and the post-operative extension deficit | Not statistically significant (p>0.4) |

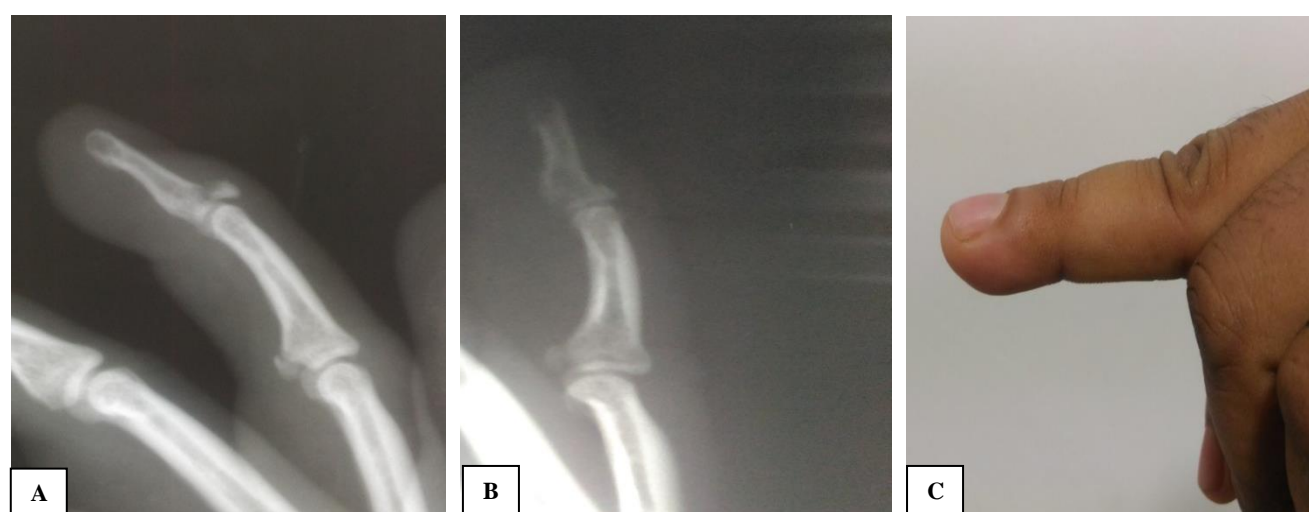

Figure 2: (A) Radiographs showing mallet fracture of the ring finger; (B) Postoperative radiograph showing anatomical reduction after wire removal; (C) Clinical photograph of full extension of the DIP joint at 3 months after follow up.

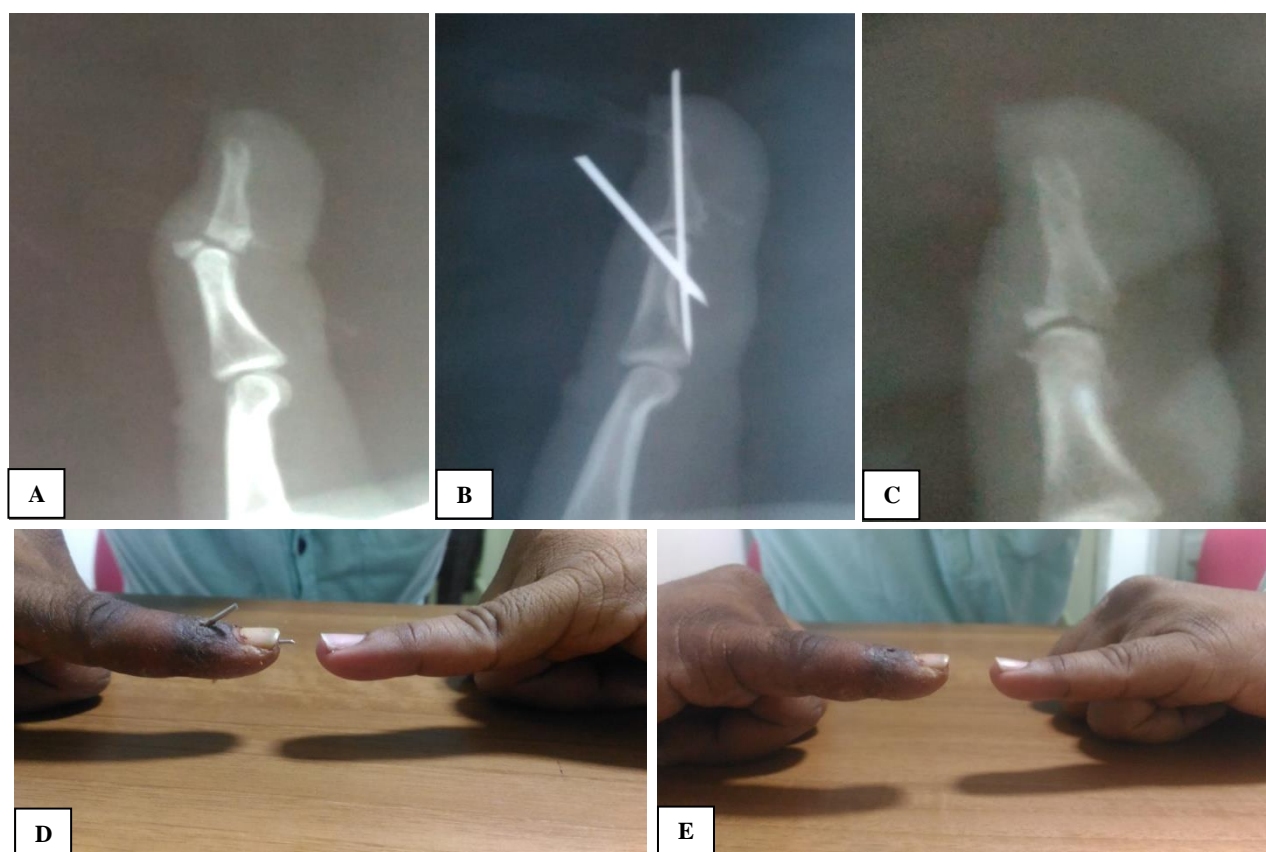


Figure 3: (A) Radiographs showing mallet fracture of the little finger; (B, C) Postoperative radiograph showing anatomical reduction of the fracture; (D) Clinical photograph of full extension of the DIP joint at 6 weeks follow up (E) Full extension maintained after wire removal (d).

DISCUSSION

Mallet finger is managed by various techniques ranging from conservative management to open repair and plating. Conservative management of mallet finger is with rigid splints, plater casts and prefabricated splints.⁹⁻¹² However it is not recommended because it can lead to joint stiffness, loss of extension, skin maceration and necrosis.¹³ Open procedures are also associated with high wound complication rates. Wehbe and Schnieder reported 33% complication rates in open surgical treated group compared to 9% in the nonsurgical group.⁷

Extension block pinning was first described by Ishiguro et al. in the year 1988.⁶ It is a simple closed technique of indirect reduction of the fracture fragment. Many studies have been done there after using the same technique or its modifications. Inoue et al. reported good to excellent results in 12 out of 14 patients.¹⁴ Similar results were seen by Pratts et al wherein they got good to excellent results in 21 out of the 22 patients treated.¹⁵ Hoffmiester et al showed good to excellent results in 94% of the patients.¹

In our study we have achieved anatomical reduction in all the cases. According to Crawford criteria excellent result in 7 out of the 10 patients treated (70%) and good results

in the other 3 (30%). None of our patients had fair or poor results. The average healing time in our study was 40 days. We have not delayed the removal of k wires beyond 6 weeks in any case. There was no statistically significant difference in the postoperative extension deficit among the different group of fractures. Some studies have reported skin maceration, nail deformities, transient nail riding as complications. But in our study none of our patients had any skin or nail problems.

CONCLUSION

Mallet finger fractures if not managed properly can lead to severe disabling complications especially if it involves the dominant hand. Thus it is very essential to achieve anatomical reduction and good DIP extension. Both of them can be achieved by extension block pinning technique. It being a closed technique of indirect reduction, it also avoids the complications associated with the open procedures. Thus we conclude that when performed correctly extension block pinning is an excellent method of treating mallet finger.

Funding: No funding sources

Conflict of interest: None declared

Ethical approval: The study was approved by the institutional ethics committee

REFERENCES

1. Hofmeister EP, Mazurek MT, Shin AY, Bishop AT. Extension block pinning for large mallet fractures. *J Hand Surg Am.* 2003;28(3):453–9.
2. Chung DW, Lee JH. Anatomic reduction of mallet fractures using extension block and additional intrafocal pinning techniques. *Clin Orthop Surg.* 2012;4(1):72–6.
3. Damron TA, Engber WD. Surgical treatment of mallet finger fractures by tension band technique. *Clin Orthop Relat Res.* 1994;(300):133-40.
4. Jupiter JB, Sheppard JE. Tension wire fixation of avulsion fractures in the hand. *Clin Orthop Relat Res.* 1987;(214):113-20.
5. Stark HH, Gainor BJ, Ashworth CR, Zemel NP, Rickard TA. Operative treatment of intra-articular fractures of the dorsal aspect of the distal phalanx of digits. *J Bone Joint Surg Am.* 1987;69(6):892-6.
6. Ishiguro T. A new method of closed reduction for mallet fractures. *Cent Jpn J Orthop Trauma Surg.* 1988;31:2049–51.
7. Wehbe MA, Schneider LH. Mallet fractures. *J Bone Joint Surg.* 1984;66A:658–69.
8. Crawford GP. The molded polythene splint for mallet finger deformities. *J Hand Surg.* 1984;9:231–7.
9. Lester B, Jeong GK, Perry D, Spero L. A simple effective splinting technique for the mallet finger. *Am J Orthop.* 2000;29:202–6.
10. Smillie IS. Mallet finger. *Br J Surg.* 1937;24:439–45.
11. Abouna JM, Brown H. The treatment of mallet finger. The results in a series of 148 consecutive cases and a review of the literature. *Br J Surg.* 1968;55:653–7.
12. Elliott RA Jr. Splints for mallet and boutonniere deformities. *Plast Reconstr Surg.* 1973;52:282–5.
13. Rayan GM, Mullins PT. Skin necrosis complicating mallet finger splinting and vascularity of the distal interphalangeal joint overlying skin. *J Hand Surg.* 1987;12:548–52.
14. Inoue G. Closed reduction of mallet fractures using extension-block Kirschner wire. *J Orthop Trauma.* 1992;6:413–5.
15. Darder-Prats A, Fernandez-Garcia E, Fernandez-Gabarda R, Darder-Garcia A. Treatment of mallet finger fractures by the extension-block K-wire technique. *J Hand Surg.* 1998;23:802–5.

Cite this article as: Sadiq M, Kulkarni V. Surgical management of mallet finger with extension block pinning. *Int J Res Orthop* 2018;4:538-42.