

Original Research Article

Anterior reconstruction of spine by posterior approach in cases of unstable thoracolumbar burst fractures

Anurag Tiwari^{1*}, Ankit Thora², Mukul Mohindra³, Amit Sharma⁴, Sumit Sural⁴, Anil Dhal⁴

Department of Orthopaedics, ¹Bansal Hospital, Bhopal, Madhya Pradesh, ²Shalby Hospital, Indore, Madhya Pradesh, ³Safdarjung Hospital, Delhi, ⁴Maulana Azad Medical College, New Delhi, India

Received: 01 April 2018

Revised: 16 April 2018

Accepted: 17 April 2018

*Correspondence:

Dr. Anurag Tiwari,

E-mail: dranurag.tiwari@gmail.com

Copyright: © the author(s), publisher and licensee Medip Academy. This is an open-access article distributed under the terms of the Creative Commons Attribution Non-Commercial License, which permits unrestricted non-commercial use, distribution, and reproduction in any medium, provided the original work is properly cited.

ABSTRACT

Background: The purpose of this study is to evaluate neurological, functional and radiological outcome of the anterior reconstruction of spine by posterior approach in cases of unstable thoracolumbar burst fractures.

Methods: Ten patients with acute unstable burst fractures at thoracolumbar junction (T-11 to L-3) with partial or complete neurological deficit in the age group of 18-50 years with McCormack's score six or more and thoracolumbar injury severity score (TLISS) five or more were included. Neurological status, Japanese Orthopaedic association score (JOA score), visual analogue scale (VAS), angle of kyphotic deformity, McCormack's score and TLISS score were evaluated.

Results: The mean duration of surgery was 282 minutes. The mean blood loss was 1885 ml. Five patients with neurologic deficit recovered an average of 1.40 ASIA grades at last 24 months' follow-up. The JOA score improved from -6 preoperatively to 11 at 24 months follow up. The mean kyphotic angle was 19 degrees preoperative improved to -0.6° postoperatively. Visual analogue score improved from 6.1 to 1.7.

Conclusions: The familiar posterior approach is a safe and reliable surgical approach for reconstruction of all the columns of spine. It has the advantage of doing anterior decompression and reconstruction with posterior instrumentation in single stage, reducing the operative time and blood loss. It reduces the morbidity of anterior approach (isolated or two staged) in the hands of an average orthopaedic surgeon.

Keywords: Anterior reconstruction, Posterior approach, Unstable, Burst fracture, Titanium cage

INTRODUCTION

Burst fractures are compression failure of the anterior and middle column of the spine in which the vertebral body fragments are retropulsed into the spinal canal causing neurological complications. They result from severe compressive axial loading of the spine.¹ These fractures comprise 10% to 20% of all spine injuries at the thoracolumbar junction of the spine.² The management of these fractures has been the subject of controversy. The goal of surgical treatment for burst fractures include decompression of the neural canal to facilitate

neurological recovery, correction of spinal deformity, fusion with rigid stabilization for early mobilization and maintenance of anatomic alignment. However, the selection of the approach for decompression and stabilization of fracture is controversial and can be carried out via an anterior, posterior, or combined anterior-posterior approach.^{3,4}

In unstable thoracolumbar fractures with McCormack score more than 6, anterior column reconstruction should be done.⁵ In case posterior stabilization is contemplated, the short segment is likely to fail. Hence the posterior

instrumentation should span 2-3 levels. However, the use of both approaches on an already traumatized patient may significantly increase morbidity. The purpose of our study was to describe the outcome of stabilization of all three columns through a single posterior approach and weigh the advantages and disadvantages of this approach.

METHODS

This prospective study was conducted in Lok Nayak Hospital, Delhi, India from May 2011 to April 2015. Ten patients with acute unstable burst fractures at thoracolumbar junction (T-11 to L-3) with partial or complete neurological deficit in the age group of 18-50 years with McCormack's score six or more and thoracolumbar injury severity score (TLISS) five or more were included in this study.⁶ Major fractures or limb injuries which are likely to impair mobilization of the patient, injury involving other major organ systems, pathological or osteoporotic fractures, history of previous spine surgery, and patients with bed sores were excluded from the study.

Neurological status was assessed in all patients using American Spinal Injury Association scale (ASIA). Functional status was assessed by Japanese Orthopaedic Association score (JOA score). Pain was measured according to visual analogue scale (VAS). The angle of kyphotic deformity of fractured segment was measured on plain radiograph lateral view of spine as the angle between superior endplate of vertebral body above the affected level and inferior endplate of vertebral body below the affected level (Figure 1). Pre-operative CT scans (Figure 2) and MRI dorsolumbar spine was done of all the patients (Figure 3). McCormack's score and TLISS score was calculated of all the patients.

Surgical technique

The anaesthetized patient was placed on a radiolucent table in prone position. A midline longitudinal skin incision was used. Para spinal muscles were retracted to expose the spinous processes, lamina, facets of fractured vertebra and of the adjoining one level cephalad and one level caudal vertebra. Pedicle screws each were placed on each side at one level cephalad and one level caudal to the fractured vertebra using the free hand technique.⁷

A temporary rod was fixed to the pedicle screws on the contralateral side of the area being exposed during decompression. Spinous process and laminae of the affected level, the inferior part of the cephalad lamina and the superior facet were removed. The bone removed was saved to be used as bone graft. The ligamentum flavum and the epidural fat were removed to expose the dura.

After gentle retraction of the dura and the nerve roots, the interbody graft was placed either alone or within a cage. The graft or cage was longitudinally aligned and set parallel to the axis of the spinal column in the centre of

the fractured vertebral body using an impactor, guided by intraoperative fluoroscopy. The temporary rods were replaced by the final rods over the pedicle screws on both sides. The bone already saved while doing laminectomy was broken into small fragments and was filled in a 2 ml syringe with its front end removed (Figure 4) and this graft was placed over roughened cortical bone of lamina (Figure 5). The surgical wound was sutured in layers over a suction drain followed by antiseptic dressing.

Post-operative regime

Turning in bed was done in the post-operative period every two hourly and the patient was encouraged to turn actively from second post-operative day. The patient was made to sit up with a brace and mobilized on a wheel chair on the second postoperative day. Post-operative radiograph was done on second post-operative day (Figure 6). The suction drain was removed after 48 hours and the sutures were removed at two weeks. Neurological charting, JOA score, VAS score and kyphotic angle were measured in all the patients at day 2, 2 weeks, 6 weeks, 3 months, 6 months, 12 months and 24 months post-operatively. In few selected patients, CT scan was done to see the intervertebral body fusion.

Statistical analysis

Differences in clinicoradiological findings between preoperative, postoperative and at final followup were analyzed using paired t tests and repeated analysis of variance. The level of significance was set at 95%.

RESULTS

In this study, the age of the patients ranged from 18 to 35 years with mean age of 27 years of which seven were male and three were female as shown in Figure 1 and 2.

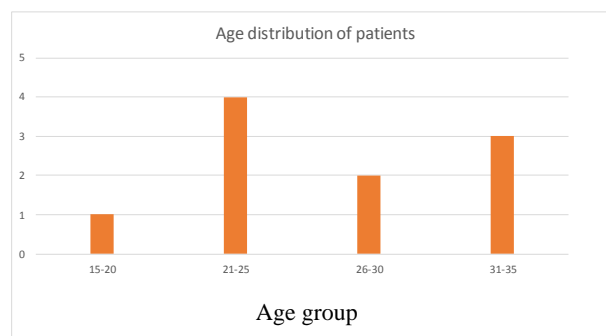


Figure 1: Bar graph showing the age distribution of patients.

Eight patients sustained fractures due to fall from height. One had history of fall of heavy object on the back, and one had history of fall from stairs. Most of the patients who sustained burst fracture were manual labourers, two were students, two were housewives, one was a farmer and one was a skilled worker.

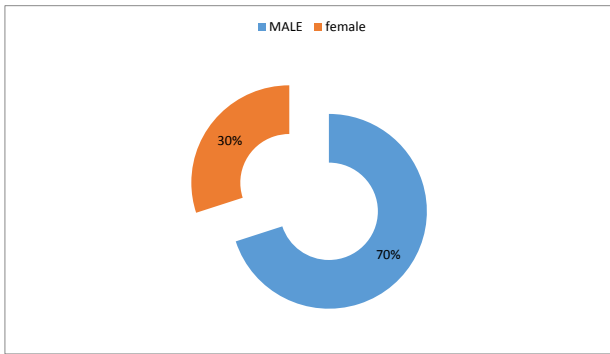


Figure 2: Pie graph showing gender distribution of patients.

The most common site of fracture was T-12 vertebra and majority of the injuries were at the thoracolumbar junction T-12 -L1. The mean McCormack score was 6.6 with range from 6 to 9. The mean TLISS score was 6.6 with range from 5 to 9.

The mean pre-operative haemoglobin level was 11.9 g%. The range was from 9.9 to 14.4 g%. The mean blood loss during surgery was 1885 ml. The range was from 1000 to 3000 ml. The mean requirement of blood transfusion was 1.7 units of whole blood. The range was from 1 to 4 units.

There was transection of cord in two patients while significant cord compression was found in one patient. Dural tear was found in three patients which was due to retropulsed fracture fragments and none were iatrogenic. Ligamentum flavum was found adhered to the dura in two patients. Pulsatile dura was found in two patients.

One patient had surgical site infection and implant failure for which pedicle screws were removed. One patient had infection without loosening of implant. One patient had disengagement of rod from one of the pedicle screw for which rod was removed.

The mean duration of surgery was 282 minutes. The range is from 210-360 minutes.

Four cases were in ASIA grade A and remained in A after 24 months of follow up. One patient was in grade C and remained C after 24 months of surgery. Two patients improved from A to C. Two patients improved from C to D and one from B to C. There was no neurological deterioration in this study. There was improvement in neurological status in five patients. Five patients with neurologic deficit recovered an average of 1.40 grades at last 24 months' follow-up.

The mean pre-operative JOA score was -0.6 ranged from -4 to 10. The mean post-operative JOA score at 6 weeks was 11.2 ranged from 3 to 22. The mean post-operative JOA score at 24 months was 11 ranged from 3 to 20. The outcome of JOA score is shown in Figure 3. The

improvement in JOA scores in patients of our study was statistically significant as shown by p value of 0.0001 calculated by Friedman test.

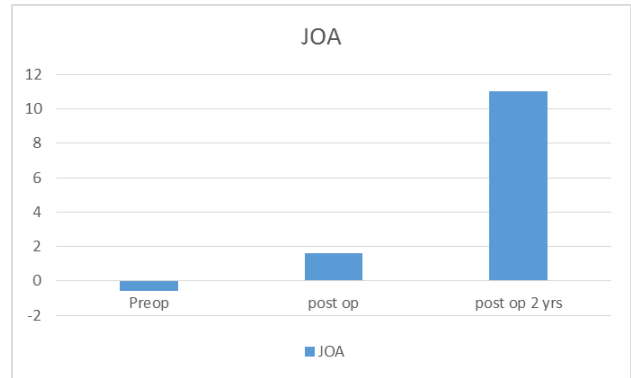


Figure 3: Bar graph showing the outcome of patients in terms of JOA score.

The mean pre-operative kyphotic angle was 19 degrees. The range was from 8 to 30 degrees. The mean post-operative kyphotic angle -0.6 degrees after surgery, the range was from -18 to +10 degrees. The mean kyphotic angle at 24 months was 7.7 degrees with the range from -18 to + 46 degree as shown in Figure 4.

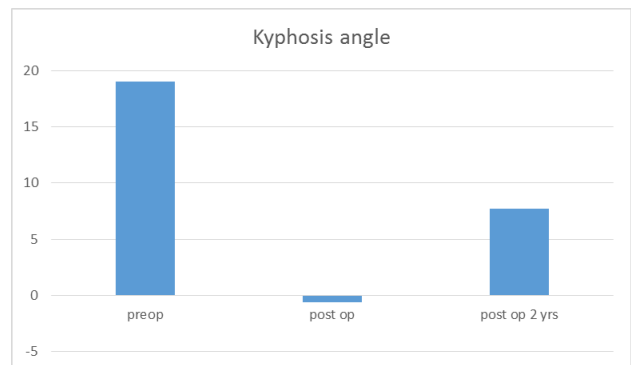


Figure 4: Bar graph showing the outcome in terms of Kyphosis angle.

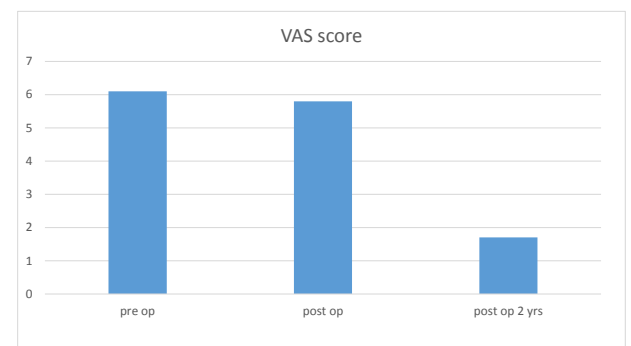


Figure 5: Bar graph showing the outcome in terms of VAS score.

The mean pre-operative visual analogue score was 6.1. The range was from 2 to 9. The mean post-operative VAS score was 3.8 after 2 weeks of surgery. The range was from 1 to 6. The mean post-operative VAS score at 24 months was 1.7 as shown in Figure 5. The range was from 0 to 6. This change in VAS score at final follow up was statistically significant as shown by Wilcoxon Signed Ranks test which showed a two tailed p value of 0.0001.

DISCUSSION

Thoracolumbar burst fractures represent 10% to 20% of all spine injuries at thoracolumbar region.^{1,2} The optimal treatment strategy for the thoracolumbar junction fractures is a controversial subject and still under debate. Patients with burst fracture of the thoracolumbar spine require surgery to relieve pain, decompress the canal to address neurologic deficits, stabilize the spine for early mobilization and to correct the anatomic alignment. The pedicle offers a strong point of attachment of the posterior elements to the vertebral body and pedicle screw instrumentation has revolutionized spine surgery.^{8,9} Pedicle screw fixation is considered biomechanically superior to other stabilization constructs and is exceptionally rigid.¹⁰ Pedicle screw fixation is a commonly used procedure for correcting deformity and stabilizing the spine until bony fusion occurs.

The selection of approach for treating these fractures has long been debated. The required steps can be carried out by either the anterior, posterior, or combined anterior-posterior approach.

Posterior instrumentation with pedicle screws has revolutionised the spine surgeries as it is superior to other posterior fixation system. The advantages are safe exploration of the surgical site with no injury to the pulmonary, visceral, and vascular structures. The posterior approach has also the advantage of better alignment correction. Pedicle screws provide rigid fixation along all 3 columns of the spine and a combination of forces (distraction, compression, or rotation) can be applied to the spinal segments. Thus, pedicle screw fixation improves the ability to correct a spinal deformity.^{11,12} The posterior approach gives a clear view of the neural structures which allows the removal of all dangerous structures compressing the neural elements. Using the posterior approach, the processes, such as decompression, correction of alignment, and posterior stabilization can be performed safely under direct vision. Furthermore, dural tears occur frequently in fractures with posterior element fractures which can be repaired using the posterior approach.¹³ The posterior approach involves shorter duration of surgery, decreased blood loss, and outcomes are similar to those of anterior surgery.¹⁴ The major disadvantage of posterior instrumentation alone is inability to reconstitute anterior column support and is somewhat weaker in compression than anterior instrumentation. This has led to a higher

incidence of progressive kyphosis and implant failure while managing highly comminuted fractures.

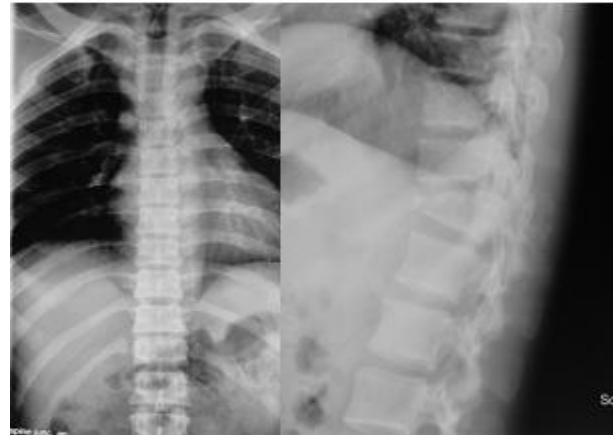

Figure 6: Preoperative radiograph anteroposterior and lateral view of thoracolumbar spine showing burst fracture of T 12 vertebra.

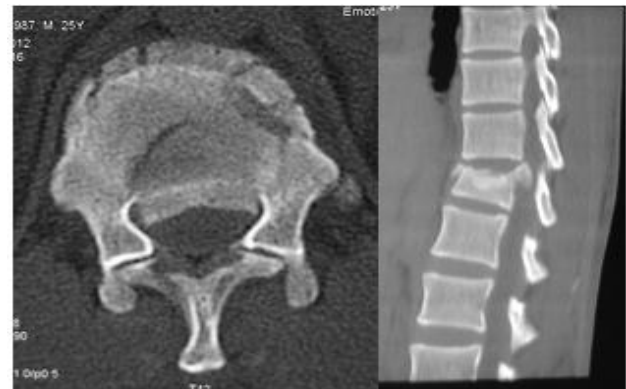

Figure 7: Preoperative CT scan axial and sagittal view showing the burst fracture and the retropulsion of fragments into the spinal canal.

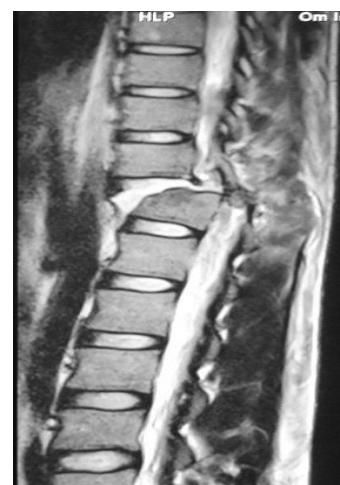

Figure 8: MRI sagittal view of thoracolumbar spine showing burst fracture of T 12 vertebra with spinal cord compression.

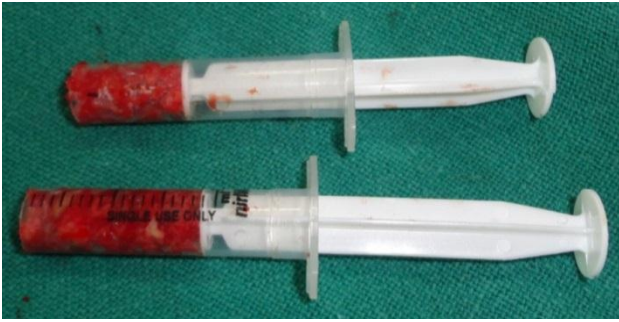

Figure 9: Syringe filled with morcelized bone graft.

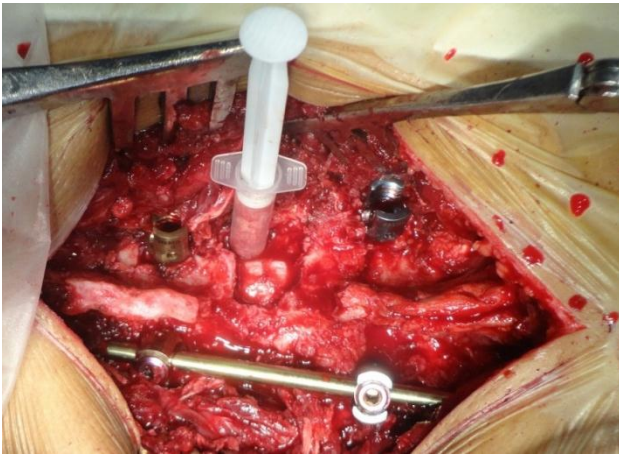


Figure 10: Morcelized bone graft being introduced through syringe before final rod placement.

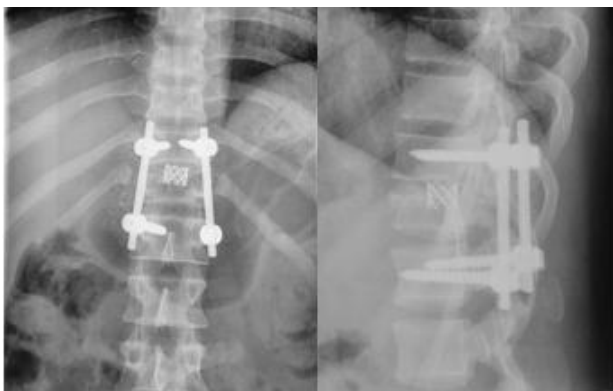

Figure 11: Postoperative radiograph anteroposterior and lateral view of thoracolumbar spine showing the pedicle screws and cage in place with correction of alignment.

Anterior approach provides direct visualization of the dural sac and is the most reliable method of decompression of spinal canal. Although the literature suggest that the neurological improvement is greater with anterior decompression as compared to posterior decompression, no prospective randomized study is available to demonstrate this difference. Bradford and McBride found in their study that the recovery of bowel and bladder paralysis occurred more frequently with

anterior decompression than with posterior decompression (69% vs. 33%, respectively). Another advantage of an anterior approach is restoration of anterior column support. According to Mc Cormack's load sharing classification; severely comminuted unstable fracture patterns are more prone to implant failure with posterior fixation alone. Reconstruction of the anterior column provides greater mechanical stability and helps prevent late collapse in unstable comminuted burst fractures than posterior constructs alone.^{15,16} However, anterior approach is not preferred by the average orthopaedic surgeon due to the extensive dissection required in the thoracolumbar area. Since the posterior approach is familiar to all orthopaedic surgeons, this approach can be extended to perform the required anterior decompression thereby resulting in global decompression of the dura and the anterior column reconstruction through this approach can augment the posterior pedicle screw instrumentation preventing its failure.

In cases of severely unstable burst fractures, anterior column reconstruction is necessary. High failure rates with short posterior construct prompted McCormack et al to devise a new classification named as the "Load Sharing Classification" in order to predict the failure of short segment fixation.⁵ McCormack et al concluded that the injuries with load sharing score greater than 6 must be treated with the anterior column reconstruction along with posterior fixation.

Multi-segmental fixation can achieve firmer fixation, but may result in stiffness and leads to early degenerative changes in the adjacent regions. The main advantages of the short-segment fixation through posterior approach are preservation of the motion segment, but a major disadvantage is the difficulty in restoring the anterior column. Failure to restore the anterior column support can lead to secondary kyphosis, instability, pain, and late onset neurological deficit.

Titanium mesh cages filled with bone graft provides anterior reconstruction after corpectomy in spine. The hollow cylindrical mesh structure of the cage can adequately recreate the size of vertebra bodies.^{17,18} The use of cages in the present series for anterior reconstruction, stabilization, and fusion combined with posterior transpedicular fixation, was done and the results were good.

In our study the complications were infection and implant failure. Surgical site infection occurred in two patients. Both the patients were young and non-diabetic with no focus of infection at remote sites in the pre-operative period. Both the infections had resolved with no recurrence at the latest follow-up at 24 months. Both of these infected cases showed improvement in the neurological deficit. Both improved from ASIA grade C to grade D, and were able to walk with support.

The risk of infection in spine surgeries is less common after anterior spinal fusion and is not greater for a combined anterior-posterior fusion than for a posterior fusion alone.¹⁹ Risk factors include advanced age, prolonged hospital stay, obesity, diabetes, immunosuppression, and infection at remote sites. Operative factors include prolonged surgery (more than five hours), high volume of personnel moving through the operating room, and instrumentation.²⁰ Posterior spinal surgery has higher infection rates than anterior spinal surgery. This is due to devascularization of paraspinal muscles produced by extensive muscle dissection required to expose the posterior elements. Use of large retractors for a long time may also induce paraspinal muscle ischemia. The large incisions required for surgery also produce large dead spaces where hematomas can occur that carry risk of infection.²¹

Two patients had construct failures. Both the patients presented with persistent pain. On serial x-rays, there was progressive spinal deformity with loss of kyphotic correction and implant failures. One was in the form of disengagement of the connecting rod from the superior pedicle screw of one side, because of the defect in the threads of the inner locking screw. The load sharing score was 6. The kyphotic angle increased from -2 degrees to +14 degrees 6 weeks after the surgery for which rod was removed and intra operatively, it was found that the bony fusion had been achieved.

In the second patient, there was surgical site infection which subsequently developed a progressive kyphosis with pedicle screw construct failure. The kyphotic angle increased from -12 to +24 degrees 3 months after the surgery, for which the pedicle screws were removed and the cage was left in situ.

CONCLUSION

The familiar posterior approach is a safe and reliable surgical approach for reconstruction of all the columns of spine. It has the advantage of doing anterior decompression and reconstruction with posterior instrumentation in single stage, reducing the operative time and blood loss. It reduces the morbidity of anterior approach (isolated or two staged) in the hands of an average orthopaedic surgeon.

Funding: No funding sources

Conflict of interest: None declared

Ethical approval: The study was approved by the institutional ethics committee

REFERENCES

1. Denis F. The three column spine and its significance in the classification of acute thoracolumbar spinal injuries. *Spine*. 1983;8:817-31.
2. Korovessis P, Baikousis A, Zacharatos S, Petsinis G, Koureas G, Iliopoulos P, et al. Combined anterior plus posterior stabilization versus posterior short-segment instrumentation and fusion for mid-lumbar (L2-L4) burst fractures. *Spine* 2006;31:859-68.
3. Dai LY, Jiang SD, Wang XY, Jiang LS. A review of the management of thoracolumbar burst fractures. *Surgical Neurology*. 2007;67(3):221-31.
4. Sasso RC, Renkens K, Hanson D, Reilly T, McGuire RA Jr, Best NM. Unstable thoracolumbar burst fracture, anterior only versus short segment posterior fixation. *J Spinal Disord Tech*. 2006;19(4):242-8.
5. McCormack T, Karaikevic E, Gaines RW. Load sharing classification of spine fractures. *Spine (Phila Pa 1976)*. 1994;19(15):1741-4.
6. Vaccaro AR, Lehman RA Jr, Hurlbert RJ, Anderson PA, Harris M, Hedlund R, et al. A new classification of thoracolumbar Injuries:the importance of injury morphology, the integrity of the posterior ligamentous complex, and neurologic status. *Spine (Phila Pa 1976)*. 2005;30(20):2325-33.
7. Kim YJ, Lenke LG, Bridwell KH, Cho YS, Riew KD. Free hand pedicle screw placement in the thoracic spine:Is it safe? *Spine (Phila Pa 1976)*. 2004;29(3):333-42.
8. Steffee AD, Biscup RS, Sitkowski DJ. Segmental spine plates with pedicle screw fixation. A new internal fixation device for disorders of the lumbar and thoracolumbar spine. *Clin orthop Relat Res*. 1986;203:45-53.
9. Whang PG, Vaccaro AR. Spinal Pedicle Fixation Revisited: The Role of X-rays and Other Surgical Factors. *Spine*. 2006;31(6):717-21.
10. White KK, Oka R, Mahar AT, Lowry A, Garfin SR. Pullout strength of thoracic pedicle screw instrumentation: comparison of the transpedicular and extrapedicular techniques. *Spine*. 2006;31(12):355-8.
11. Kaya RA, Aydin Y. Modified transpedicular approach for surgical treatment of severe thoracolumbar or lumbar burst fractures. *Spine J*. 2004;4(2):208-17.
12. Aebi M, Etter C, Kehl T, Thalgot J. Stabilization of the lower thoracic and lumbar spine with the internal skeletal fixation system. Indications, techniques and first results of treatment. *Spine (Phila Pa 1976)*. 1987;12(6):544-51.
13. Pickett J, Blumenkopf B. Dural lacerations and thoracolumbar fractures. *J Spinal Disord*. 1989;2(2):99-103.
14. Danisa OA, Shaffrey CI, Jane JA, Whitehill R, Wang GJ, Szabo TA et al. Surgical approaches for the correction of unstable thoracolumbar burst fractures:a retrospective analysis of treatment outcomes. *J Neurosurg*. 1995;83(6):977-83.
15. Shono Y, McAfee P, Cunningham BW. Experimental study of thoracolumbar burst fractures. A radiographic and biomechanical analysis of anterior and posterior instrumentation systems. *Spine (Phila Pa 1976)*. 1994;19(15):1711-22.

16. Gurwitz GS, Dawson JM, McNamara MJ, Federspiel CF, Spengler DM. Biomechanical analysis of three surgical approaches for lumbar burst fractures using short-segment instrumentation. *Spine (Phila Pa 1976)*. 1993;18(8):977–82.
17. Kazuhiro H, Masashi A, Toshikatsu W, Hara T. An experimental study or the interface strength between titanium Mesh cage and vertebra in reference to vertebral bone mineral density. *Spine*. 2001;26:957–63.
18. Robertson P, Rawlinson H, Hadlow A. Radiologic stability of titanium mesh cages for anterior spinal reconstruction following thoracolumbar corpectomy. *J Spinal Disord Tech*. 2004;17:44–52.
19. Blam OG, Vaccaro AR., Vanichkachorn JS, Albert TJ, Hilibrand AS, Minnich JM. Risk Factors for Surgical Site Infection in the Patient with Spinal Injury. *Spine (Phila Pa 1976)*. 2003;28(13):1475-80.
20. Massie JB, Heller JG, Abitbol JJ, McPherson D, Garfin SR. Postoperative posterior spinal wound infections. *Clin Orthop Relat Res*. 1992;284:99-108.
21. Levi AD, Dickman CA, Sonntag VK. Management of postoperative infections after spinal instrumentation. *J Neurosurg*. 1997;86(6):975-80.

Cite this article as: Tiwari A, Thora A, Mohindra M, Sharma A, Sural S, Dhal A. Anterior reconstruction of spine by posterior approach in cases of unstable thoracolumbar burst fractures. *Int J Res Orthop* 2018;4:421-7.