

## Original Research Article

# Functional outcome of proximal tibial fracture treated surgically using locking compression plate

Mahendra K. Aseri, Vijaypal Singh, Pradeep Kr. Sharma\*

Department of Orthopaedic, Dr. S.N. Medical College, Jodhpur, Rajasthan, India

**Received:** 13 March 2018

**Revised:** 04 April 2018

**Accepted:** 05 April 2018

**\*Correspondence:**

Dr. Pradeep Kr. Sharma,

E-mail: [paddysms02@gmail.com](mailto:paddysms02@gmail.com)

**Copyright:** © the author(s), publisher and licensee Medip Academy. This is an open-access article distributed under the terms of the Creative Commons Attribution Non-Commercial License, which permits unrestricted non-commercial use, distribution, and reproduction in any medium, provided the original work is properly cited.

### ABSTRACT

**Background:** Tibial plateau fractures are common intra-articular fractures, representing 1.2% of all fractures. These fractures are common in two age groups: as higher-energy fractures in younger patients and lower-energy fractures in elderly patients secondary to osteopenia. In the younger population, these injuries are associated with an increased incidence of complications like nonunion, infection, restriction of motion, and post-traumatic arthritis. The study aimed for final outcome of proximal tibial fracture using locking compression plate by minimally invasive percutaneous plate osteosynthesis (MIPPO).

**Methods:** 30 cases of proximal tibial fractures were treated by using locking compression plate and studied from December 2015 to November 2017 in Department of Orthopaedics, Dr. S.N. Medical College associated group of Hospitals, Jodhpur.

**Results:** All the selected 30 cases were followed up for 6 months. The average time for union of fracture was 21 weeks ranging from 18-24 weeks. Full weight bearing was not allowed until 12 weeks or complete fracture union. Partial immobilization was kept for 6 weeks in long knee brace. An average flexion was achieved upto 114°. We observed 4 cases of postoperative complications that included 2 infections, one knee stiffness and one varus deformity.

**Conclusions:** Surgical management of proximal tibia fractures with only lateral plating by MIPPO gave excellent reduction, rigid fixation to restore articular congruity and provides early motion to achieve optimal knee function and reducing post-traumatic osteoarthritis.

**Keywords:** Fracture, Proximal tibia, Locking compression plate, MIPPO

### INTRODUCTION

The knee joint is complex and most commonly injured joint now days because of increased motor vehicle accidents and sports related injuries. Tibial plateau fractures are common intra-articular fractures, representing 1.2% of all fractures.<sup>1</sup> These fractures are common in two age groups: as higher-energy fractures in younger patients and lower-energy fractures in elderly patients secondary to osteopenia. In the younger population, these injuries are associated with an increased

incidence of complications like nonunion, infection, restriction of motion, and post-traumatic arthritis.<sup>2</sup> Each fracture type has its own characteristic morphology and response to the treatment. It is essential to determine the force of injury since high energy trauma is associated with significant soft tissue and neurovascular damage. Apart from tibial plateau, meniscal tear and ligament injuries should also be assessed.<sup>3</sup> Most of automobile injuries occur with flexed limbs lead to maximum impact on patella, then the tibia and femur in varying proportions and at various positions. A better quality of implants,

good principles of internal fixation, soft tissue care, selection of proper antibiotics and use of aseptic technique in operation theatres have all contributed to dramatic change in trauma care. Thus we have advanced from the conservative approach to internal fixation of fractures as a treatment modality of first choice. Conservative treatment at any age, can be complicated by knee stiffness, malunion and nonunion. Open reduction and internal fixation has been advocated by using implants like locking compression plates to achieve good fracture union and optimal knee function.

#### **Clinical benefits of locking compression plate<sup>4</sup>**

The plate and screws form one stable system and the stability of the fracture depends on the stiffness of the construct. Locking the screw into the plate to ensure angular as well as axial stability, eliminate the possibility for the screw to toggle slide or be dislodged and thus strongly reduces the risk of postoperative loss of reduction.

Multiple angle stable screw fixation in the epiphyseal and metaphyseal region, allows for fixation of many fractures that are not treatable with standard devices.

Improved stability in multi-fragmentary complex fractures, so that with bone loss double plating can be avoided.

The fixed angle stability avoids subsidence of fixation in metaphyseal areas. This allows for less precise contouring of the plate, as fixation depends of plate screw construct rather than friction between plate bone interfaces.

In situations where the MIPPO technique is indicated or possible, accurate contouring of the plate is not mandatory.

#### **Aims and objectives**

- To restore the anatomy of articular surface of upper end of the tibia and knee joint by operative treatment with internal fixation.
- Early mobilization of knee joint.
- To assess the union of fractures after internal fixation.
- To assess the range of motion of knee joint after surgical treatment.

#### **METHODS**

This prospective study was conducted during December 2015 to November 2017. We selected 30 patients who were treated surgically for proximal tibial fracture using locking compression plate at Department of Orthopaedics, Dr. S. N. Medical College Associated group of Hospital, Jodhpur.

#### **Inclusion criteria**

Inclusion criteria were age/sex, above 18 years of both sex; closed fractures; Schatzker's type 1,2,3,4,5, and 6 fracture; associated ligamentous injuries; associated fibular upper end fracture.

#### **Exclusion criteria**

Exclusion criteria were age below 18 years; compound fractures; other limb fractures and diseases; pathological fractures; associated neurovascular injury; patients who are medically not fit for surgery.

Fracture was assessed for soft tissue injuries and followed by radiological assessment of fracture with Schatzker's classification.<sup>5</sup>

**Table 1: Schatzker's classification.<sup>5</sup>**

<b>Type I</b>	Pure cleavage
<b>Type II</b>	Cleavage combined with depression
<b>Type III</b>	Pure central depression
<b>Type IV</b>	Fractures of medial condyle
<b>Type V</b>	Bicondylar fractures
<b>Type VI</b>	Plateau fracture with dissociation of metaphysis and diaphysis

The following protocol was followed after patients were admitted and planned for surgery.

At first preoperative investigations were done. Treatment of the co-morbidities of the patient were done with appropriate references to the concerned specialties. Use of antibiotics pre-operatively and continued till the removal of sutures.

Appropriate and valid written consent was taken. The patient was taken for surgery after routine investigations and after obtaining fitness toward surgery. Routine investigations were done like hematocrit, fasting blood sugar, blood urea, serum creatinine, HIV, HbSAg, HCV, chest X-ray and ECG. Instruments were checked and sterilized beforehand.

#### **Procedure**

Patient was shifted to OT table on supine position then part was scrubbed, painted and draped. A minimum required skin incision was made over the antero-lateral aspect of proximal tibia. Fracture was reduced by traction and manipulation and confirmed under C-arm.

Plate inserted in sub muscular plane with minimum incision. Proper placement of plate was confirmed with C-arm and maintained with K-wire/drill bit. At first compression screw was applied then fixed angle drill sleeve applied to the locking slot of plate to drill for

applying locking screw. Wound was closed layer by layer.

**Various instruments required are**

- Reduction-clamp (pointed) for reduction the fracture.
- Periosteum elevator for elevation of periosteum.
- Screw driver for 4.5 mm cortical screw and 6 mm cancellous screw.
- Battery operated hand drill.
- Drill bit 3.2 mm for drilling the bone.
- Tape of different sizes: 4.5 mm and 6.5 mm.
- Depth gauge for measuring the appropriate size of screw.

**Post-operative instructions**

BP and TPR of patients were monitored hourly and post-operative analgesic given. Dressing observed for soakage and post-operative antibiotics administered till suture removal, 5 days intravenous then 7 days oral. Foot end elevated (as surgeries were performed under spinal anaesthesia). Postoperative X-ray preferably done on the next day. Suture was removed on the 10-12 days of post-operative day.

The patients were advised static quadriceps exercise soon after surgery followed by passive range of motion with protected knee brace up to 6 weeks. After 6 weeks knee mobilization and partial weight bearing was started. An immediate postoperative X-ray was done, later on repeated on 6 weeks, 3 months and 6 months.

**Follow up**

Follow up was done at 2 weeks, 4 weeks, 6-8 weeks and 6 months. Following points were noticed during follow up:-

**Clinical features**

- Surgical scar
- Range of movement
- Presence of pain
- Stability

**Radiological features**

- Callus formation
- Maintenance of reduction
- Widening and depression of articular surface.
- Varus and valgus collapse
- Sign of secondary osteoarthritis

Patients were regularly followed up at 6-8 weeks interval till complete fracture union. Based on the clinical and radiological signs of union, patients were allowed partial weight bearing and gradually progressed to full weight bearing. The patients were then reviewed at 6 months, during that time the anatomic and functional evaluation

was done using the modified Rasmussen clinical and radiological grading system.

**Table 2: Modified Rasmussen criteria for clinical assessment.<sup>6</sup>**

Clinical characteristics	Score
<b>Pain</b>	
None	6
Occasional	5
Stabbing pain in certain position	3
Constant pain after activity	1
Significant rest pain	-3
<b>Walking capacity</b>	
Normal walking capacity for age	6
Walking outdoor more than one hour	5
Waling outdoor 15 min - 1 hr	3
Walking outdoor <15 min	1
Walking indoor only	0
Wheel chair or bed ridden	-3
<b>Knee extension</b>	
Normal	4
Lack of extension <10°	2
Lack of extension >10°	0
Lack of extension >20°	-2
<b>Total range of motion</b>	
Full	6
At least 120°	5
At least 90 °	3
At least 60°	1
<60°	-3
<b>Power of quadriceps</b>	
Grade 5	2
Grade 3-4	1
Grade <3	-2
<b>Maximum scores</b>	
Excellent	28-30
Good	24-27
Fair	20-23
Poor	<20

**Assessment of complications**

- Malunions, delayed union, non union
- Knee stiffness
- Nerve injury

**RESULTS**

In our study, 25 (83.33%) were male patients and 5 (16.67%) were female patients with mean age 39.03 years (Table 3).

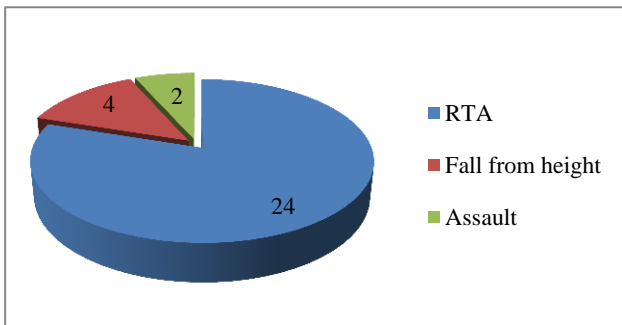
The majority of patients were in the age group of 31-40 years (Table 4). Those who were highly associated with road traffic accident accounts for 80% of cases.

**Table 3: Gender distribution.**

Gender	No. of patients	Percentage (%)
Male	25	83.33
Female	5	16.67
<b>Total</b>	<b>30</b>	<b>100</b>

**Table 4: Age distribution.**

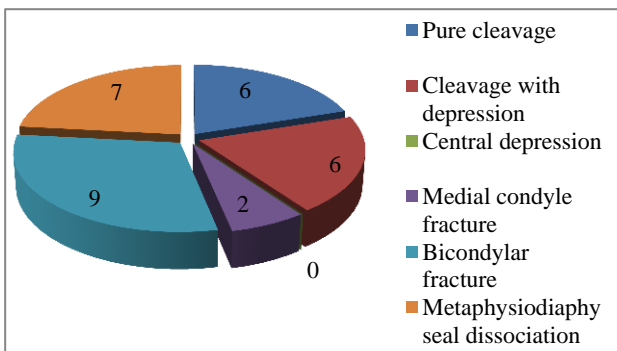
Age (in years)	No. of patients	Percentage (%)
<30	9	30
31-40	11	36.67
41-50	3	10
51-60	7	23.33
<b>Total</b>	<b>30</b>	<b>100</b>



**Figure 1: Mode of injury.**

In our series most of patients were outdoor workers 17 (56.67%). An average flexion was achieved upto 0-114° in present series. The average time for union of fracture was 21 weeks ranging from 18-24 weeks.

In our study, 56.67% of the patients sustained injury on left side and 43.33% on right side, so there was left sided predominance as compared to the right side. Most of the patients were found to be type V (9 cases) and type VI (7cases) Schatzker's classification (53.33%).



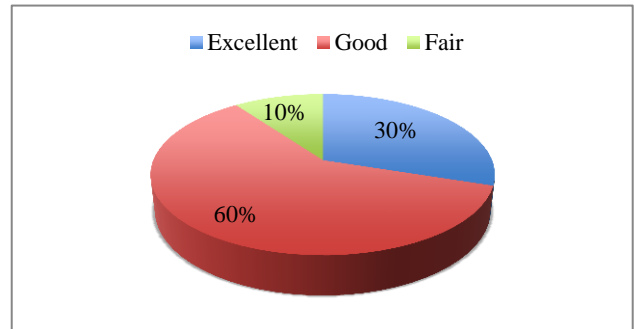
**Figure 2: Type of fractures.**

All fractures united within expected time (except two cases with infection), not a single case of nonunion was noted in our series.

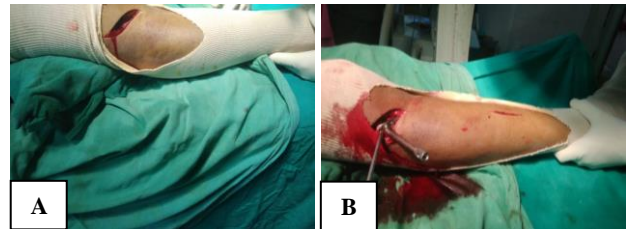
**Table 5: Postoperative complications.**

Postoperative complications	No. of patients	Percentage (%)
Infection and wound dehiscence	2	6.67
Varus deformity	1	3.33
Knee stiffness	1	3.33
Normal	26	86.67
<b>Total</b>	<b>30</b>	<b>100</b>

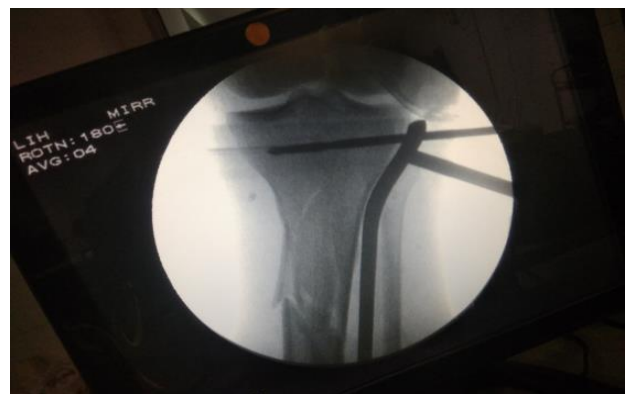Out of 30 cases treated, nine fractures gave excellent results, eighteen fractures healed with good results and three fractures with fair results.



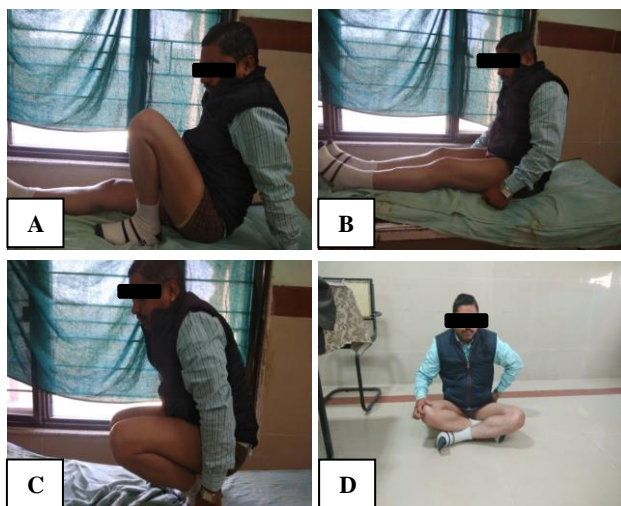**Figure 3: Minimal incision and plate sliding of same case.**



**Figure 4: A= Minimal incision after painting and drapping; B= Sliding of the plate with help of angled drill sleeve in submuscular plane.**



**Figure 5: Proper placement of plate confirmed with C-arm and maintained with drill bit.**



**Figure 6: A= complete flexion; B= complete extension; C= squatting; D= cross legged sitting.**

**DISCUSSION**

Proximal tibial fractures are major traumatic injury occurring as the result of RTA, fall from height, violence etc. It is sometimes associated with other bony or soft tissue injuries. Any fracture around the joint (especially weight bearing knee joint in the lower limb) is of paramount importance as it could result in significant morbidity and quality of life. Hence the treatment of upper tibial fractures with intra articular extension has become a challenge for the orthopaedic surgeon. Stable internal plate fixation without damaging the soft-tissue envelope is very difficult to achieve, only fair results are seen in 20% to 50% of these fractures. Outcome after tibial plateau fracture fixation depends mainly on knee range of motion and strength of the quadriceps. Knee stiffness is more clinically relevant than instability in these fractures.

We presented the clinical study of surgical treatment of 30 closed proximal tibial fractures. The analysis of the results were made in terms of gender, age, occupation, mode of injury, laterality, duration of hospitalization, types of fracture (Schatzker’s classification), period of immobilization, complications and clinical results.

We have attempted to present the various types of proximal tibial fractures in our Indian setup. It is found that the keenness for modernisation, mechanisation and industrial development created more automobile accidents due to increase in the number of population and automobiles.

The maximum incidence of proximal tibial fracture was found in the productive age populace i.e., 31-40 years (36.67%). The mean age was found to be 39.03 years in our study. Seppo also showed age incidence of 20-60 years with an average of 39.8 years, which correlates with the present study.<sup>7</sup>

In our succession majority of the patients were male (83.33%). This can be attributed to our Indian setup where the female population mostly works indoor and less prone for injuries. So the significant proportions of proximal tibial fractures related to sex distribution were not available to comment. Occupationally proximal tibial fractures were seen in people with high level of activity, travel and outdoor working habits. In our study the commonest mode of injury was road traffic accident (80%), followed by fall from height (13.33%). There was a significant preponderance of left side laterality. The left tibia was affected in 56.67% and right tibia in 43.33% of cases.

In our series, Schatzker’s type V and type VI fractures dominated making 53.33% of all fractures. It was also concluded that bicondylar fracture was more common.

**Table 6: Comparison of fracture type with other studies.**

Type of fractures	Tampere hospital Finland (%) of cases <sup>7</sup>	Wellesley hospital Toronto (%) of cases <sup>5</sup>	Our study (%) of cases
Type I	11.5	6	20
Type II	30.5	25	20
Type III	9.9	36	0
Type IV	9.2	10	6.67
Type V	21.3	3	30
Type VI	17.5	20	23.33

The problem faced by us during the study was infection and wound dehiscence in two cases; hence immobilization was kept for longer duration in these patients. The infection might be attributed to nosocomial infection. An average flexion of 0-114<sup>0</sup> was achieved by less soft tissue damage, better implant placement and physiotherapy, similar also reported by Cole et al (0-122<sup>0</sup>) and Egol et al (0-109<sup>0</sup>).<sup>8,9</sup> In spite of all the ligament injuries and complications, we were able to achieve 30% excellent result, 60% good result (overall 90% acceptable result) with our surgical care using locking compression plate fixation. In addition we obtained 10% fair result in terms of functional outcome. These results were comparable with other documented standard studies of Schatzker and Seppo et al (86% satisfactory).<sup>5,7</sup>

Recent trend is to do minimal invasive surgeries as much as possible. Many centers have shown good results with arthroscopic assisted internal fixation, hybrid external fixator, minimal internal fixation supplemented with external fixation, Ilizarov ring fixation and most recently the MIPPO (minimal invasive percutaneous plate osteosynthesis).<sup>10-12</sup> We employed the MIPPO technique and had satisfactory results. Hence, the surgical management of tibial plateau fractures is challenging, gives excellent anatomical reduction, rigid fixation to

restore articular congruity, facilitate early knee motion, thus achieving optimal knee function and thereby preventing post-traumatic osteoarthritis.

## CONCLUSION

Proximal tibial fractures are increasing (especially the high velocity injuries) with increase in the number of road traffic accidents. These fractures need optimum treatment as it involves the productive age groups. These fracture with inherent less soft tissue coverage have high risk of wound dehiscence and infection. Anatomic reduction, accurate axial and articular alignment with rigid fixation should be the objective of the treatment to achieve a stable and functional knee joint. Minimal invasive surgery lead to less soft tissues dissection without draining fracture haematoma thereby reduction in the period of immobilization with less chances of infection and stiffness lead to excellent functional outcome of the knee joint.

*Funding: No funding sources*

*Conflict of interest: None declared*

*Ethical approval: The study was approved by the institutional ethics committee*

## REFERENCES

1. Cole P, Levy B, Schatzker J, Watson JT. Tibial plateau fractures. In: Browner B, Levine A, Jupiter J, Trafton P, Krettek C, eds. *Skeletal Trauma: Basic Science Management and Reconstruction*. Philadelphia, PA: Saunders Elsevier; 2009: 2201–2287.
2. Papagelopoulos PJ, Partsinevelos AA, Themistocleous GS, Mavrogenis AF, Korres DS, Soucacos PN. Complications after tibia plateau fracture surgery. *Injury*. 2006;37:475–84.
3. Watson JJ and Wiss AD. Fractures of the proximal tibia and fibula, chapter 44 in Rockwood and Green's fractures in adults, Bucholz RW and Heckman JD, Ed. 5th ed. Vol 2. Philadelphia: Lippincott Williams and Wilkins; 2001: 1799-1839.
4. Wagner M. General principles for the clinical use of the LCP. *Injury*. 2003;2:31-42.
5. Schatzkar J, Mc Broom R and Bruce D. The tibial plateau fractures – Toronto experience. *Clin Orthop*, 1979;138:94.
6. Rasmussen PS. Tibial condylar fractures. Impairment of knee joint stability as an indication for surgical treatment. *J Bone Joint Surg Am*. 1973;55:1331-50.
7. Honkonen SE. Indications for surgical treatment of tibial condyle fractures. *Clin Orthop*. 1994;302:199-205.
8. Cole PA, Zlowodzki M, Kergor J. Treatment of proximal tibia fracture using the Less Invasive Stabilization System. Surgical experience and early clinical results in 77 fractures. *J Orthop*. 2004;18:528-35.
9. Egol KA, Su E, Tejwani NC, Sims SH, Kummer FJ, Koval KJ. Treatment of complex tibial plateau fractures using the less invasive stabilization system plate. *J Trauma*. 2004;57:340-6.
10. Buchko GM, Johnson DH. Arthroscopy assisted operative management of tibial plateau fractures. *Clin Orthop*. 1996;332:29.
11. Marsh JL, Smith ST, Do TT. External fixation and limited internal fixation for complex tibial plateau fractures. *J Bone Joint Surg*. 1995;77:661-73.
12. Jong-keun O, Chang-wug O, In-Ho J, Sung-Jung K, Hee-Soo K, Il-Hyung P, et al. Percutaneous plate stabilisation of proximal tibial fractures. *J Trauma*. 2005;5:431-7.

**Cite this article as:** Aseri MK, Singh V, Sharma PK. Functional outcome of proximal tibial fracture treated surgically using locking compression plate. *Int J Res Orthop* 2018;4:400-5.