

## Case Report

# Anterior hip dislocation in young patient obturator (inferior) type: a rare case report

Vijaykumar Kulambi, Kartavya Chaudhari\*, Vickykumar Pethapara

Department of Orthopaedics, JJM Medical College, Davangere, Karnataka, India

**Received:** 11 December 2017

**Revised:** 23 March 2018

**Accepted:** 26 March 2018

**\*Correspondence:**

Dr. Kartavya Chaudhari,

E-mail: [kartavya8891@gmail.com](mailto:kartavya8891@gmail.com)

**Copyright:** © the author(s), publisher and licensee Medip Academy. This is an open-access article distributed under the terms of the Creative Commons Attribution Non-Commercial License, which permits unrestricted non-commercial use, distribution, and reproduction in any medium, provided the original work is properly cited.

### ABSTRACT

Obturator type traumatic anterior hip dislocation in adult is rare of all type of hip dislocation. Here we described a case with same description. A patient 30 years male residing at Hoovina Hadagali, Bellary district, Karnataka met road traffic accident of his car while he was sitting in front seat with thigh abducted. He was brought to emergency room where he was diagnosed as obturator type of anterior right hip dislocation and closed reduction was achieved within 2 hours. Patient was posted for closed reduction of right hip under general anaesthesia which achieved by Alli's maneuver followed by traction and immobilisation with Thomas splint. 3 weeks of immobilisation followed by progressive mobilisation and loading patient was able to walk without any complaint with normal range of movements after 6 months.

**Keywords:** Anterior hip dislocation, Obturator inferior type, Alli's maneuver, Closed reduction

### INTRODUCTION

Hip dislocations which were once to be rarity have become increasingly common in the last decade because of the increased number of automobile accidents due to high speed transportation and increased number of industrial accident particularly in mines which provide high energy trauma.

Traumatic dislocation of the hip joint may include pure hip dislocations, dislocations with fracture of the femoral head and dislocations with fracture of acetabulum.

The position of the femoral head in relation to the acetabulum and the vector of the force at the time of impact determine the type of injury produced. Because of the intrinsic stability and massive bony columns of pelvis surrounding the acetabulum, high energy is usually required to produce these injuries.

Anterior dislocations are less common and of two main types: superior, where the femoral head is displaced into the iliac or pubic region and inferior, where the head lies in the obturator region.<sup>1</sup>

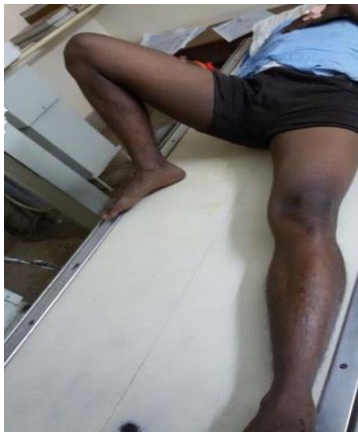The clinical presentation of the injured limb can give important information regarding the likely type and direction of hip dislocation. Anterior hip dislocations are presented as shortened and externally rotated limb.<sup>2</sup>

The evaluation of a patient with suspected hip dislocation should be expedited, beginning with an immediate anteroposterior pelvis radiograph before any attempt at reduction. The size of the femoral head and projection of the lesser trochanter compared with the contra lateral side yield important information about the direction of the dislocation. With an anterior dislocation, the femoral head typically appears larger and the lesser trochanter may be seen in its entirety because of external rotation of the extremity.<sup>2</sup>

A pure hip dislocation should be reducing as soon as possible to minimise the risk of osteonecrosis. The risk of osteonecrosis clearly increases with increasing time to reduction of the dislocation. Multiple attempts at closed reduction should be avoided to minimize the risk of iatrogenic damage to the femoral head. After reduction plain x-ray should be done for confirmation.

### CASE REPORT

A 30 years, male patient named resident of Hoovina Hadagali, Bellary district, Karnataka met road traffic accident of his car while he was sitting in front seat with right thigh abducted. Patient was brought to emergency room with right hip abducted 30°, flexed at 80° and externally rotated 20° (Figure 1). Extension and adduction of hip was extremely painful and restricted. No neurovascular impairment was determined.

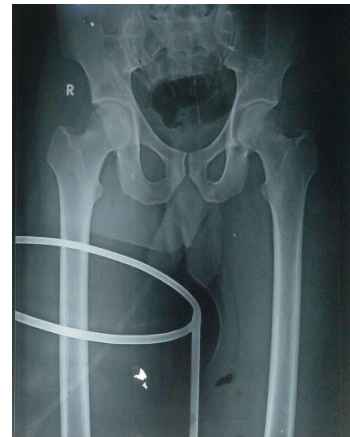

**Figure 1: Clinical position of patient when brought to emergency room.**

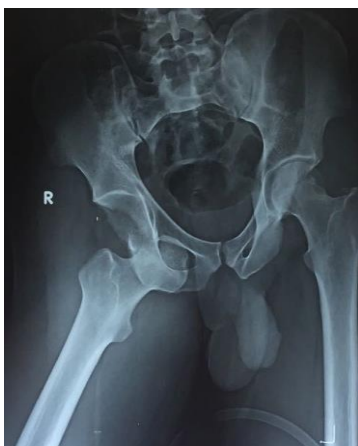Patient was scheduled for closed reduction under general anaesthesia within 2 hours. Patient was shifted to operation theatre and under effect of anaesthesia patient was shifted on floor and reduction was achieved with Allis's maneuver.

In this procedure patient was kept in supine position, knee was flexed to relax the hamstrings, with an assistant stabilising the pelvis and lateral traction force was applied to the inside of the thigh. Longitudinal traction is applied in line with axis of the femur, and the hip is slightly flexed. Then gently adduct and internally rotate the femur to achieve reduction.

After reduction with slight traction Thomas split was applied right lower limb and check x-ray of pelvis with both hips was taken and reduction was confirmed (Figure 3). Thomas splint was continued for 3 weeks.

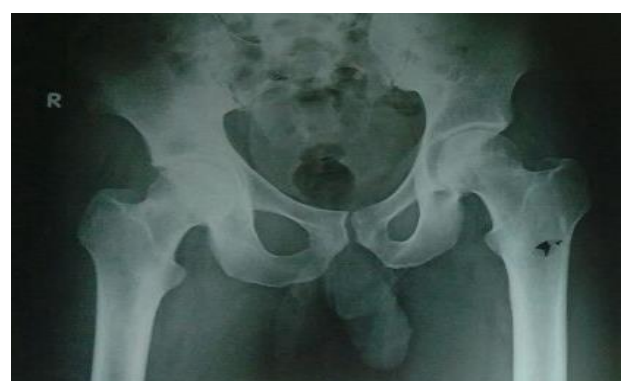

**Figure 3: Post reduction x-ray of pelvis with both hips AP view with Thomas splint in situ.**



**Figure 2: X-ray of pelvis with both hips anteroposterior view showing obturator (inferior) type anterior dislocation of right hip.**

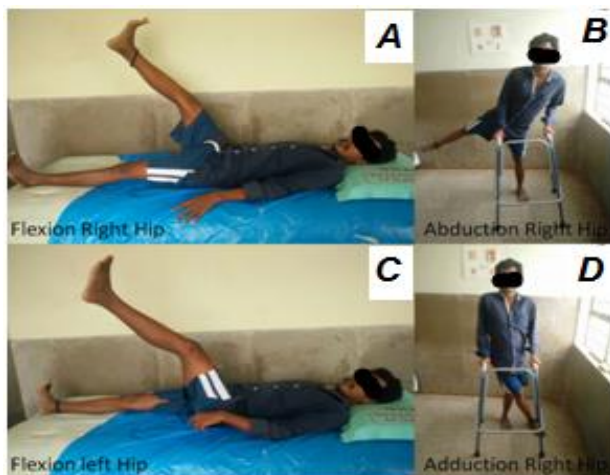
After vitals monitoring patient was shifted for x-ray of pelvis including both hip joints anteroposterior view. On x-ray patient was diagnosed as obturator type anterior right hip dislocation (Figure 2).



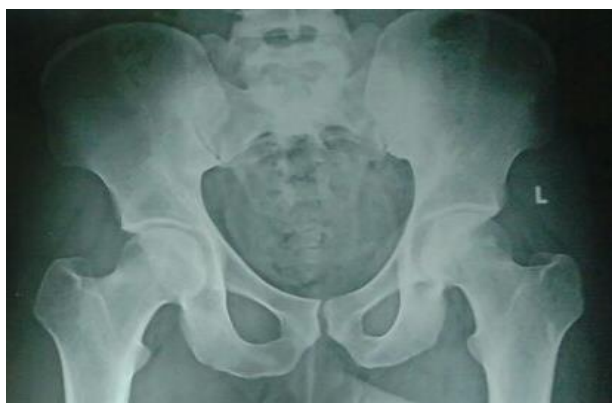**Figure 4: Post reduction 6 weeks x-ray of pelvis with both hips.**

After 3 weeks patient was reviewed in OPD where Thomas splint was removed and range of movements of right hip were assessed. Patient was advised for progressive mobilisation assisted with help of walker and partial weight bearing for further 3 weeks avoiding abduction and external rotation of right hip (Figure 4). And after of total 6 weeks of reduction patient was

advised for complete weight bearing and to review after 1 month (Figure 5).



**Figure 5: Post reduction 6 weeks movements: (A) Flexion of right hip; (B) abduction of right hip; (C) flexion of left hip; (D) adduction of left hip.**



**Figure 6: Post reduction 6 months check x-ray without any osteonecrotic changes of right femoral head.**

On 6 months follow up patient came without any complaints of pain and with complete normal range of movements of right hip. X-ray was taken and assessed for any osteonecrotic changes which were absent (Figure 6).

## DISCUSSION

According to the position of femoral head, anterior hip dislocations can be divided into 2 types either pubic or obturator. Pubic type being superior and obturator is inferior type of dislocation.<sup>3,4</sup>

Inferior type of anterior hip dislocation is the most uncommon injury, accounting of <5% of all hip dislocations.<sup>4,5</sup>

Because of strong anterior capsule and the ligament of Bigelow anterior hip dislocations chances are less. They

occur as a result of the forced abduction, external rotation and flexion of the hip joint.<sup>6</sup>

Being an orthopaedic emergency, hip dislocation should be reduced under general anaesthesia.<sup>8,9</sup>

Chance of avascular necrosis is about 50% if hip is not reduced before 6 hours of the dislocation. In our case it was relocated under 4 hours.

3 to 6 weeks of immobilisation and traction is advisable for capsular healing followed by progressive mobilization and loading.<sup>11,12</sup>

After immobilization of hip till 6 weeks pt was encouraged for walk with walker or support for 3 weeks and advised not to squat or sit with crossed leg. And after 3 weeks complete weight bearing has to start gradually. CT scan is also advisable at regular interval to rule out the avascular necrosis changes in hip. In our case as patient was not affordable, was not done.

## CONCLUSION

Anterior hip dislocation obturator (inferior) type in young patient is rare due to deep position in the pelvis with strong ligaments and muscles. Early diagnosis and treatment are crucial in the management of this injury to prevent osteonecrosis of femoral head.

*Funding: No funding sources*

*Conflict of interest: None declared*

*Ethical approval: Not required*

## REFERENCES

1. Croft SJ, Brenchley J, Badhe SP, Cresswell TR. An unusual rugby injury. *Emergency Med J.* 2006;23(6):e40.
2. Frederick M. Azar, James H. Beaty, S. Terry Canale, Campbell's operative orthopaedics 13th Edition, chapter 55. Elsevier; 2016: 2852.
3. Phillips AM, Konchwalla A. The pathologic features and mechanism of traumatic dislocation of the hip. *Clin Orthop Relat Res.* 2000;(377):7-10.
4. Epstein HC. Traumatic dislocations of the hip. *Clin Orthop Relat Res.* 1973;(92):116-42.
5. Dawson I, van Rijn AB. Traumatic anterior dislocation of the hip. *Arch Orthop Trauma Surg.* 1989;108(1):55-7.
6. DeLee JC. Fractures and dislocations of the hip. In: Rockwood CA Jr, Green DP, editors. *Fractures in adults.* 4th ed. Vol. 2. Lippincott Raven, Philadelphia; 1996: 1756-1803.
7. Sneath RJ, Morgan NP. Bilateral traumatic anterior dislocation of the hip joint. *J Accid Emerg Med.* 1997;14(6):391.
8. Duygulu F, Karaoglu S, Kabak S, Karahan OI. Bilateral obturator dislocation of the hip. *Arch Orthop Trauma Surg.* 2003;123(1):36-8.

9. Lam F, Walczak J, Franklin A. Traumatic asymmetrical bilateral hip dislocation in an adult: a case report. *Emerg Med J.* 2001;18(6):506–7.
10. Toms AD, Williams S, White SH. Obturator dislocation of the hip. *J Bone Joint Surg.* 2001;83(1):113–5.
11. Mowery C, Gershuni DH. Fracture dislocation of the femoral head treated by open reduction and internal fixation. *J Trauma.* 1986;26(11):1041–4.
12. Amihood S. Anterior dislocation of the hip. *Injury.* 1975;7(2):107–10.

**Cite this article as:** Kulambi V, Chaudhari K, Pethapara V. Anterior hip dislocation in young patient obturator (inferior) type: a rare case report. *Int J Res Orthop* 2018;4:523-6.