

Original Research Article

A study of intra articular calcaneal fractures treated with minimally invasive cannulated screw fixation

B. Sundararaja, L. Senthil*, U. Thyagarajan, D. Gokulraj

Department of Orthopaedics Surgery, Sri Ramachandra Medical College, Chennai, Tamil Nadu, India

Received: 07 December 2017

Revised: 18 January 2018

Accepted: 19 January 2018

*Correspondence:

Dr. L. Senthil,

E-mail: lsenthil_dr@yahoo.co.in

Copyright: © the author(s), publisher and licensee Medip Academy. This is an open-access article distributed under the terms of the Creative Commons Attribution Non-Commercial License, which permits unrestricted non-commercial use, distribution, and reproduction in any medium, provided the original work is properly cited.

ABSTRACT

Background: The management of displaced intra-articular calcaneal fractures (DIACFs) remains challenging and controversial. A prospective study to assess the functional outcome of patients with displaced intra-articular calcaneal fractures treated with percutaneous reduction, cannulated screw fixation.

Methods: Ultimately, 14 patients with a DIACFs, underwent percutaneous reduction, cannulated screw fixation. Functional outcomes were evaluated using the American Orthopaedic Foot and Ankle Society (AOFAS) hind foot scores. Radiological results were assessed using plain radiographs and computed tomography (CT) scans, and postoperative wound-related complications were also recorded.

Results: A total of 46 adult patients were assessed in our study. Twenty patients did not meet the inclusion criteria and were excluded. Twelve patients were excluded due to severe medical ailments (2 patients) and non-adherence to the treatment plan (10 patients). Therefore, 14 patients with an average age of 42.5 years old (range, 20 to 72 years) including 10 men and 4 women participated in the study. All patients were followed-up for 12 months averagely (range, 11 to 18 months). Complete articular reduction is achieved in 8 patients, 6 patients had articular depression of posterior facet, 3 patients had heel widening and lateral impingement. There was no wound complications in any of the patients, 2 patients developed sub talar arthritis at 2 years of follow up.

Conclusions: Surgical treatment of intra articular calcaneal fractures remains challenging task. Minimally invasive reductions remain good option to minimize wound complications. Cannulated cancellous screw fixation is good option for intra articular calcaneal fracture.

Keywords: Calcaneus, Intra-articular fractures, Minimally invasive, Percutaneous fixation

INTRODUCTION

Calcaneal fractures constitute above 70% of all tarsal injuries.¹ Majority of the calcaneal Fractures are treated non operatively.²⁻⁵ Intra articular fractures often lead to sub talar arthritis with gross limitation of function.^{6,7} The management of displaced intra-articular calcaneal fractures (DIACFs) remains challenging and controversial. Open reduction and internal fixation (ORIF) through an extensile lateral approach has been widely accepted and established as a standard treatment

for DIACFs.^{2,3} However, a fairly high wound-related complication rate has been reported with this approach, including wound edge necrosis, dehiscence, hematoma, infection and injury to the sural nerve.⁴⁻⁷

In an attempt to lower the complication rate, various minimally invasive techniques have recently been introduced, including external fixation, percutaneous fixation, arthroscopically assisted fixation, and minimal incision techniques via medial, modified lateral (such as the sinus tarsi approach), longitudinal, or combined

approaches.⁸⁻¹⁴ Minimally invasive techniques have been reported as effective in minimizing soft tissue trauma, thereby reducing the incidence of wound-related complications. The soft tissues remain major challenge in treating these injuries. Minimally invasive technique is a good option in maintaining articular reduction and soft tissue integrity.

As one of the most popular and effective minimally invasive techniques, the sinus tarsi approach not only can fully expose the posterior facet and the anterolateral fragment, but it also significantly reduces the incidence of postoperative wound complications.^{11,12,15} In order to further shorten the operative time and decrease the wound complication rate, we introduced, in 2006, percutaneous reduction, cannulated screw fixation.¹⁶ The purpose of the present study was to assess the functional and radiological outcomes and complications of our percutaneous reduction, cannulated screw fixation for treatment of DIACFs.

METHODS

Subjects

Patients with intra-articular calcaneal fracture, who were the consecutive candidates for surgical treatment at Sri Ramachandra University hospital from January 2010 to December 2014, were allocated to the percutaneous reduction, cannulated screw fixation.

The inclusion criteria were: 1) All patients with intra-articular calcaneal fracture; 2) the age was greater than or equal to 18 years old; and 3) closed fracture.

The exclusion criteria were: 1) severe medical ailments (severe vascular or neurologic injury, diabetes) or contraindications (known local or systemic infection); 2) severe and polytraumatic injuries or polytrauma of the ipsilateral lower limb when admitted; and 3) refused to accept the treatment plan.

Statistical analysis

Statistical analysis was performed with SPSS 17.0 software for Windows. Continuous data with a normal distribution were expressed as the mean±standard deviation. The Mann-Whitney U test and non-paired t test were used to compare differences continuous variables with non-normal distributions and approximately normally distributed respectively.

Preoperative management

All patients were evaluated using preoperative calcaneal radiographs and computed tomography (CT) scans and two-dimensional reconstruction of the injured foot.

Surgical techniques

All surgeries were performed with Patients placed in the lateral decubitus position and under spinal anaesthesia and c-arm guidance. Firstly, Steinman pin is inserted in posterior inferior portion of calcaneus. Then In axial view varus, valgus angulation is corrected and provisionally fixed with Kirschner wires. In lateral view joint depression is elevated using bone taps and fixed with Kirschner wires. In tongue depression fractures Kirschner wire is inserted lateral to Achilles tendon and elevated. All provisionally fixed Kirschner wires are replaced with cannulated cancellous screws (Figure 1).

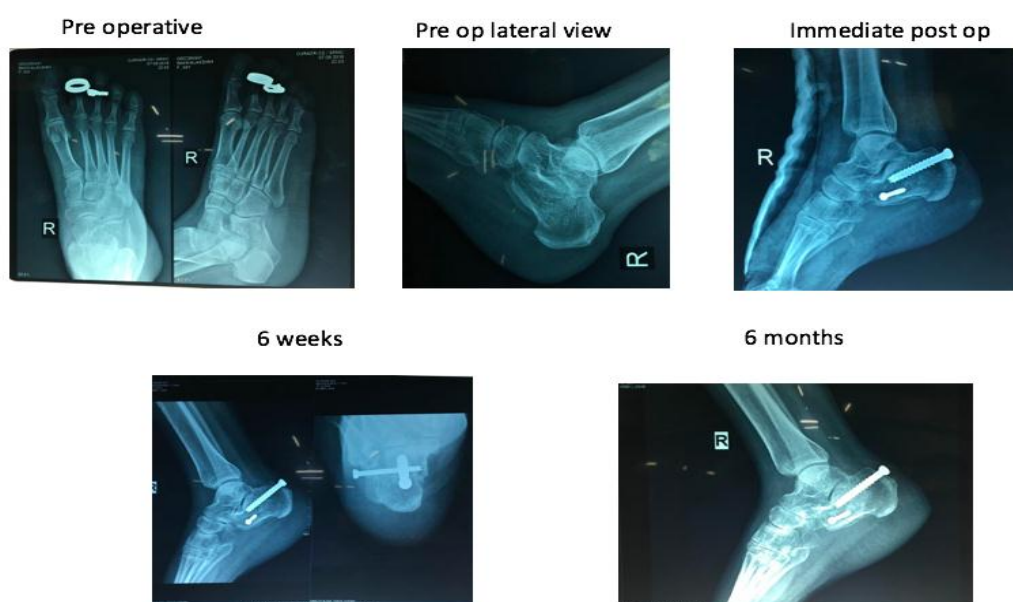

Figure 1: Surgical technique and radiological evaluation during follow up.

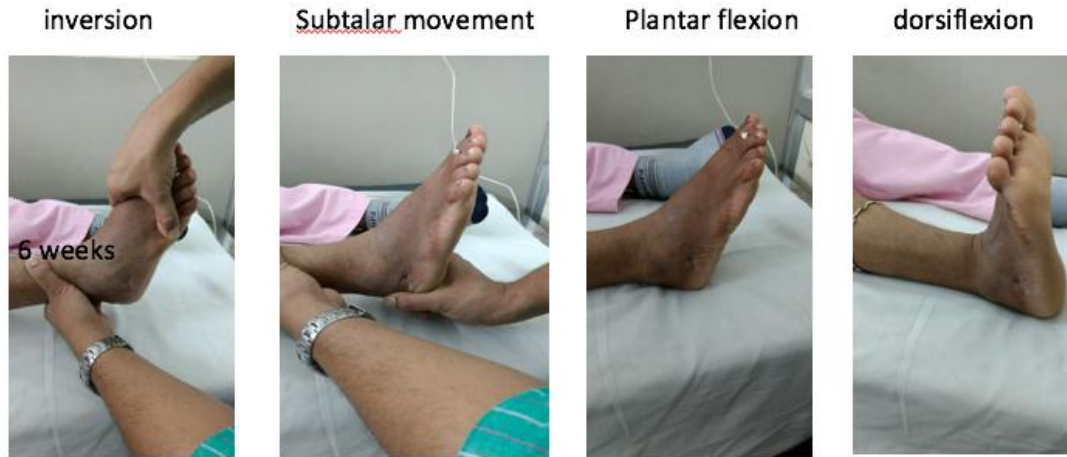


Figure 2: Functional assessment as per AOFAS hind score.

Postoperative management

All patients underwent the same postoperative management protocol. The patients were encouraged to do non-weight-bearing exercises including extension and plantar flexion as early as the pain could be endured and use crutch while walking two or three days postoperatively. Partial weight-bearing was permitted at six weeks post-operation and then progressed gradually. Full weight-bearing was not allowed until bony union confirmed on radiographs. X-rays are taken at 6, 12 and 24 weeks. Bone grafting and bone substitutes was not used in any of our patients.

Clinical evaluation

The functional outcomes were assessed using the American Orthopaedic Foot and Ankle Society (AOFAS) hind foot scores 17 at the 12-month follow-up (Figure 2). The postoperative wound-related complications were also recorded.

RESULTS

A total of 46 adult patients were assessed in our study. Twenty patients did not meet the inclusion criteria and were excluded. Twelve patients were excluded due to severe medical ailments (2 patients) and non-adherence to the treatment plan (10 patients). Therefore, 14 patients with an average age of 42.5 years old (range, 20 to 72 years) including 10 men and 4 women participated in the study. All patients were followed-up for 12 months averagely (range, 11 to 18 months).

According to the Sanders classification, there were 12 type-ii fractures and 2 type-III fractures. Fall from height (10 fractures) were the primary injury mechanisms, besides motor- vehicle accident (4 fractures). Average time from initial injury to operation was 1.6 days. Average operation time was 43.6 min. According to the

AOFAS scoring system, 10 fractures were assessed as excellent; 2 as good; 2 as fair. Among the patients who achieved good or excellent results, there were 12 Type-II fractures and 2 Type-III fractures. The mean time from surgery to partial weight-bearing was 6.2 weeks. Complete articular reduction is achieved in 8 patients, 6 patients had articular depression of posterior facet, 3 patients had heel widening and lateral impingement. There was no wound complications in any of the patients, 2 patients developed sub talar arthritis at 2 years of follow up.

Table 1: Baseline characteristics.

General information	Mean/percentage
Age	42.5 (20 to 70 years)
Sex	
Male	10 (71.42)
Female	4 (28.58)
Sanders classification	
Type II	12 (85.72)
Type III	2 (14.28)
Injury mechanism	
Fall from height	10 (71.42)
Road traffic accident	4 (28.58)
Time to operation	1.6 days
Operation time	43.6 min

DISCUSSION

Displaced intra-articular calcaneal fractures management remains controversial. Complete articular reduction is achieved in 55% of patients this is low as complete articular reduction 70% achieved with open reduction and internal fixation various fixation methods including multiple k wire fixation is advocated. In our study fixation was done with cannulated cancellous screws. The infection with k-wire fixation is 35% which is significantly higher than cannulated cancellous screw fixation (5%).

Recent studies have shown a trend toward better functional outcomes in the operatively managed groups than those treated non-operatively.^{18,19} However, the major concern about wound-related complications with the extensile lateral L-shaped approach has troubled many orthopaedic surgeons with complication rate reported to range from 11 to 25%.^{20,21} Percutaneous reduction, cannulated screw fixation were introduced in 2006 for treatment of DIACFs. In this study, we aimed to assess the functional outcomes, radiographic results and the postoperative wound-related complications of the minimally invasive percutaneous fixation approach among patients from tertiary centre in south India.

The assessment of functional outcomes in our study revealed an overall good to excellent rate of 84.0%. The mean AOFAS score was 86.6. The results analysis from the AOFAS scoring system suggested these patients suffered from less pain, less activity limitations, less gait abnormality, and less demand on walking surfaces. Meanwhile, they obtained better sagittal motion and hind foot motion. Wang YM et al reported percutaneous reduction and Steinman pin fixation minimized complications and achieved functional outcomes comparable to those of the open techniques in patients with Sanders Type-II calcaneal fractures.²² Mulcahy et al also suggested that a minor residual step-off of the posterior facet could cause a significant load shift within the subtalar joint, which might have an adverse effect on functional outcome.²³⁻²⁵

There are a few limitations in this study. First, we had a relatively small number of patients and short average follow-up time. Therefore, further investigation with a larger sample size and longer follow-up time is needed to obtain more overall clinical data.

CONCLUSION

Surgical treatment of intra articular calcaneal Fractures remains challenging task. However minimally invasive reductions remains good option to minimize wound complications. Ideal methods of fixations still remains debate. Cannulated cancellous screw fixation is good option for intra articular calcaneal fracture.

Funding: No funding sources

Conflict of interest: None declared

Ethical approval: The study was approved by the institutional ethics committee of Sri Ramachandra University

REFERENCES

- Rammelt S, Zwipp H. Calcaneus fractures: facts, controversies and recent developments. *Injury*. 2004;35:443–61.
- Sanders R. Displaced intra-articular fractures of the calcaneus. *J Bone Joint Surg Am*. 2000;82:225–50.
- Buckley R, Tough S, McCormack R, Pate G, Leighton R, Petrie D, et al. Operative compared with nonoperative treatment of displaced intra-articular calcaneal fractures: a prospective, randomized, controlled multicenter trial. *J Bone Joint Surg Am*. 2002;84:1733–44.
- Howard JL, Buckley R, McCormack R, Pate G, Leighton R, Petrie D, et al. Complications following management of displaced intra-articular calcaneal fractures: a prospective randomized trial comparing open reduction internal fixation with nonoperative management. *J Orthop Trauma*. 2003;17:241–9.
- Koski A, Kuokkanen H, Tukiainen E. Postoperative wound complications after internal fixation of closed calcaneal fractures: a retrospective analysis of 126 consecutive patients with 148 fractures. *Scand J Surg*. 2005;94:243–5.
- Cavadas PC, Landin L. Management of soft-tissue complications of the lateral approach for calcaneal fractures. *Plast Reconstr Surg*. 2007;120:459–66.
- Al-Mudhaffar M, Prasad CV, Mofidi A. Wound complications following operative fixation of calcaneal fractures. *Injury*. 2000;31:461–4.
- Ramos RR, de Castro Filho CD, Ramos RR, Bittar CK, de Cillo MS, de Mattos CA, et al. Surgical treatment of intra-articular calcaneal fractures: description of a technique using an adjustable uniplanar external fixator. *Strategies Trauma Limb Reconstr*. 2014;9:163–6.
- Rammelt S, Heineck J, Barthel S, Zwipp H. Percutaneous fixation of intraarticular calcaneus fractures. *Techn Foot Ankle Surg*. 2009;8:70–6.
- Sampath Kumar V, Marimuthu K, Subramani S, Sharma V, Bera J, Kotwal P. Prospective randomized trial comparing open reduction and internal fixation with minimally invasive reduction and percutaneous fixation in managing displaced intra-articular calcaneal fractures. *Int Orthop*. 2014;38:2505–12.
- Schuberth JM, Cobb MD, Talarico RH. Minimally invasive arthroscopic- assisted reduction with percutaneous fixation in the management of intra-articular calcaneal fractures: a review of 24 cases. *J Foot Ankle Surg*. 2009;48:315–22.
- Hospodar P, Guzman C, Johnson P, Uhl R. Treatment of displaced calcaneus fractures using a minimally invasive sinus tarsi approach. *Orthopedics*. 2008;31:112.
- Schepers T. The sinus tarsi approach in displaced intra-articular calcaneal fractures: a systematic review. *Int Orthop*. 2011;35:697–703.
- Zhang T, Su Y, Chen W, Zhang Q, Wu Z, Zhang Y. Displaced intra-articular calcaneal fractures treated in a minimally invasive fashion: longitudinal approach versus sinus tarsi approach. *J Bone Joint Surg Am*. 2014;96:302–9.
- Yeo JH, Cho HJ, Lee KB. Comparison of two surgical approaches for displaced intra-articular calcaneal fractures: sinus tarsi versus extensile

- lateral approach. *BMC Musculoskelet Disord.* 2015;16:63.
16. Chen L, Zhang G, Hong J, Lu X, Yuan W. Comparison of percutaneous screw fixation and calcium sulfate cement grafting versus open treatment of displaced intra-articular calcaneal fractures. *Foot Ankle Int.* 2011;32:979–85.
 17. Kitaoka HB, Alexander IJ, Adelaar RS, Nunley JA, Myerson MS, Sanders M. Clinical rating systems for the ankle-hindfoot, midfoot, hallux, and lesser toes. *Foot Ankle Int.* 1994;15:349–53.
 18. Radnay CS, Clare MP, Sanders RW. Subtalar fusion after displaced intra-articular calcaneal fractures: does initial operative treatment matter? *J Bone Joint Surg.* 2009;91:541–6.
 19. De Boer AS, Van Lieshout EM, Den Hartog D, Weerts B, Verhofstad MH, Schepers T. Functional outcome and patient satisfaction after displaced intra-articular calcaneal fractures: a comparison among open, percutaneous, and nonoperative treatment. *J Foot Ankle Surg.* 2015;54:298–305.
 20. Rak V, Ira D, Masek M. Operative treatment of intra-articular calcaneal fractures with calcaneal plates and its complications. *Indian J Orthop.* 2009;43:271–80.
 21. Backes M, Schepers T, Beerekamp MS, Luitse JS, Goslings JC, Schep NW. Wound infections following open reduction and internal fixation of calcaneal fractures with an extended lateral approach. *Int Orthop.* 2014;38:767–73.
 22. Wang YM, Wei WF. Sanders II type calcaneal fractures: a retrospective trial of percutaneous versus operative treatment. *Orthop Surg.* 2015;7:31–6.
 23. Mulcahy DM, McCormack DM, Stephens MM. Intra-articular calcaneal fractures: effect of open reduction and internal fixation on the contact characteristics of the subtalar joint. *Foot Ankle Int.* 1998;19:842–8.
 24. Song KS, Kang CH, Min BW, Sohn GJ. Preoperative and postoperative evaluation of intra-articular fractures of the calcaneus based on computed tomography scanning. *J Orthop Trauma.* 1997;11:435–40.
 25. Gavlik JM, Rammelt S, Zwipp H. The use of subtalar arthroscopy in open reduction and internal fixation of intra-articular calcaneal fractures. *Injury.* 2002;33:63–71.

Cite this article as: Sundararaja B, Senthil L, Thyagarajan U, Gokulraj D. A study of intra articular calcaneal fractures treated with minimally invasive cannulated screw fixation. *Int J Res Orthop* 2018;4:249-53.