

Original Research Article

Functional outcome of calcaneal locking compression plate

George Thomas, Jinny John*

Department of Orthopaedics, Government Medical College, Kottayam, Arpookara, Kerala, India

Received: 28 November 2017

Revised: 02 March 2018

Accepted: 05 March 2018

***Correspondence:**

Dr. Jinny John,

E-mail: jinnyjohn@gmail.com

Copyright: © the author(s), publisher and licensee Medip Academy. This is an open-access article distributed under the terms of the Creative Commons Attribution Non-Commercial License, which permits unrestricted non-commercial use, distribution, and reproduction in any medium, provided the original work is properly cited.

ABSTRACT

Background: The calcaneus is the frequently injured tarsal bone. 75% of calcaneal fractures are intraarticular. Treating calcaneal fractures is a challenge for orthopaedic surgeon due to complex fracture pathology. Our aim is to evaluate the functional outcome of calcaneum Locking compression plate in patients with intraarticular calcaneal fractures with Bohler's angle <20 degree who are admitted in the department of Orthopaedics, Government Medical College, Kottayam.

Methods: In this study, 41 patients with 42 intraarticular calcaneal fractures were operated on with locking compression plate through lateral approach during the period of July 2015 to December 2016. Radiological evaluation done with X-rays. Bohler's angle was measured from lateral view and those patients with angle <20° were selected for study. Patients were followed up clinically and radiologically for 24 weeks. Radiological assessment was done by Bohlers angle. Functional outcome was assessed using American Orthopaedic Foot and Ankle Society (AOFAS) scale.

Results: At 24 weeks follow up, 90.5% of the study population had excellent to good functional outcome and 9.5% had fair and none had poor result. All patients had stable hind foot with all having good dorsiflexion and plantar flexion. But some patients had limited inversion and eversion. The mean postoperative Bohler's angle was 30.02±3.97.

Conclusions: Open reduction and internal fixation with locking compression plate gives sound functional outcome, if the surgery is well timed. Anatomical articular reduction especially of the posterior facet to be achieved and restoration of Bohler's angle to normal range to be attempted.

Keywords: Intraarticular calcaneal fractures, Bohlers angle, Internal fixation

INTRODUCTION

The calcaneum is the most commonly fractured tarsal bone. Calcaneal fractures comprise 1-2% in adults.^{1,2} Most of the calcaneal fractures are intraarticular and almost all occur due to an axial load such as a fall from height. Intraarticular calcaneal fractures have significant importance as poor outcomes of treatment are associated with poor health status. Calcaneal fractures are mostly work related, as they result from a fall from height

especially in males aged 35-45 years. These fractures frequently result in long term disability with potentially severe economic impact on the patient.

Fractures of the calcaneus are typically the result of high-energy trauma, such as a fall from a height or a motor vehicle accident. The pattern of fracture lines and extent of comminution are determined by the position of the foot, the amount of force, and the porosity of the bone at the time of impact.

Treating calcaneal fractures is a challenge for orthopaedic surgeon. A wide range of treatment options varying from non-operative to operative methods are available. Studies conducted by Batra, Makki et al, Wu et al all had results favouring open reduction and internal fixation with plate and screws.³⁻⁵ The purpose of this study is to assess the functional outcome of calcaneal locking compression plate in patients with intraarticular calcaneal fractures with Bohler's angle <20 degree.

METHODS

A descriptive study on 41 patients with 42 intraarticular fractures who were admitted in Government medical college, Kottayam during July 2015 to December 2016 were treated with open reduction and locking compression plating.

Inclusion criteria

All patients 18-60 yrs of age with intraarticular calcaneum fractures with Bohler's angle <20 degree, fractures less than 3 weeks old.

Exclusion criteria

Extraarticular calcaneal fractures, open fractures, undisplaced intraarticular fractures, ipsilateral limb fracture, polytrauma, patients with arthritis, abnormal gait, those with congenital defects of ankle, neurovascular injuries, tendon injury, ankle dislocation, fracture of other tarsal bones.

Surgeries are done after the appearance of wrinkle sign. Under proper aseptic precautions and preoperative antibiotic cover the surgeries are done. Our protocol in management of calcaneal fractures is immediate temporary plaster stabilization. Elevation of the fractured limb to reduce the swelling are utilised in the initial management. CT scan was used to assess the fracture pattern and the amount of comminution.

The patient is placed lateral on a radiolucent table. Antibiotic prophylaxis is administered, and standard intra-operative fluoroscopy was used throughout the procedure. Both the injured and the non-injured limb are prepared and draped above the knee, thus allowing intra-operative alignment to be checked against the uninjured limb. Benirschke and Sangeorzan technique (Figure 1A).⁶ After exposure is complete lateral wall of calcaneum is removed. If there is a fracture line between anterior process and sustentacular process, that is reduced first. Tuberosity is reduced to sustentacular fragment by manipulating with a threaded Steinmann pin. It is then provisionally fixed with a Kirschner wire. Then depression of posterior facet is reduced and provisionally fixed. We used bone graft in most of the cases as there was void after the reduction of articular surface. Lateral wall is reduced and fixed by using calcaneal locking compression plate laterally (Figure 1B). Plate should

extend from anterior process of calcaneus to the most posterior aspect of the tuberosity. Intraoperative radiographs are obtained using C-arm to confirm the reduction (Figure 1C). After completing fixation flap is closed and a below knee slab is applied. Post operatively regular wound inspection will be done, followed by suture removal on ninth postoperative day, and application of POP Cast. The casts will be removed after 6 weeks. No weight-bearing will be allowed till 12 weeks. Weight bearing will be started from 12 weeks along with range of movement exercises. Reviews will be done, and functional outcome will be recorded using AOFAS (American Orthopaedic foot and ankle society) scoring system at 6 weeks, 12 weeks and 24 weeks (Figure 1D) after the index procedure.

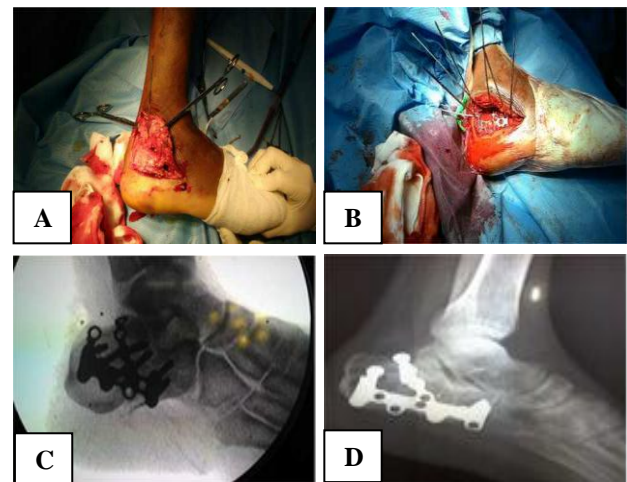


Figure 1 (A-D): A=Lateral approach to the calcaneum, B=Intraoperative picture showing plate fixation, C=Intraoperative fluoroscopic picture, D=Postoperative radiograph at 24 weeks follow-up.

RESULTS

Most of the patients were between 21 and 40 years (47.6%) of age. Mean age of the study population was 38.05 years.

Table 1: Distribution of study population according to age.

Age group	Number of patients	Percentage (%)
<20	4	9.5
21-40	20	47.6
41-60	18	42.9
Total	42	100

Table 2: Distribution of study population according to gender.

Gender	Number of patients	Percentage (%)
Male	38	90.5
Female	4	9.5
Total	42	100

Mechanism of injury in majority of the study population was fall from height (90.5%) and road traffic accident constitutes 9.5%.

Among complications following surgery, skin necrosis was seen in 21.4% of the study population and all other complications like infection, wound dehiscence were less. None of the patient had malreduction, sural nerve injury or peroneal tendon injury. Mean preoperative Bohler's angle was 10.43 and that postoperatively was 30.02. This difference was found to be statistically significant with a t value of 22.313 at $p < 0.001$.

Table 3: AOFAS score at 24 weeks postoperatively.

AOFAS score	Number of patients	Percentage (%)
Excellent	31	73.8
Good	7	16.7
Fair	4	9.5
Poor	0	0
Total	42	100

Excellent results were noted in 73.8% patients and majority of the patients (90.5%) had excellent-good functional outcome at 24 weeks postoperatively (Table 3), though only 52.4% of the study population had excellent-good functional outcome at 12 weeks follow up.

Among the study population, 76.3% of those who were treated after 1 week i.e., after wrinkle sign had appeared, had excellent result. On assessing the association between smoking and skin necrosis, smokers had more (25%) skin necrosis than non-smokers (20%). But there was no statistical significance with a Chi-Square value of 0.127 at $p < 0.721$. On assessing the association of duration between injury and treatment and wound dehiscence, those who got treatment within 1 week had more (25%) wound dehiscence than those got after 1 week (5.3%).

DISCUSSION

Calcaneum intraarticular fractures are common as compared to extraarticular fractures, hence the importance of anatomical reduction to decrease the possibility of joint incongruity and subtalar arthritis. Open reduction and internal fixation is now more aggressively advocated for management of intraarticular fractures of calcaneum. 41 patients with intraarticular calcaneal fractures were admitted in Department of Orthopaedics, Medical College, Kottayam, for treatment between July 2015 to December 2016.

In our study most of the patients were between 21 and 40 years of age with a mean age of 38.05 ± 11.98 years. Parmar noticed age range between 16-64 with mean age 50.9 years and Buckley noted that in his study the maximum age incidence was between 30-39 years.⁷

90.5% of the study population were males and majority were manual labourers.

We compared pre and postoperative Bohlers angle and it was found that mean preoperative Bohlers angle was 10.43 ± 4.7 and postoperative was 30.02 ± 3.97 . Similar study was done by Makki et al in 2010.⁴ They have done a retrospective review of 47 intraarticular fractures of calcaneum treated by open reduction and fixation. They concluded that restoration of Bohler's angle was associated with better outcome.

Surgical technique, soft tissue dissection and local conditions are most important in determining the success of surgery and rate of infections. Though CT scanning is better we found accurate radiological evaluation is adequate in planning operative management. Primary subtalar arthrodesis may be good option in severely comminuted intraarticular fractures.

AOFAS clinical rating system the ankle hindfoot scale for calcaneal area is a standard scoring system for foot function evaluation. Using this standard scoring system that takes into account subjective and objective assessments enables to achieve relevant results and comparisons of different patient's studies.

To conclude, well timed open reduction and internal fixation with locking compression plate in an indicated case, respecting soft tissue envelope and early rehabilitation lead to therapeutic success. Lateral approach with minimal soft tissue handling reduces skin complications. Anatomical articular reduction especially of the posterior facet to be achieved and restoration of Bohlers angle to normal range to be attempted. Long term study is needed to know about long term results.

AKNOWLEDGEMENTS

I wish to express my sincere gratitude to Dr. M.A. Thomas, the Head of the Department of Orthopaedics, Government Medical College, Kottayam for his valuable suggestions and expert guidance throughout the period of the study.

Funding: No funding sources

Conflict of interest: None declared

Ethical approval: The study was approved by the institutional ethics committee

REFERENCES

- O'Connell F, Mital MA, Rowe CR. Evaluation of modern management of fractures of the os calcis. Clin Orthop. 1972;83:214-23.
- Slatis K, Kiviluoto O, Santavirta S, Laasonen EM. Fractures of the calcaneum. J Trauma. 1979;19:939-43.
- Batra GS, Jain B. Management of fractures of calcaneum. J Orthop. 2009;6:36-40.

4. Makki D, Alnajjar HM, Walkay S, Ramkumar U. Osteosynthesis of displaced intraarticular fractures. *J Bone Joint Surg*. 2010;92:693-700.
5. Wu Z, Su Y, Chen W, Zhang Q, Liu Y, Li M, et al. Functional outcome of displaced intra-articular calcaneal fractures: A comparison between open reduction/internal fixation and a minimally invasive approach featured an anatomical plate and compression bolts. *J Trauma Acute Care Surg*. 2012;73(3):743-51.
6. Benirschke SK, Sangeorzan BJ. Extensive intraarticular fractures of the foot: surgical management of calcaneal fractures. *Clin Orthop*. 1993;292:128-34.
7. Parmar HV, Triffitt PD, Gregg PJ. Intraarticular fractures of the calcaneum treated operatively or conservatively; a prospective study. *J Bone Surg Br*. 1993;75(6):932-7.

Cite this article as: Thomas G, John J. Functional outcome of calcaneal locking compression plate. *Int J Res Orthop* 2018;4:493-6.