

Original Research Article

Tumour like lesions and their management: a retrospective study

Kuriakku Puthur Dominic, Davis Dijoe*, Libin Thomas Manathara

Department of Orthopedics, Amala Institute of Medical Sciences, Amala Nagar, Thrissur, Kerala, India

Received: 04 November 2017

Accepted: 06 December 2017

***Correspondence:**

Dr. Davis Dijoe,
E-mail: dr.dijoe@gmail.com

Copyright: © the author(s), publisher and licensee Medip Academy. This is an open-access article distributed under the terms of the Creative Commons Attribution Non-Commercial License, which permits unrestricted non-commercial use, distribution, and reproduction in any medium, provided the original work is properly cited.

ABSTRACT

Background: Tumour like lesions of the bone is a frequently used term but has not yet been clearly defined. There are no definite guidelines available for their management. The present study was aimed to evaluate the tumour like lesions and their management.

Methods: Cases of tumour like lesions managed in the Cancer Institute during the last two decades were systematically analyzed. By and large non aggressive and non-operative treatment was given in all conditions.

Results: One hundred and twenty seven cases of tumour like lesions managed. As they are not tumours, basics of tumour surgery need not be applied to them. Outcome of conservative management of tumour like lesions was very encouraging on long term follow-up.

Conclusions: Most of the cases with lesser interventions produced better results. They need to be treated only if they are symptomatic or likely to produce a pathological fracture. Even in such situations, one need not take a radical approach.

Keywords: Tumour like lesions, Cytogenetics, Pathological fracture

INTRODUCTION

Tumor-like lesions of bone are lesions having appearance and cytogenetic characteristics of neoplasm but their clinical behavior supports a non-neoplastic nature.¹ Significance of the tumor-like bony lesions is that, they are very common and their radiological appearance mimics that of true bone tumors including malignant lesions. Tumor like bone lesions can be latent like non ossifying fibroma or active like simple bone cyst or aggressive like aneurysmal bone cysts.^{2,3} There are no definite guidelines available for their management. They need not be treated as aggressively as other bone tumours. The present study was aimed to evaluate the tumour like lesions and their management.

METHODS

Study design and subjects

A retrospective study was conducted on cases of tumour like lesions managed in the Cancer Institute during the last two decades. All the cases presented between 1st January 1990 to 31st December 2015 conforming to the listed diseases in table 1 clinically, radiologically or histopathologically were included in the study. The classification system followed was a conglomerate of classification systems for bone tumours proposed by various authors.⁴⁻⁸ Patients who were lost on follow-up and patients presented with a different clinical and histological picture on follow up were excluded. All the cases were followed up clinically and radiologically at

regular intervals. Repeat biopsy was done whenever a deviation observed from the natural course of the disease. Since the diseases and the sites involved are varied, we couldn't apply a single outcome measurement for all the cases.

Cystic lesions

Simple bone cyst

All cases in humerus were presented with pathological fracture following trivial trauma. Relative distribution of the cases is consistent with available literature.^{9,10} Diagnosis is done by clinical presentation, typical x-ray appearance and by CT guided aspiration of the fluid through the cortical break. If aspirated fluid is straw colored or slightly blood stained fluid, methylprednisolone acetate (depomedrol) injection is done through the same needle.

Most of the cases of proximal femur presented with pathological fracture. All lesions in the calcaneum were incidental findings.

Aneurysmal bone cyst (ABC)

All cases were treated surgically till 2010 until the introduction of polidocanol.

Fibrous lesions

Fibrous dysplasia

Proximal femoral lesions were treated initially, by impacting fibular graft intramedullary across the lesion without disturbing the lesion (Figure 4c). Lesions presented at the other sites were treated non-operatively.

Osteofibrous dysplasia

All cases were treated non operatively after biopsy confirmation.

Fibrous cortical defect and non-ossifying fibroma

Diagnosis was mostly done by X ray and classical CT appearance and in cases where there is a cortical defect, core needle biopsy was done.¹³

Hematopoietic

Eosinophilic granuloma

Diagnosis was confirmed by core needle biopsy and surgical treatment was offered if the lesion met Mirel's criteria.

Follow-up of these tumours like lesions varies from 2 years to 25 years. First review is after 3 months which include clinical examination and repeat X-ray. Further follow up depends on the pathology of the lesion. In latent lesions like fibrocortical defect, they were contacted by phone to make sure that they are symptom free in regards to the lesion. In case of active lesions, they were followed up clinically and radiologically at 6 months, 1 year, 2 year and then biennially thereafter.

RESULTS

Total 136 patients were conforming to the diagnoses during the study period. Four patients were lost on follow up and couldn't be even contacted through mobile. One patient who was initially diagnosed to have aneurysmal bone cyst histologically, was diagnosed to have a malignant lesion on recurrence of the swelling on follow-up. Excluding these 5 patients, we had a total of 131 patients in our study group (Table 1).

Table 1: Classification system for tumour like lesions.⁴⁻⁸

Type of lesion	Subdivision	Number of cases included in our study
Cystic lesions	Simple bone cyst	47
	Aneurysmal bone cyst	31
	Intra osseous ganglion	7
Fibrous lesions	Fibrous dysplasia.	19
	Osteofibrous dysplasia	3
	Fibrous cortical defect nonossifying	10
	Fibroma	6
Hematopoietic	Eosinophilic granuloma	8

Simple bone cyst

Site wise distribution in our series is given in Table 2. Relative distribution of the cases is consistent with available literature.^{9,10}

Proximal humerus

Most of the humeral lesions were treated non-operatively by immobilization in a U slab and arm to chest strapping (Figure 1). Even cases that sustained repeated fractures were treated non-operatively. Two cases were treated by closed titanium nailing, without undertaking any specific

treatment for the lesion. Lesions got healed at the site of fracture and rest of the lesions remained as such. Over the years surrounding cortex got thickened, so that the patient is able to undertake heavy manual labour. Five cases (17.9%) had refracture. This includes the case treated with closed titanium nail. Re fractured cases were treated with further immobilization. In these cases also lesion showed more healing towards the refractured site.

Table 2: Site wise distribution of simple bone cyst.

Proximal humerus	28
Proximal femur	11
Calcaneum	4
Ulna	1
Fibula	1
Radius	2

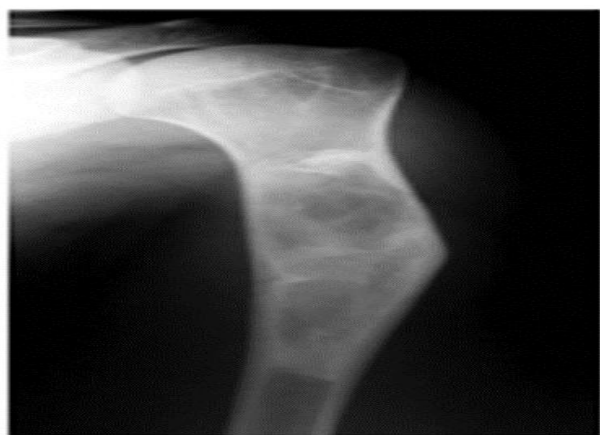

Figure 1: Case of solitary bone cyst treated by immobilization after depomedrol injection on long follow up of 12 years shows thickening of the cortex around the remaining cyst.

Upper femur

Seven out of eleven cases in proximal femur, presented with pathological fracture (Figure 2A). Nine cases of proximal femur were treated by surgery. Four cases of pathological fracture were treated by PFN and one with DHS. In 2 cases we have used fibula K wire composite (Figure 2B). Patients presented without fracture in proximal femur were treated with bone grafting without implant. Free fibula graft was impacted in three cases and iliac crest graft was used in the remaining one. No attempt was done to remove the lesion. One small lesion in neck of femur was treated by depomedrol injection and non-weight bearing.

In cases presented with pathological fracture, fibula K wire composite gave the best results. In the cases treated by proximal femoral nail, one case on follow-up after 2 years showed flattening of the femoral head- suggestive of segmental avascular necrosis, though the patient was asymptomatic. In lesions without pathological fracture,

all the lesions got healed with the use of bone graft alone. Fibula imperceptibly got incorporated (Figure 2C). In the case treated by depomedrol, lesion didn't heal completely. But the surrounding cortex got thickened so as to withstand the additional stresses in that area.

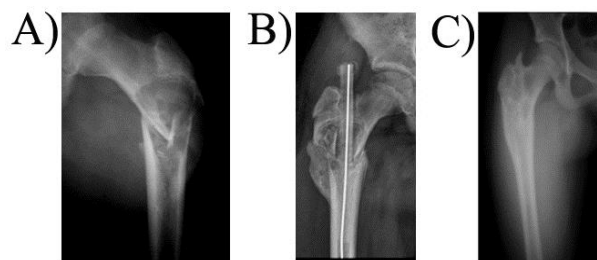


Figure 2: A) Pathological fracture proximal femur caused by simple bone cyst; B) Treated with fibula K-wire composite -3 months follow up; C) Final picture after k wire removal.

Calcaneum

One case of lesion in the calcaneum was treated by curettage and bone grafting, one case was treated by depomedrol injection and the remaining two cases were left untreated. The case treated with bone grafting healed well. Two cases which were left alone, the radiological appearance remained same. But these patients remained asymptomatic during the follow up. One case that was treated by depomedrol injection got infected. This was further treated by curettage and antibiotics based on culture and sensitivity.

One case of lesion in the radius, which was found incidentally, was left untreated after taking biopsy. The second case presented with pathological fracture, and was treated by plaster immobilization. Lesion in the ulna was treated by excision and fibula grafting. In the ulnar lesion, grafted fibula got incorporated. Lesions in the radius including that presented with pathological fracture, which were treated conservatively, got healed eventually. The fibular lesion treated by depomedrol showed complete obliteration of the cyst radiologically.

Aneurysmal bone cyst

Twenty cases were treated surgically till 2010. After the introduction of sclerotherapy treatment for ABC, 11 cases which presented to us between 2011 and 2016 were treated by sclerotherapy with polidocanol (Figure 3).^{11,12} Five/eleven cases required repeated injections. Cases of uncertain diagnosis encountered during this period were continued to be treated by curettage and bone grafting.

Of the 20 operated cases, 4 cases were recurred. One of these recurred cases was a pathological fracture neck of femur treated by excision and hemiarthroplasty initially. They underwent total hip arthroplasty for recurrence from another hospital within a year. In cases (n=11) treated by

sclerotherapy (Figure 3A), there was complete obliteration of cavity in 2 cases (Figure 3B) and partial obliteration in 6 cases. Three cases had no change after second injection during the follow-up period. Even in these cases without radiological changes, there was no progression of the lesion and the patients were asymptomatic.

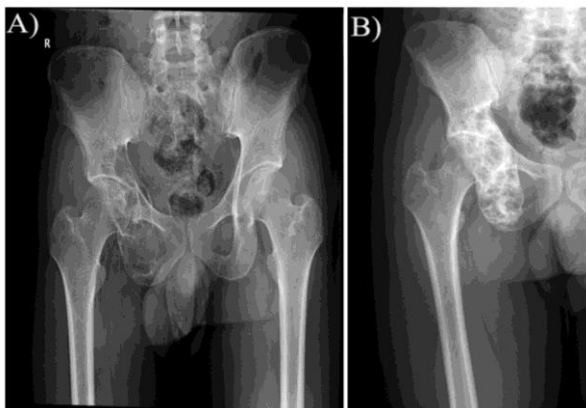


Figure 3: A) ABC of innominate bones around acetabulum; B) Complete obliteration after a single injection of polidocanol at 1 year.

Two cases of partial obliteration by sclerotherapy were cases of recurrence after curettage and bone grafting. Of the 3 cases which showed no change during follow up after repeated injections of polidocanol, 2 cases underwent curettage and bone grafting. Preoperatively it was found that these lesions were less vascular than usual.

Intraosseous ganglion

Four out of seven cases were treated by bone grafting. All these cases were in the lower end of tibia. Two cases diagnosed as intra osseous ganglion, by imaging and was advised curettage. They did not come for surgery. On enquiry they were asymptomatic except for occasional pain which subsided with reduced physical activity for 4 to 5 days. One case in the lower end fibula was associated with thickened peroneal tendon. Intraoperatively mucinous material was obtained from the cavity which was let out. No graft was used.

Fibrous dysplasia

Of the 19 cases, one was a case of polyostotic fibrous dysplasia. On site wise distribution, there were 8 cases of proximal femur, 6 cases of tibia, 4 cases of ribs, 2 cases of ulna and one in fibula.

In five of the seven cases of proximal femoral lesions treated by fibular grafting, fibula gave support to the weak area and lesion did not progress further at follow after three years. There were two cases of recurrences. One was a 6 year old girl and the other was a 9 year old

boy (Figure 4) who had polyostotic variety of the disease. The girl is now walking with a mild limp. The boy underwent plating on proximal femur of both sides. On final follow up he had started walking without support.

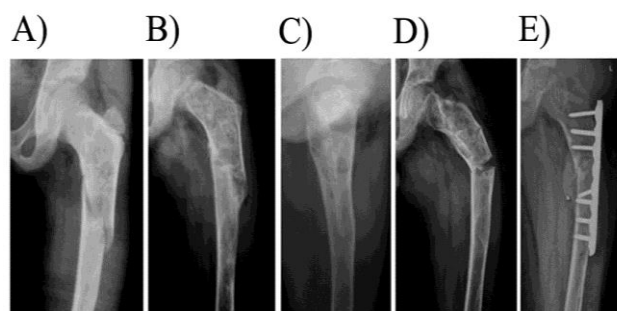


Figure 4: A) Case of polyostotic fibrous dysplasia of a 11 year old boy who presented with pathological fracture of proximal femur; B) Fracture healed on immobilization with hip spica; C) Weakened bone strengthened by intramedullary fibular autograft; D) Refracture after 1 year E) Open reduction and internal fixation of the fracture which eventually went in for union.

In the remaining lesions that were left alone, there was no further progression. Even in cases that presented with deformity there was no significant increase in the deformity during the follow up period. Follow up period extends from 2 yrs to 12 yrs.

Osteofibrous dysplasia

There was one case each in tibia, fibula and ulna. All of them presented with pathological fracture. After biopsy, all lesions were treated by simple immobilization. Lesions partially healed with healing of the fracture. At final follow up there is no further increase in size of lesion and patients were asymptomatic.

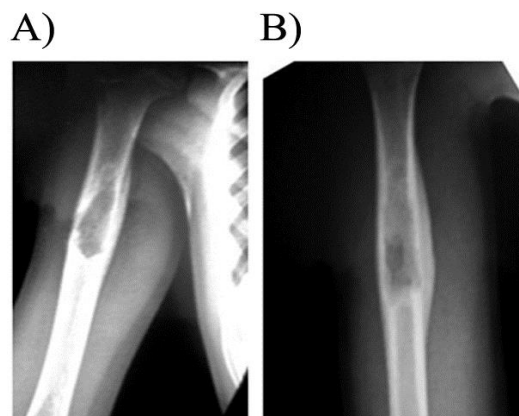


Figure 5: A) Case of lytic lesion in humerus which on biopsy was diagnosed as eosinophilic granuloma and no active intervention was done; B) Follow up after 2 months shows fast healing of the lesion.

Non ossifying fibroma/fibrous cortical defect

All cases were incidental findings and were left alone after imaging/biopsy confirmation. They all remained asymptomatic throughout the follow-up.

Eosinophilic granuloma

Four cases treated with curettage and bone grafting. Remaining four cases were left alone after core needle biopsy. Cases treated by bone grafting healed completely. Cases left alone healed spontaneously to varying extent but remained asymptomatic at final follow up (Figure 5).

DISCUSSION

A number of non-neoplastic lesions of bone resemble a neoplasm. Often the distinction between these tumour like lesions and benign tumours is arbitrary.¹⁴ In the present WHO Classification of bone tumours, there is a group of lesions named as ‘tumors of undefined neoplastic nature’.⁷ In the earlier publication of World Health Organization edited by Schajowicz et al, these lesions were called tumor-like lesions and this term is more popular and well accepted even now.⁸ Tumours like lesions are not neoplasms. Though there are differences of opinion regarding etiology and pathophysiology of these lesions, it is generally accepted to originate from structural changes that had happened either in the intrauterine life (as in fibrous dysplasia) or later during growth period (as in aneurysmal bone cyst).¹⁴

Simple bone cyst

Venous obstruction theory by Cohan regarding simple bone cyst is generally accepted and explains the following aspects.^{15,16}

1) Chemical constituents of the fluid in cysts are similar to serum, 2) Drilling, reaming and fracture helps healing as it opens vascular channels between cyst and the venous system and 3) Cyst fluid is the cause and obstacle to healing. Fracture is the natural way of healing. Healing will be better if there is a repeated fracture. This aspect forms the base of our treatment. Steroid injection is another established method of treatment as also exemplified by our study.^{17,18} Segmental resection and grafting was done in our earlier cases when we didn't practice the concept of tumour like lesions.

Aneurysmal bone cyst

Local post injury alterations in haemodynamics related to venous obstruction or arteriovenous fistulas are important in the pathogenesis of aneurysmal bone cysts, a concept that is supported by angiographic data.^{16,19}

These vascular malformations cause secondary bony changes. This explains the use of sclerosants in the treatment of this condition. Sclerosants, in general, act by direct damage to the endothelial lining, triggering a

coagulation cascade and thrombotic occlusion of blood vessels.¹¹ There are earlier reports of spontaneous remission of ABC in the literature.²⁰ Response to autogenous bone marrow injection is also reported.²¹

As neither curettage nor excision can guarantee lack of recurrence, sclerotherapy has to be considered as the first line of treatment in ABC.

Fibrous dysplasia and osteofibrous dysplasia

The etiology of these disorders has been linked with a mutation in the gene that occurs after fertilization in the somatic cells. The clinical presentation varies depending on where in the cell mass, the mutation is located and the size of the cell mass during embryogenesis when the mutation occurred.²² In the setting of monostotic fibrous dysplasia, the mutated cells are thought to be limited to the affected bone. Competitive growth disadvantage compared with the non mutated cells and increased rates of apoptosis of the mutated cells is responsible for dampening the activity in monostotic fibrous dysplasia with increasing age. For fear of recurrence, cortical grafts are preferred over cancellous grafts due to slower resorption of the former one.²² There was a case report suggesting that graft may serve as a bridge for fibrous dysplasia cells to reach a previously unaffected bone.²³ Progressions of lesion in our cases (Figure 4) validate this hypothesis. At present intramedullary fixation is considered better than bone grafting in actual or impending pathological fractures.^{22,24}

Osteofibrous dysplasia or Kempson-Campanacci lesion is a benign, self limiting lesion that spontaneously regress by puberty.²⁵ Except in the peritrochanteric area, both fibrous dysplasia and osteofibrous dysplasia lesions are better treated nonoperatively including cases of pathological fracture and to accept the deformity and swelling.²² Any surgical intervention is likely to spread the disease process.

Nonossifying fibroma and fibrous cortical defect

These are common lesions. Although these two terms are used interchangeably, it is generally agreed that non ossifying fibroma is more appropriately applied to a larger lesion and fibrous cortical defect to defects confined to cortex.^{4,7} The origin and histogenesis of these lesions are still debated; but an unrecognized, local traumatic insult (or insults) to the periosteum resulting in focal hemorrhage and edema is consistent with both the natural history of fibrous cortical defects and their propensity to occur at osseous sites of muscular attachment.¹⁶ Almost always they are incidental findings and it is a well accepted fact that they require no treatment.²⁴

Eosinophilic granuloma

Proliferation of specific histiocytes (Langerhans cell histiocytes) can manifest in various forms. Localization

to one or a few bones has been known as eosinophilic granuloma. The classical type of eosinophilic granuloma may resolve spontaneously, with no clinical or surgical intervention.⁵ Often a biopsy alone is enough to incite healing.²⁶ This had happened in 3 cases in our series. Cases of eosinophilic granuloma of thoracic spine presenting as vertebra plana usually undergo progressive healing and restoration of vertebral height.²⁷ Indomethacin seems to be effective for treating eosinophilic granuloma of bone in children.²⁸

Tumour like lesions is generally treated aggressively like osteoclastoma if not like osteosarcoma. The author's experience as well as the review of the literature clearly shows that this has to be discouraged. Lesions in the peritrochanteric region pose a high chance for pathological fracture. Mirel had given an additional score for lesions in the peritrochanteric area.²⁹ That is why we had done prophylactic fixation in lesions of upper femur (Figure 2 and 4). Lesions in the peritrochanteric area that remains asymptomatic and radiologically stable, can present with a pathological fracture at a later date, as happened in one of our cases of simple bone cyst located at proximal femur, which presented with pathological fracture at the age of 28. He was asymptomatic till then.

Aneurysmal bone cyst was an exception to the general statement till recently. Success of treatment of aneurysmal bone cyst with percutaneous sclerotherapy using polidocanol has made its treatment of as simple as other tumour like lesions.

CONCLUSION

As tumors like lesions of the bone are not neoplasms, they need not be treated as aggressively as other bone tumours. Most of the cases can be left alone. They need to be treated only if they are symptomatic or likely to produce a pathological fracture. Even in such situations, one need not take a radical approach.

ACKNOWLEDGEMENTS

The authors gratefully acknowledge the valuable help of Dr. Ajith TA, Professor of Biochemistry, Department of Biochemistry, Amala Institute of Medical Sciences during the preparation of the manuscript.

Funding: No funding sources

Conflict of interest: None declared

Ethical approval: The study was approved by the institutional ethics committee

REFERENCES

- Mohan H. Text book of Pathology. 7th edition. 2015: 828.
- Szendrői M, Sim FH. Color Atlas of Clinical Orthopedics. 2009: 209-229.
- Enneking WF. Musculoskeletal Tumor Surgery. Vol. 1. New York, Churchill Livingstone: 1983; 87-89.
- Motamedi K, Seeger LL. Benign Bone Tumors Radiol Clin N Am. 2011;49:1115-34.
- Kim SH, Smith SE, Mulligan ME. Hematopoietic Tumors and Metastases Involving Bone Radiol. Clin N Am. 2011;49:1163-83.
- Unni KK, Carrie Y. Inwards Dahlin's Bone Tumors. 2010: 305-347.
- Christopher F, Bridge JA, Hogendoorn PCW, Fredrik M. WHO classification of soft tissue and bone. 4th edn. 2013: 240-301
- Schajowicz F. Histological typing of bone tumours. World Health Organization; International histological classification of tumours. Second edition. 1993: 36-42.
- Wold LE, Unni KK. Atlas of Orthopedic Pathology. Third edition. 2008: 460-462.
- Puri A, Agarwal M, Current concepts in bone and soft tissue tumors; 2007: 93-106.
- Rastogi S, Varshney MK, Trikha V, Khan SA, Choudhury B, Safaya R. Department of Orthopaedics, All India Institute of Medical Sciences, New Delhi. Treatment of aneurysmal bone cysts with percutaneous sclerotherapy using polidocanol. A review of 72 cases with long-term follow-up. J Bone Joint Surg Br. 2006;88:1212-6.
- Varshney MK, Rastogi S, Khan SA, Trikha V. Is sclerotherapy better than intralesional excision for treating aneurysmal bone cysts? Clin Orthop Related Res. 2010;468:1649-59.
- Balach T, Stacy GS, Peabody TD. The clinical evaluation of bone tumors. Radiol Clin N Am. 2011;4:1085.
- Bhardwaj JR, Deb P. Boyd's Text Book of Pathology. 10th Edition. 2013: 1676.
- Jonathan C. Etiology of Simple Bone Cyst. J Bone Joint Surg. 1970;52:1493-97.
- Resnick D, Kransdorf MJ. Bone and Joint Imaging. Third Edition. 2005: 2408-2593.
- Chang CH, Stanton RP, Glutting J. Unicameral bone cysts treated by injection of bone marrow or methylprednisolone. Bone Joint J. 2002;84:407-12.
- Scaglietti O, Marchetti PG, Bartolozzi P. The effects of methylprednisolone acetate in the treatment of bone cysts. Results of three years follow-up. Bone Joint J. 1979;61:200-4.
- Vergel De Dios AM, Bond JR, Shives TC, McLeod RA, Unni KK. Aneurysmal bone cyst clinicopathological study of 238 cases. Cancer. 1992;69:2921-31.
- McQueen M, Chalmers GDJ. Spontaneous healing of aneurysmal bone cyst report of two cases. JBJS. 1985;310:2.
- Donati D, Frisoni T, Dozza B, Ugo HD, Giannini AS. Advance in the treatment of aneurysmal bone cyst of the sacrum. Skeletal Radiol. 2011;40:1461-6.

22. Dicaprio M, Enneking W. Current concept review of Fibrous Dysplasia pathophysiology evolution and treatment. *JBJS.* 2005;87:1848-63.
23. Meredith DS, Healey JH. Twenty-Year Follow-up of Monostotic Fibrous Dysplasia of the Second Cervical Vertebra A Case Report and Review of the Literature Investigation performed at Memorial Sloan-Kettering Cancer Center, New York, NY. *Bone Joint Surg Am.* 2011;93:1-7.
24. Robert K. Heck Jr., Patrick C. Toy. Benign bone tumours and non neoplastic conditions simulating bone tumours. *Campbell's Operative Orthopaedics* 12th edition. Elsevier Mosby.
25. Panda P, Gulia A. Osteofibrous Dysplasia – an update. *J Bone Soft Tissue Tumors.* 2016;2:23-5.
26. Bonetumor.org. Eosinophilic granuloma. Available at: <http://www.bonetumor.org/tumors-unknown-type/eosinophilic-granuloma>. Accessed on 3 July 2017.
27. Gasbarrini A, Cappuccio M, Donthineni R, Bandiera S, Boriani S. Management of benign tumors of the mobile spine. *Orthop Clin North Am.* 2009;40:9-19,
28. Han I. Management of Eosinophilic Granuloma Occurring in the Appendicular Skeleton in Children *Clin Orthop Surg.* 2009;1:63–7.
29. Mirels H. Metastatic disease in long bones: a proposed scoring system for diagnosing impending pathologic fractures. *Clin Orthop Relat Res.* 1989;249:256–64.

Cite this article as: Dominic KP, Dijoe D, Manathara LT. Tumour like lesions and their management: a retrospective study. *Int J Res Orthop* 2018;4:159-65.