

Original Research Article

Management of intra-articular fractures of distal end radius in adults

Satish R. Gawali^{1*}, Hardikar S.M.², S. Prakash², Sunil Nadkarni²

¹Assistant Professor, Department of Orthopedics, Government Medical College and Hospital, Latur, Maharashtra, India

²Department of Orthopedics, Hardikar Hospital Pune, Maharashtra, India

Received: 25 June 2016

Revised: 01 July 2016

Accepted: 06 July 2016

***Correspondence:**

Dr. Satish. R. Gawali,

E-mail: satishgawali61@gmail.com

Copyright: © the author(s), publisher and licensee Medip Academy. This is an open-access article distributed under the terms of the Creative Commons Attribution Non-Commercial License, which permits unrestricted non-commercial use, distribution, and reproduction in any medium, provided the original work is properly cited.

ABSTRACT

Background: Incidence of intra articular fracture L/3rd radius is significantly on rise due to high velocity accidents in young and adults. Painless wrist function is of vital importance for functioning of upper extremity in almost all activities of daily living and precise function of hand. Intra articular fracture of L/3rd radius has generally gross comminution and so also small articular fragments. Orthopaedic community differ about specific implants to fix this complex injury. The present study was undertaken to know efficacy of different modalities of treatment for different fracture pattern. Comminuted intra articular fracture geometry varies widely, to fix these small fragments to achieve stable anatomical reduction is a challenging task.

Methods: It is a combined i.e. retrospective and prospective study conducted at Hardikar Hospital, Pune, India from 1999 to December 2000. Patients of intra-articular fracture of distal end radius by different modes of treatment are included in the study. 1 patient with unilateral fracture was lost for follow-up. Thus 50 fractures, in 49 patients. were included in study. Clinico-radiological assessment was carried out by Lidstrom's (1959) criteria.

Results: Satisfactory early functional end results with plaster treatment is 72.2% whereas with other modality of treatment it rises to 87.5%, indicating superiority of other modalities of treatment as far as early functional end results are concerned.

Conclusions: Manipulation and plaster cast method continues to be the treatment of choice in the stable intra articular distal radial fractures. Hence there is a need for a "differentiated therapy for distal radial fractures". The treatment plan for patients must be based not only on fracture pattern identified on plain radiographs but also on factors such as bone quality, bone comminution, energy of injury and associated soft tissue damage. Additional factors to be considered in individual patient are-life style associated medical conditions and compliance.

Keywords: Distal end radius, K-wire, External fixator

INTRODUCTION

Distal radial fractures are one of the commonest fracture occurring in skeleton. Although, it was described 176 years back, controversies still exist regarding best mode of treatment, immobilization and prediction of results due

to influence of various intrinsic and extrinsic factors, affecting final outcome. Thousands of articles have been published to understand the patho-mechanics and best modality of treatment after Sir Abraham Colles described a very common fracture of distal end radius in 1814.¹ Many consider that the anatomical position did not really matter and left alone the patient obtained some function.⁷

Although Colles was evidently satisfied with the results of this treatment, review of literature shows the rather high incidence of unsatisfactory results in the treatment of these fractures in a plaster cast alone. Deformities in up to 60% and unsatisfactory functional results in up to 32% of the patients are seen.^{6,9,10} Most cases are still treated with closed reduction and plaster cast in spite of growing concern with poor results in many cases. Many authors have now shown that anatomical position does matter and as Bonnin put it "for perfect function, perfect reduction is essential".^{5,7} The answer to the problems of functional impairment and cosmetic deformity after this fracture remains elusive. In an attempt towards achieving better functional results, many other modalities of treatment have been described for this fracture.

Consistently, the results are unsatisfactory when intra articular and unstable fractures are treated by plaster cast alone. The range of intra-articular fracture extends from simple undisplaced intra-articular fracture to fracture with severe comminution and crushing of articular surface and associated soft tissue injury.⁵⁻⁷

The intra articular fracture of distal end radius still remains a difficult problem to manage satisfactorily aiming to obtain excellent clinico-radiological results consistently. Different modes of treatment are clearly required for injuries of differing severity.^{4,11,12}

Purpose of study

- To study mechanism of injury & displacement in various types of intra-articular fracture of distal end radius.
- To select different modes of management for intra-articular fracture distal end radius (according to symposium panel of Universal classification in 1990).
- To evaluate functional & anatomical end results and complications of various modes of treatment.

METHODS

Combined i.e. retrospective and prospective study was done.

Details of material and experimental design

For retrospective study, 30 patients of intra-articular fracture of distal end radius who were treated at Hardikar Hospital, Pune, India by different modes of treatment during the year 1999 were considered for study.

For prospective study, 20 patients with recent intra-articular fractures of distal end radius who attended the OPD from January 2000 to December 2000 were included in study.¹ Patient with unilateral fracture was lost for follow-up.

Thus 50 fractures, in 49 patients were included in study.

Inclusion criteria

- Both males and females are included.
- Above 18 years of age.
- Fracture distal end radius with soft tissue injuries with fracture ulnar styloid or traumatic carpal instability were included.
- Duration - Recent intra-articular fractures of distal end radius at the time of presentation were included

Exclusion criteria

- Cases with failure of previous modality of treatment such as implant failure, infection and other complications were excluded.
- Pathological fractures secondary to osteomyelitis, tumor etc. were excluded.

In undisplaced fracture, only below elbow plaster cast was given with the forearm pronated and the wrist flexed and ulnar deviated 5°. In 5 compound fractures debridement of wound was done and external fixator applied. All the other displaced fractures were subjected to any one of the following modes of treatment according to treatment algorithm of symposium Panel of universal classification (1990):

- Closed reduction and a plaster cast
- Closed reduction and percutaneous K wires fixation and cast.
- Closed reduction and external fixation.
- Closed reduction and percutaneous K wires and Ext. fixator
- Open reduction and internal fixation (ORIF) with T plate and screws
- Ext. fixator and ORIF

Anaesthesia

General anaesthesia or regional anaesthesia (Bier's Brachial or Scapular block)

Technique

Closed reduction and cast

Manipulative reduction done as per standard method and cast was applied from the metacarpal heads to above the elbow in supination and 5°-10° palmar flexion and ulnar deviation each. The third pressure point is the upper forearm on the dorsal aspect, to obtain a 'three point action' in the plaster.

Closed reduction and percutaneous 'K' wire fixation-after manipulative

Reduction, under aseptic precautions 2 K wires (7/64") were passed-one through the radial styloid processes obliquely upwards towards the opposite cortex. The other

pin was passed parallel to and above it or transversely depending on the fracture comminution.

Closed reduction and external fixation

Under aseptic precautions 2 schanz pins (2.5 mm) were passed through the 2nd metacarpal after predrilling. 2 more schanz pins (3.5 mm) were passed proximal to the fracture in proximal radius, about 10 cm from the wrist joint. Sensory branch of radial nerve was identified and protected. The fracture was then reduced and the fixator locked.

Closed reduction and percutaneous K wires and Ext. fixator

Firstly, closed reduction and external fixator was applied as mentioned in technique 'c'. Then 2 'K' wires were passed from radial styloid in addition for better stability of fragments.

Open reduction and internal fixation (ORIF) with 'T' plate and screws

An incision was made on distal forearm on the tendon of flexor carpi radialis, by standard approach, after reduction of fracture, a 'T' plate (for comminuted and volar displaced fractures) or ellis buttress plate (for volar lip articular fractures) was used to fix the fracture with screws.

External fixator and ORIF

On certain occasion due to severe comminution and the fracture fragments being small it was not possible to internally fix all of them. Therefore to maintain reduction and stability an external fixator was applied first. Then internal fixation was done as described above. Acceptable position-restoration of radial length and volar angle.

Whenever severe oedema was present, reduction or surgery was delayed for a few days and a plaster slab was applied. 2 patients who had persistent oedema showed poor results. Check radiographs were done immediately after reduction, at one and two weeks after reduction. If the initial reduction was not satisfactory or if there was significant loss of reduction, re-manipulation under anaesthesia was done.

The follow up was done as per standard protocol.

Follow up protocol

- 1st follow up after 15 days. Check X-ray in cast.
- 2nd follow up 1 month post trauma. Check X-ray AE cast converted to BE cast.
- 3rd follow up-
 - a) At 6 weeks post trauma, if Ext. fixator applied - fixator

removed, and BE cast for 2 - 4 weeks

- b) At 8 weeks post trauma, for all other cases without Ext.

- fixator - Remove cast, check X-ray,
- Note the signs of union.
- If no, continue BE cast for 2 weeks.
- If fracture united start wrist and finger movements.

Clinico-radiological assessment

Lidstrom's (1959) criteria for Anatomical and functional end results was used for assessment.⁹⁻¹¹

RESULTS

The observations of 30 retrospective fractures and 20 fractures in 19 patients in prospective study are pooled together as the patients were comparable with respect to following demographic clinico-radiological and surgical intervention techniques. Out of 51 fractures in 50 patient, 1 patient with unilateral fracture was lost for follow-up. Thus 50 fractures were included in the study.

Age and sex distribution

Total numbers of males are 35 and females 14 so total 49 patients and 1 male has got Bilateral fracture so total 50 fracture were studied.) High incidence of intra articular fracture in male before the age of 45 years, probably due to road traffic accident. In females after age of 45 years incidence markedly increased due to post menopausal osteoporosis.

Type of violence

The predominant mechanism of injury was road traffic accident followed by fall on outstretched hand.

Displacement of fracture

3 cases had multiple fractures (poly-trauma). In 26% cases, intra articular fracture distal end radius is associated with other fractures 6% of cases among all, had Poly-trauma.

In all these case, group average is taken. It is very clear that volar angle V is better maintained with other modalities of treatment than conventional plaster cast method. In severe injury leading to Type VII and VIII fracture, volar angle is not well maintained, irrespective of modality of treatment, due to fracture comminution.

Loss of radial length is more conventional plaster cast method as compare to other modalities of treatment.

Table 1: Frykman's grade of fracture and treatment protocol.

Treatment protocol/#Gr.	III	IV	V	VI	VII	VIII	Total	
A*	In situ cast	2	1	2	0	1	0	6
	CR and Cast	1	2	1	1	3	4	12
B**	CR and K wires	1	1	0	1	1	2	6
	CR, K wires & Ex. Fix	0	1	0	0	2	4	7
	ORIF with plate	1	1	0	0	4	5	11
Total	6	9	3	2	12	18	50	

*A- conventional plaster cast method. **B- Other modalities of treatment.

Table 2: Volar (V) angle (after 12 weeks) in degrees (normal angle is 11°-12°).

	Frykmans' Fracture Grade					
	GR III	GR IV	GR V	GRVI	GR VII	GR VIII
A*	+ 6	+ 7	+ 6	+ 5	0	-2
B**	+ 10	+ 9	No Case	+ 8	+ 4	+ 1

* A - conventional plaster cast method + = Volar , ** B - Other modalities of treatment= Dorsal

Table 3: Loss of radial length in mm (after 12 weeks).

	Frykman's Fracture Grade					
	Gr III	Gr IV	Gr V	Gr VI	Gr VII	Gr VIII
* A	6	5	5	6	7	8
** B	1	1	No case	1 1.5	2	3

* A - conventional plaster cast method, ** B - Other modalities of treatment

Table 4: Loss of radial angle (in degrees) (after 12 weeks).

	Frykman's Fracture Grade					
	Gr III	Gr IV	Gr V	Gr VI	Gr VII	Gr VIII
* A	5	4	4	5	7	5
**B	1	1	No case	1.5	2	2.5

* A - conventional plaster cast method, ** B - Other modalities of treatment

Radial angle and hence the radial length is better maintained with other modalities of treatment than conventional plaster cast method.

Redisplacement of fracture

Redisplacement occurred up to 27.7% of cases treated with conventional plaster cast method and 6.2% with other modalities of treatment.

Out of 7 displacement, 6 occurred in 1st week and 1 in 2nd week after reduction. In all these cases re reduction was done under GA.

Movements

Restriction of movement is more with conventional plaster cast method mainly supination.

Table 5: Complications.

	Conventional plaster cast method	Other modalities
Malunion, (deformity)	5 (27.7%)	2 (6.2%)
Residual wrist pain	6 (33%)	3 (9%)
Displacement	5 (27.7%)	2 (6.2%)
Stiffness	6 (33%)	4 (12.5%)
Weak hand grip	4 (22.2%)	2(6.2%)
Sudeck's osteo dystrophy	2(11%)	1 (3.1%)
Compressive neuropathy (Median nerve)	1 (5.5%)	0
Tendon rupture	0	dI
Wrist arthritis	3 (16.6)	1 (3.1%)
Pin site infection	-	1
Pin loosening/breakage	-	2
Screw loosening	-	0

Criteria for unstable fracture.

- Severe comminution
- Dorsal angulation > 20° and radial shortening 10 mm or more. Criteria for secondary instability or displacement.

- Loss of angulation > 10° and radial shortening 5 mm or more.

Table 6: Functional end results.

	Plaster cast method	Other modalities
Satisfactory		
Excellent	5 (27.7%)	12 (37.5%)
Good	8(44.4%)	16(50%)
Unsatisfactory		
Fair	2(11.1%)	3 (9.3%)
Poor	3(16.6%)	1(3.2%)

Table 7: Comparison of functional end results (with standard series) using McBride system.

End Results	Gartland and Werley	Dowling and Sawyer	Cole and Obltez	Jenkin etal	Present series	
					*P	**O
Satisfactory	69%	84%	94%	93%	72%	87.5%
Unsatisfactory	31%	16%	6%	7%	28%	12.5%

* P = Conventional plaster cast method, ** O = Other modalities of treatment

Table 8: Relationship between functional and anatomical end results.

Anatomical end results								Total
I	II		III		IV			
C	O	C	O	C	O	C	O	
5	11	7	17	2	2	4	2	50
Functional end results								Total
Excellent	Good		Fair		Poor			
C	O	C	O	C	O	C	O	
5	12	8	16	2	3	3	1	50

C = plaster cast method O = Other modalities of treatment.

The results of present study, compare favourable with, those of the Gartland's and Werley series (treated by plaster cast method) and those with, Dowling and Sawyer study, with other modality of treatment.

Table 8 shows the relation present between the early functional end results and anatomical end results. We should aim for good anatomical reduction to get good functional results in these fractures. In one case, we had achieved excellent functional end result despite of poor anatomical end result.

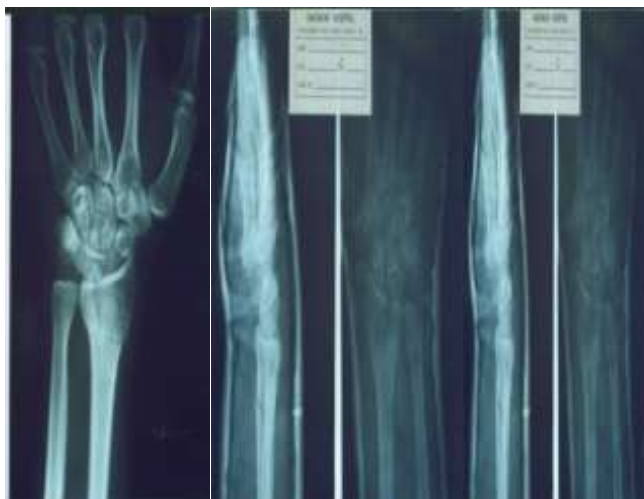

Figure 1: Undisplaced intra articular fracture treated with in-situ cast.

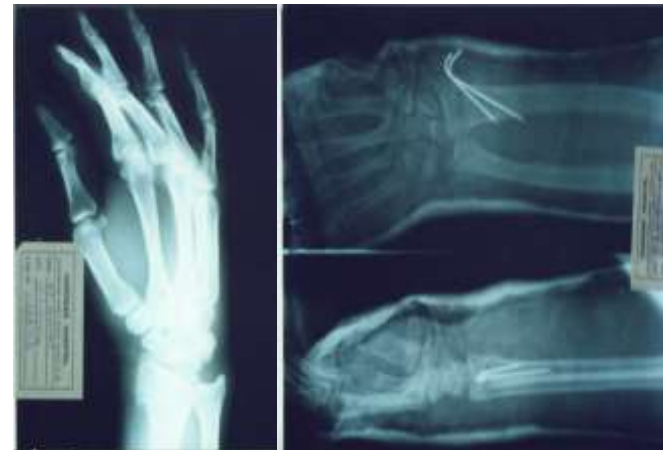

Figure 2: Intra-articular fracture treated with K-wires and cast.

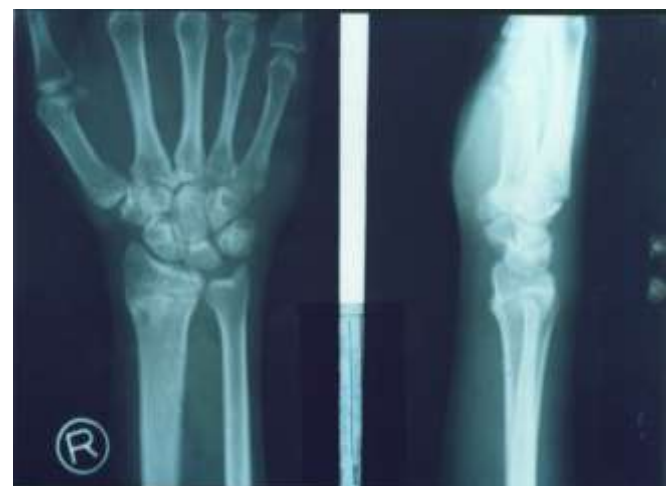

Figure3: Final X-ray-excellent anatomical union.

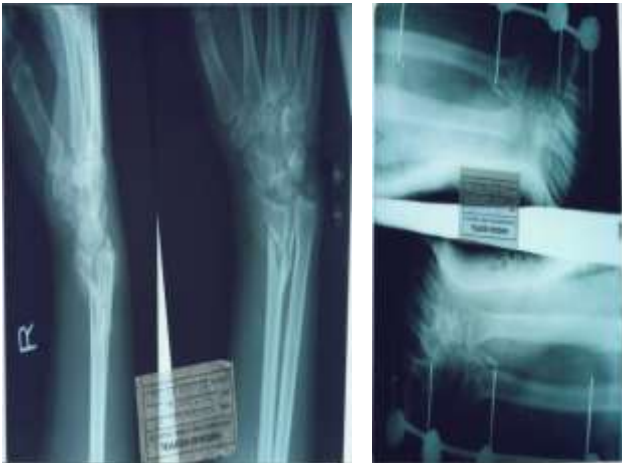

Figure 4: Unstable comminuted fracture treated with Ex-fix and cast.

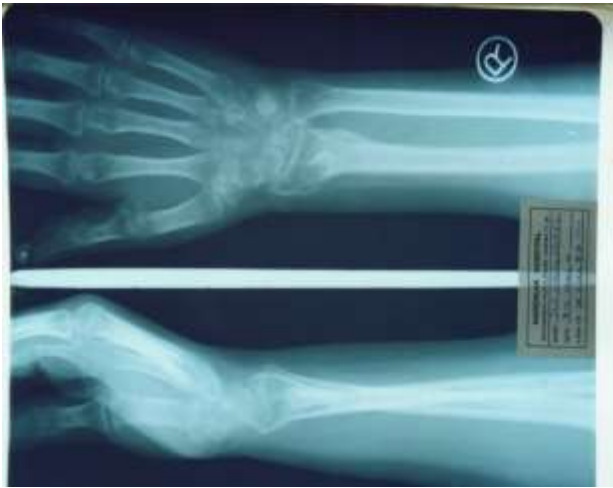

Figure 5: Final X-ray (union).

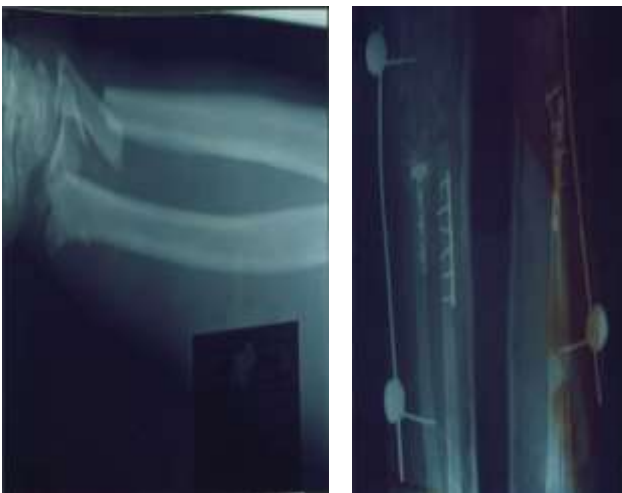

Figure 6: Comminuted fracture treated with plating and Ex-fix.

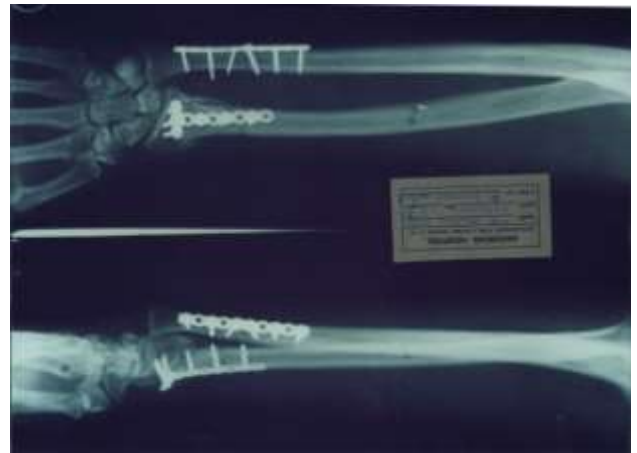

Figure 7: Final X ray -union in good position.

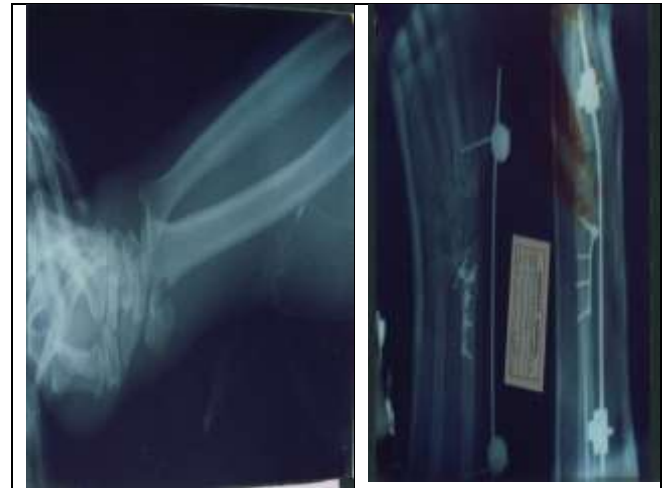

Figure 8: Unstable intra articular fracture treated with plating and Ex-Fix.

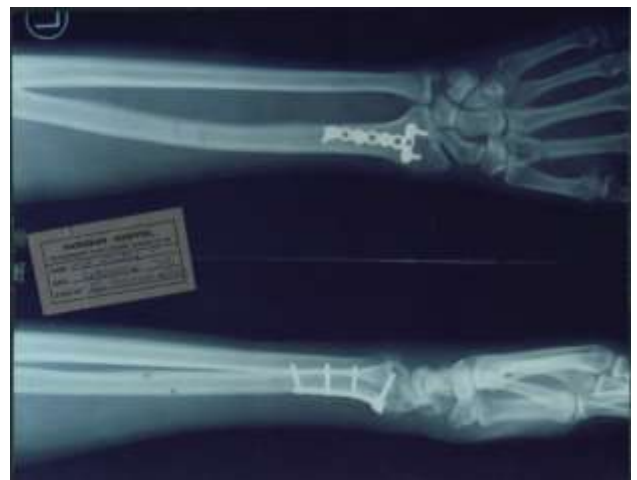

Figure 9: Final X-ray (union in good position).

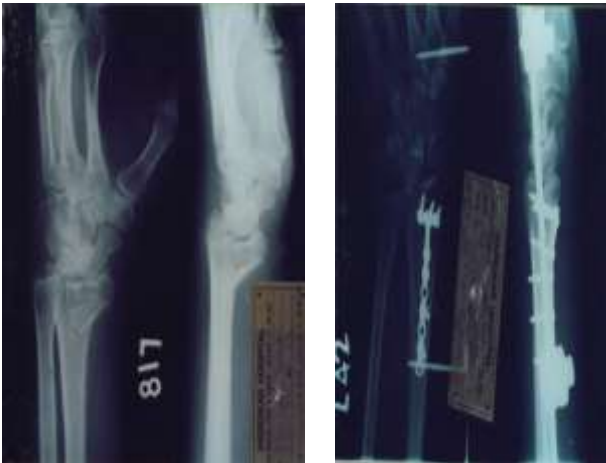


Figure 10: Die-punch fracture treated with Ex fix and plating.

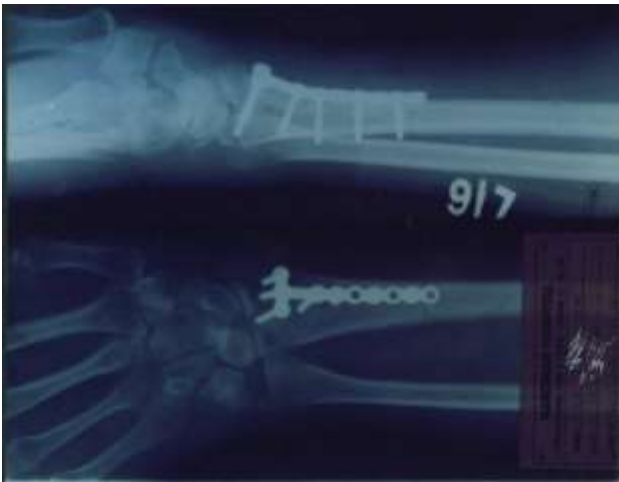


Figure 11: Final X-ray (fracture union).

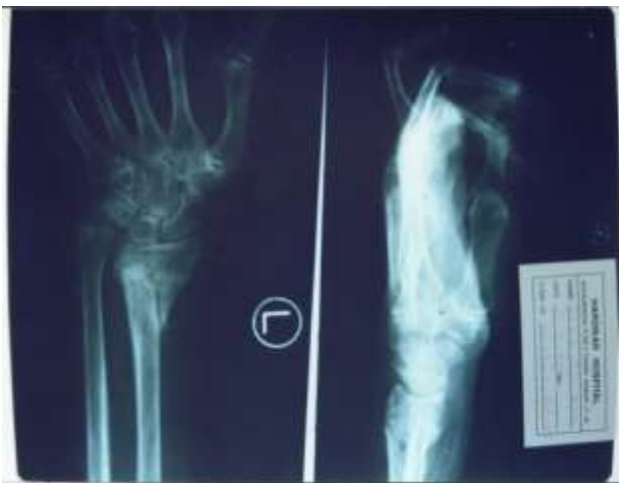

Figure 12: Complications (malunion).



Figure 13: Clinical results-bilateral distal intra articular radius fracture.

DISCUSSION

In present study, the Frykman's classification have used, and retrospectively and prospectively evaluated the results, following treatment of those fractures by different methods.^{4,9,11}

In the present series, there were more males. In the study by Linden WV et al the number of females outnumbered males. After the age of 45 years however, the fracture was common in females. This could be attributed, to post-menopausal osteoporosis.⁸

Distal radial fragment pins were used because of comminution. It has been shown that pins in the distal radius are not stable and need additional external support. Hence pins were used in the shaft of 2nd metacarpal. Good results have been reported with the Hoffman system. We have no experience of this system and are satisfied with the results of Aesculap fixator.²

Percutaneous 'K' wire fixation was done in 6 patients however in one patient with persistent oedema requiring 3 days of elevation, result was not satisfactory. It was found that this method to be very effective if the 'K1 wire pierces the opposite cortex after entering through the radial styloid.

Internal fixation with a T or Ellis plate was under taken in 11 cases. Perfect anatomical reduction was possible in all these cases. Cancellous screw (small size) in inter-fragmentary mode was used in addition for one case only. Contouring of plate was necessary in each case. Ellis buttress plate was used only in volar articular lip fractures. The average operating time was 30 minutes. Dorsal plating for dorsal lip fracture has been described. We have no experience with it.

Barton's fracture (articular lip fractures) is intrinsically unstable. If either the volar or dorsal lip of the radius is fractured and displaced, the entire carpus becomes unstable and dislocates. With a dorsal lip fracture, instability is greater in palmar flexion, for in this position the compressive forces are principally upon the dorsum of the distal radius. Similarly, the volar lip fracture is most unstable in dorsiflexion of wrist. But closed reduction of a volar lip fracture requires wrist dorsiflexion so that the volar radio-carpal ligaments are made taut and pull the fragment distally. In this precise position, compressive forces tend to dislocate it. Similarly in dorsal lip fracture, closed reduction is done by palmar flexion of wrist which tends to dislocate the fracture.¹⁰⁻¹² Thus there is an inherent paradox in this treatment. Barton's frustration in treating these injuries has been shared by many surgeons. The study experience the same. In 3 patients whose volar barton fracture was treated with closed reduction and percutaneous 'K' wires and plaster cast, 2 re-dislocated.

As the articular lip fractures are intrinsically unstable and malunion of these intra articular fractures is disabling, it was strongly felt that open reduction and rigid internal fixation will solve the paradox of Barton's fracture.

Analyzing the functional and anatomical end results we have found that for the less severe fracture type (III to VI) plaster cast method gives satisfactory results in a high percentage of cases.^{4,11} But in the cases of more severe fracture types, treatment methods other than the plaster cast give highly satisfactory results. Stability of the fracture achieved after initial treatment has an important bearing on the end results.

CONCLUSION

- Radiological classification of distal radial fractures before reduction is essential to decide the correct mode of treatment. Frykman's classification which considers intra-articular extension of fracture is useful in treatment of these fractures. Identification of 'die-punch' fracture is important since they are irreducible by close methods.
- Good anatomical restoration results in good functional end result whereas very poor anatomical restoration is associated with poor functional end results. So functional end results related more to quality of anatomic reduction and stability rather than method of immobilization.
- Outcome was better in younger patients.
- The plaster cast method produced unsatisfactory results in unstable intra articular distal radial fractures.
- Many alternative methods (e.g. external fixator, ORIF, K wires) achieve excellent anatomical and functional end results in unstable fractures. They are effective and are associated with few complications. Success rate of these methods of treatment was (87.5%).
- Manipulation and plaster cast method continues to be the treatment of choice in the stable intra articular distal radial fractures. Hence there is a need for a "differentiated therapy for distal radial fractures"
- Functional outcome after external fixation proved excellent with little residual loss of mobility (correlates with Edward's recent study series)
- The treatment plan for patients must be based not only on fracture pattern identified on plain radiographs but also on factors such as bone quality, bone comminution, energy of injury and associated soft tissue damage. Additional factors to be considered in individual patient are - life style, associated medical conditions and compliance.

ACKNOWLEDGEMENTS

The authors are very grateful to all patients who consented for this study without which the efforts were futile. The study is sincere attempt to treat the patients with minimal invasive methodology and desire to get excellent functional outcome in tertiary care hospital, following strict orthopaedic principles. They also acknowledge all para-clinical staff, concerned human efforts towards patient care in this endeavour.

Funding: No funding sources

Conflict of interest: None declared

Ethical approval: Not required

REFERENCES

1. Cooney WP, Linscheid RL, Dobyns JH. External pin fixation for unstable Colles' fractures. *J Bone Joint Surg Am.* 1979;61(6):840-5.
2. Trumble TE, Schmitt SR, Vedder NB. Factors affecting functional outcome of displaced intra-articular distal radius fractures. *J Hand Surg Am.* 1994;19(2):325-40.
3. Wolfe SW, Pike L, Slade JF, Katz LD. Augmentation of distal radius fracture fixation with coralline hydroxyapatite bone graft substitute. *J Hand Surg Am.* 1999;24(4):816-27.
4. Muller M, Nazarian S, Koch P, Schatzker J. The comprehensive classification of fractures of long bones. Berlin, Germany: Springer-Verlag; 1990:43-44.
5. Castaing J. Recent fractures of the lower extremity of the radius in adults. *Rev Chir Orthop Repar Appar Mot.* 1964;50:581-696.
6. Mackenney PJ, Mcqueen MM, Elton R. Prediction of instability in distal radial fractures. *J Bone Joint Surg Am.* 2006;88(9):1944-51.
7. Mcqueen M, Caspers J. Colles fracture: does the anatomical result affect the final function? *J Bone Joint Surg Br.* 1988;70(4):649-51.
8. Cummings SR, Black DM, Nevitt MC. Appendicular bone density and age predict hip fracture in women. The study of osteoporotic fractures research group. *J Am Med Asso.* 1990;263(5):665-8.
9. Frykman G. Fracture of the distal radius including sequelae shoulder hand finger syndrome, disturbance in the distal radio ulnar joint and impairment of nerve function. a clinical and experimental study. *Acta Orthop Scand.* 1967;108:143-53.
10. Melone CP. Articular fractures of the distal radius. *Orthop Clin North Am.* 1984;15(2):217-36.
11. Jupiter JB, Fernandez DL. Comparative classification for fractures of the distal end of the radius. *J Hand Surg Am.* 1997;22(4):563-71.
12. Jupiter JB. Complex articular fractures of the distal radius: classification and management. *J Am Acad Orthop Surg.* 1997;5(3):119-29.

Cite this article as: Gawali SR, Hardikar SM, Prakash S, Nadkarni S. Management of intra-articular fractures of distal end radius in adults. *Int J Res Orthop* 2016;2:220-8.