

## Original Research Article

# Treatment of proximal humerus fracture using proximal humerus locking plating

Niranjan D. Tadvi\*, Rajesh N. Deveshwar, Yogesh C. Patel

Department of Orthopaedics, Government Medical College and Sir. T. Hospital, Bhavnagar, Gujarat, India

**Received:** 01 June 2017

**Accepted:** 20 June 2017

**\*Correspondence:**

Dr. Niranjan D. Tadvi,

E-mail: [dr.niranjantadvi@gmail.com](mailto:dr.niranjantadvi@gmail.com)

**Copyright:** © the author(s), publisher and licensee Medip Academy. This is an open-access article distributed under the terms of the Creative Commons Attribution Non-Commercial License, which permits unrestricted non-commercial use, distribution, and reproduction in any medium, provided the original work is properly cited.

### ABSTRACT

**Background:** Proximal humerus fractures are the most common upper extremity fractures in older patients. The aim of the present study was to evaluate the functional outcome and complications of proximal humeral locking plate used for healing proximal humerus fractures.

**Methods:** This prospective study was conducted at the department of Orthopaedics, Sir T. Hospital, Bhavnagar, from June 2008 to March 2010, with 20 patients who suffered with complex proximal humerus fractures and underwent surgical treatment with proximal humerus locking plates. Functional outcome was assessed at the final follow up by using Constant Murley score.

**Results:** The mean age of the patients was 52 years. Male: female ratio was 1.5: 2. The most common mode of injury is low velocity trauma i.e. fall while walking or fall in bathroom seen in 13 patients. Average time for clinical union was 60 days, while average time for radiological union is 90 days taken in the study. Postoperative complications were seen in 2 patients. Delayed complications were seen in 10 cases. No patients had shown implant related complications. At the final follow up according to Constant Murley score, 36% patients had shown excellent results, 53% patients had shown good results and poor results were seen in 11% of cases.

**Conclusions:** Our results show that good to excellent outcome can be achieved in treating proximal humerus fractures using locking plates in elderly patients. Early mobilization of the shoulder can be achieved without compromising fracture union.

**Keywords:** Proximal humerus fracture, Locking plates, Constant-Murley score

### INTRODUCTION

Proximal humerus fractures represent one of the most common fractures of upper limb in the elderly. They account for 10% of all fractures in patients over the age of 65 years and are the third most common fracture in the elderly. Seventy-five percent of these fractures occur in patients >60 years of age.<sup>1-3</sup> The management of these fractures can be a significant challenge especially in the presence of osteoporosis and multiple fracture segments. Treatment options include conservative therapy, fixation, and arthroplasty.<sup>4-6</sup>

In general, displaced two, three, and selected four part fractures are treated by internal fixation. In three and four part proximal humerus fractures, fixation and arthroplasty are superior to conservative treatment.<sup>7</sup> Fixation is the best option for preserving bone alignment, joint surface congruity, humeral head vascularity and stability to allow early mobilization.

The option of locking plate technology has become a growing trend for the treatment of proximal humerus fractures. The ability of screws to lock to a plate gives angular stability to the construct and maintain

postoperative reduction during early functional rehabilitation.<sup>8</sup>

Locking plates minimized the peak stress at the bone implant interface making them better suited for osteoporotic bone as they had less implant loosening and migration. In regards to humeral head vascularity, locking plates screws do not compress the plate against the bone. Danger of a high compressive force on bone by showing that plate bone contact disturbed periosteal blood circulation. This issue can only be avoided when stabilization requires no frictional forces between the implant and fracture fragments. Locking plates avoid this problem by interlocking the screw head to the plate.<sup>9</sup> In doing so, the plate now acts as a force carrier. In conventional plating, the plate and bone act as a force carrier, which is accomplished by friction between plate and bone.

The present study was aimed to evaluate results with respect to clinical and radiological union of the fracture, complications and ambulatory status of the patients assessed by follow up X-rays and movements.

## METHODS

This was a prospective study conducted by the department of Orthopaedics, Sir. T. Hospital, Bhavnagar, from June 2008 to March 2010, with 20 patients who suffered with complex proximal humerus fractures and underwent surgical treatment with proximal humerus locking plates.

This study was approved by the Institutional ethics committee and informed consent was taken from all the patients. After admission into the hospital complete history of the patient was noted in a proforma. General and local examination was done. Primary treatment was given with analgesics to reduce the pain. Cardiovascular and pulmonary functional assessment was done. Prophylactic treatment was given for tetanus. Fractures were classified according to AO classification.<sup>10</sup>

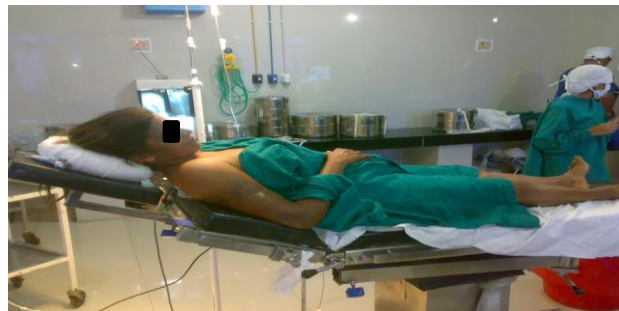### Operative procedure

The patients received prophylactic antibiotics 2 hours before surgery. Patients were given general anaesthesia by brachial plexus block technique. Patient was placed in supine position on operating table, by putting small sand bag under the spine and medial border of scapula with elevation of head of table 30° to 45°.

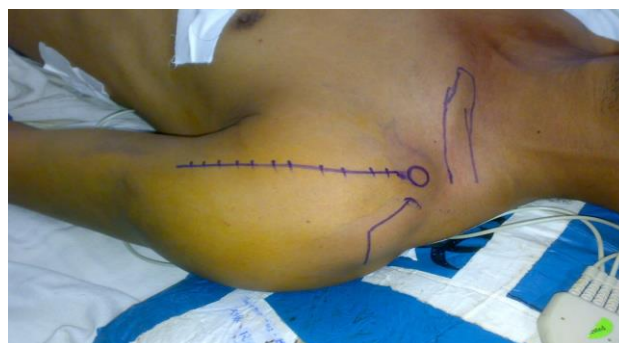### Incision

A deltopectoral approach was used with minimal soft tissue dissection. Skin incision was made and pectoralis major retracted medially and deltoid laterally after splitting them, short head of biceps and coracobrachialis with tip of coracoids process was detached and retracted medially, behind them pass a blunt

instrument between capsule and sub scapularis muscle then incise capsule to enter into joint.



**Figure 1: Positioning of the patient.**



**Figure 2: Marking of the delto-pectoral incision used for the proximal humeral locking system plate insertion.**

### Reduction

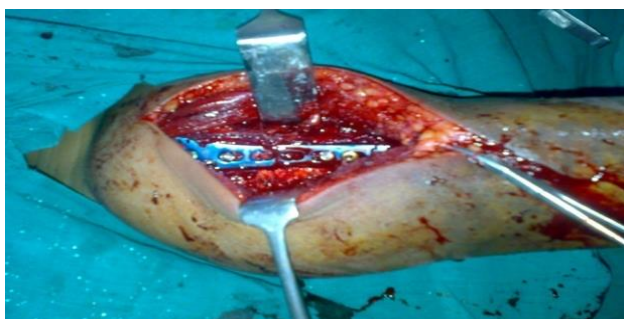It is eased by tension banding the infra-supraspinatus and the sub-scapularis in a first step. Depending on the fracture pattern, first the tubercles and the head fragment are reduced directly through the fracture gaps and their reduction is maintained by K-wires. In severely impacted valgus four part valgus fractures, the rotator cuff has to be opened alongside the fracture leading through the major tubercle to check for anatomic reduction. This holds also true when selected head split fractures are treated with plates. K-wires for temporary fixation should be placed in a way that they do not hinder the later plate positioning. To obtain a correct plate position two positioning wires are recommended. The first one 2–4 mm lateral to the bicipital groove and the second one 5–7 mm below the tip of the major tubercle.

Before the plate is fixed to the shaft with a cortical screw, the tension bands are inserted through the holes on the rim of the plate and then the plate is settled between the positioning wires and fixed with a cortical screw.

By traction on the tension bands the head segment is approached to the plate. After attachment of the aiming device, temporary fixation takes place by K-wires inserted through the drill sleeves. C-arm control takes then place under stable conditions allowing rotation of

the humeral head to obtain an antero-posterior and trans-axial X-ray. Insertion of the angular stable screws into the head fragment maintains the position of the latter. Before insertion of the head-locking screws it is important to pull on the tension bands to bring the head fragment in close contact with the plate. This prevents varus malposition.

The number and position of screws is dependent on the bone quality and the fracture configuration. In good bone stock 4–6 screws are sufficient, whereas in poor bone stock multiple fixation points using all screws is recommended. If inferomedial support is missing a slight impaction combined with an oblique-locked screw seems to achieve more stable medial column support and allow for better maintenance of reduction. Accurate measurement of screw length in osteopenic bone is difficult to obtain using a drill or a K-wire as a measuring device. Direct measuring with the depth gauge, after drilling the lateral cortex prevents penetrating the joint cartilage. The tips of the screws should stay 3–5 mm below the joint line. Too long screws with primary screw perforation during operation are one the major complications reported in the first series, which can be prevented following these precautionary measures. The plate is then fixed to the shaft. For this fixation head-locking screws or cortical screws can be used depending on the bone quality and according to the preference of the surgeon. The tension bands are then tightened to prevent secondary fragment displacement of broken tubercula during the early rehabilitation.



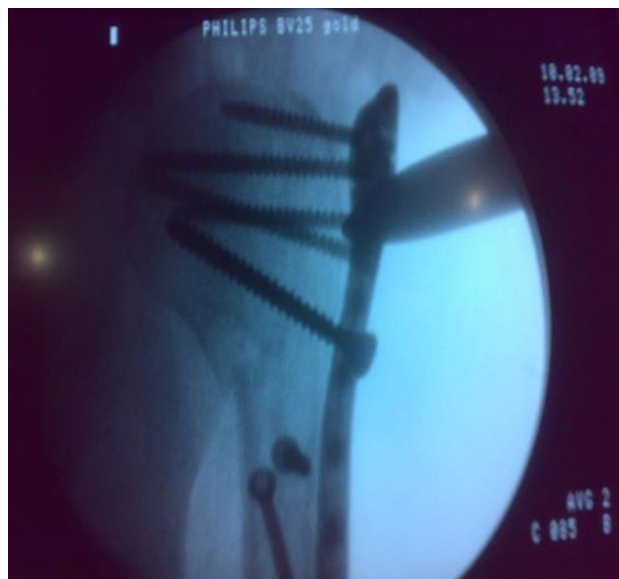**Figure 3: Insertion of proximal humerus locking plate with screws at the exact position needed.**

#### *Postoperative care*

Postoperatively patients were given with parenteral antibiotics for 5 days and oral antibiotics for 5 days. They were informed to use shoulder immobilizer. First postoperative dressing was done after 48 hours and drainage tube was removed. Second dressing was made on fifth postoperative day. Stitches were removed on tenth to twelfth postoperative day. Patient was discharged after stitch removal. Postoperative check X-ray was done after removal of drainage. It was assessed for the proper reduction, alignment/varus/valgus, screw sizes.

Patients were instructed to do the elbow mobilization, pendular and griding exercises passively after three

weeks of surgery and active exercises after 6 weeks of surgery under the guidance of a physiotherapist.



**Figure 4: Postoperative X-ray image.**

#### *Follow up*

Follow up was done on every month up to 3 months. On each follow up radiological assessment was done for checking the bone union. Functional evaluation of shoulder at final follow up was done using Constant-Murley score.<sup>11</sup>

## **RESULTS**

Table 1 presents the sociodemographic characters of the study participants. In the present study, a total of 20 patients were involved in the study. The mean age of the patient was 52 years; most of them were of old age. Maximum number of patients belonged to age group 51-70 years, so proximal humerus fracture is common in old age due to osteoporosis. Females are more affected than males. The most common mode of injury is low velocity trauma i.e. fall while walking or fall in bathroom. According to Neers classification 12 patients had three part fractures, 06 patients had two part fractures and 2 patients had 4 part fractures.

Table 2 shows the operating factors involved in the study. Patients were operated within average 3 of days. The average operative time for proximal humerus plating was 1 hour. As the learning curve of it is long, surgery requires expertization and experience which reduces the surgical time further. The average blood loss is 300 cc-500 cc. Eight out of twenty patients required blood transfusion in which there was more blood loss.

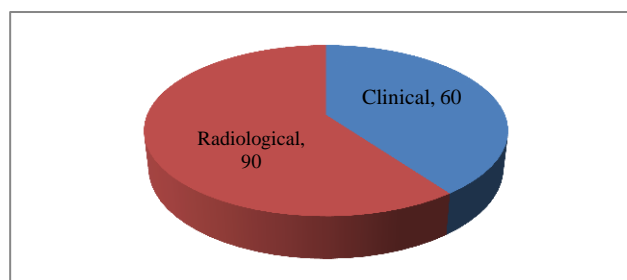
Fracture union was depicted in Figure 5. Average time for clinical union was 60 days, while average time for radiological union is 90 days taken in the study.

**Table 1: Socio-demographic characteristics of the patients.**

Variables	Values
Mean age of the patients	52
Sex distribution	No. of patients (n =20)
Males	09
Females	11
Type of injury	
High velocity	07
Low velocity	13
Type of fractures based on Neer,s classification	
Two part	06
Three part	12
Four part	02

**Table 2: Operating factors involved in the study.**

Factors	
Trauma surgery interval (in days)	2.36 days
Average operative time (in hours)	01
Average blood loss (in cc)	300-500
No. of patients required blood transfusion	08

**Figure 5: Time in days for union of fractures.**

Postoperative reduction time was shown in Table 3. In our series, anatomical reduction was achieved in 40% cases, near anatomic reduction in 44%, relative reduction in 16%, varus alignment in 0% of the patients.

**Table 3: Postoperative reduction percentages.**

Reduction	Percentage (%)
Anatomical reduction	40
Near anatomical reduction	44
Relative reduction	16
Varus alignment	00

Complications were presented in Table 4. Postoperative complications were encountered in 2 out of 20 patients. One patient developed wound infection one was a superficial wound infection that settled with antibiotics while the other one patient required surgical debridement. Delayed complications were seen in 10 cases. Stiffness in shoulder joint was seen in six patients, whereas abduction

weakness in four patients. Subluxation was not occurred in any of patient. No patients had shown implant related complications.

**Table 4: Complications.**

Type of complications	No. of patients
<b>Early complications</b>	
Instability	00
Suluxation	00
Dislocation	00
superficial infection	01
Deep infection	01
<b>Delayed complications</b>	
Stiffness	6
Abduction weakness	4
Subluxation	0
<b>Implant related complications</b>	Nil

Final outcome of the study after final follow up was done by constant scoring system as given in Table 5. All the cases were followed up for an average 3 months. The average score was 65 out of 100 points. 36% patients had shown excellent results, 53% patients had shown good results and poor results were seen in 11% of cases.

**Table 5: Final outcome of the study.**

Scoring	No. of patients (%)
Excellent	36
Good	53
Poor	11

## DISCUSSION

Treatment of proximal humerus fractures is very challenging. Several techniques and devices have been used for the fixation of these fractures. The main aim of treatment is the restoration of limb function. In the present study, the clinical and radiological results of the proximal humerus locking plates used in 20 patients, over a period of two years in our department was evaluated.

The average age of the patients involved in our study was 52 years; most of them were of old age. Maximum number of patients belonged to age group 51-70 years. This might be due to occurrence of complex proximal humerus fractures in older age groups. Similar observation was made in the study of Babst et al in which the mean age group of patients was 66.9 years that is higher as compared to present study. This can be explained by higher average life span of the U.K people than Indians.<sup>12</sup>

In present study male and female ratio male: female was 1.5:2, while in Babst et al study male: female ratio was 1:3.<sup>12</sup> This may be due to existence of females in the

study with postmenopausal osteoporosis as they more vulnerable to fracture.

In this series, the most common mode of injury is low velocity trauma i.e. fall while walking or fall in bathroom in 13 (65%) cases. Similar results were observed in the study of Junior et al.<sup>13</sup>

The average time interval between trauma and surgery in the present study was 2.36 days. It was 3.2 days in a study of Gerber et al.<sup>14</sup> This early operative treatment greatly reduces the mortality and morbidity, meanwhile giving best chance of early mobilization.

The average operative time for proximal humerus plating was 1 hour. The average blood loss is 300-500 cc. Eight out of twenty patients required blood transfusion in which there was more blood loss. One patient developed superficial infection and one patient had deep infection. In a study done by Leonard et al, the mean operative time was 81 minutes and the mean blood loss was 222 ml (range, 150–600). Two patients developed superficial wound infections that were responded to I.V. antibiotics.<sup>16</sup>

In our series the average time for clinical union was 60 days, while average time for radiological union was 90 days. In the study of Leonard et al, the mean time for radiologic outcome measurements was recorded at 84 days.<sup>16</sup>

As far as the reduction is concerned, in 40% cases, we achieved anatomical reduction, near anatomic reduction in 40% , relative reduction in 16%, varus alignment in 4% of the patients, while in the Babst et al study figures for the above parameters are 11%, 66%, 23% respectively and no varus alignment was noted.<sup>12</sup>

The functional outcome of the study was assessed by Constant Murley scoring system. In the functional evaluation, 36% patients had shown excellent results, 53% patients showed good results, and 11% patients showed poor or fair results in present study. These observations were comparable with the previous reports.<sup>16-18</sup>

## CONCLUSION

From the observations of our study, it was concluded that locking plate is an implant of choice for comminuted proximal humerus fractures. Plates with attached (locked) screws may provide improved fracture stability and healing. Locking the screw to the plate mechanically recreates a point of cortical bone contact, which may be useful in the poor cancellous bone of the proximal humerus. Patients can allow early mobilization so less chances of joint stiffness. Due to proper reduction and alignment there is no chances of nonunion and malunion. But there is also some drawback of locking plate like it is costly and it is not available easily.

*Funding: No funding sources*

*Conflict of interest: None declared*

*Ethical approval: The study was approved by the institutional ethics committee*

## REFERENCES

1. Court Brown CM, Caesar B. Epidemiology of adult fractures: A review. *Injury.* 2006;37:691-7.
2. Agudelo J, Schürmann M, Stahel P, Helwig P, Morgan SJ, Zechel W, et al. Analysis of efficacy and failure in proximal humerus fractures treated with locking plates. *J Orthop Trauma.* 2007;21(10):676-81.
3. Südkamp N, Bayer J, Hepp P, Voigt C, Oestern H, Kääb M, et al. Open reduction and internal fixation of proximal humeral fractures with use of the locking proximal humerus plate. Results of a prospective, multicenter, observational study. *J Bone Joint Surg Am.* 2009;91(6):1320-8.
4. Lanting B, MacDermid J, Drosdowech D, Faber KJ. Proximal humerus fractures: a systematic review of treatment modalities. *J Shoulder Elbow Surg.* 2008;17(1):42-54.
5. Thanasas C, Kontakis G, Angoules A, Limb D, Giannoudis P. Treatment of proximal humerus fractures with locking plates: a systematic review. *J Shoulder Elbow Surg.* 2009;18(6):837-44.
6. Monteiro GC, Ejnisman B, Andreoli CV, Pochini AC, Olympio E. Resultados do tratamento das fraturas do terço proximal do úmero com placas de bloqueio. *Acta Ortop Bras.* 2011;19(2):69-73.
7. Basti JJ, Dionysian E, Sherman PW, Bigliani LU. Management of proximal humeral fractures. *J Hand Ther.* 1994;7:111-21.
8. Hirschmann MT, Quarz V, Audigé L, Ludin D, Messmer P, Regazzoni P, et al. Internal fixation of unstable proximal humerus fractures with an anatomically preshaped interlocking plate: a clinical and radiologic evaluation. *J Trauma.* 2007;63(6):1314-23.
9. Badman BL, Mighell M. Fixed-angle locked plating of two-, three-, and four-part proximal humerus fractures. *J Am Acad Orthop Surg.* 2008;16:294–302.
10. Muller ME, Nazarian S, Koch P. The comprehensive classification of fractures of long bones. Berlin: Springer Verlag; 1990.
11. Constant CR, Murley AH. A clinical method of functional assessment of the shoulder. *J Clin Orthop Relat Res.* 1987;214:160-4.
12. Babst R, Brunner F. Plating in proximal humerus fractures. *European J Trauma Emergency Surg.* 2007;33:345-56.
13. Junior ACT, Cavalcanti AMG, Albuquerque BM, Ribeiro FR, Pereira da Costa M, Filho RB. Treatment of proximal humeral fractures using anatomical locking plate: correlation of functional and radiographic results. *Revista Brasileira de Ortopedia.* 2016;51(3):261-7.

14. Gerber C, Worner CM, Vienne P. Interlocking fixation of complex fractures of the proximal humerus. *J Bone Joint Surg (Br)*. 2004;86:848-55.
15. Leonard M, Mokotedi L, Alao U, Glynn A, Dolan M, Fleming P. The use of locking plates in proximal humeral fractures: Comparison of outcome by patient age and fracture pattern. *Int J Shoulder Surg*. 2009;3(4):85-9.
16. Deepak CD, Mahesh DV, Ravooof A, Baruah MJ. Functional outcome of displaced proximal humerus fractures managed by proximal humerus interlocking system plate. *Int J Res Orthop*. 2017;3:583-8.
17. Kiran Kumar GN, Sharma G, Sharma V, Jain V, Farooque K, Morey V. Surgical treatment of proximal humerus fractures using PHILOS plate. *Chinese J Traumatol*. 2014;17(5):279-84.
18. Kettler M, Biberthaler P, Braunstein V, Zeiler C, Kroetz M, Mutschler W. Treatment of proximal humeral fractures with the PHILOS angular stable plate. Presentation of 225 cases of dislocated fractures. *J Unfallchirurg*. 2006;109(12):1032-40.

**Cite this article as:** Tadvi ND, Deveshawar RN, Patel YC. Treatment of proximal humerus fracture using proximal humerus locking plating. *Int J Res Orthop* 2017;3:670-5.