

Case Report

A rare combination of comminuted distal ulna fracture with flexor tendons injury, median nerve injury and ulnar artery injury managed by staged fixation: a case report

Puspalatha Bontalakoti, Sarfaraz Hussain Rajavali*, Nageswararao Vutharkar, Sanjeeva Venkata Krishna Sai Marthy

Department of Orthopaedics, GSL Medical College and General Hospital, Rajahmundry, Andhra Pradesh, India

Received: 08 May 2026

Accepted: 17 June 2026

*Correspondence:

Dr. Sarfaraz Hussain Rajavali,

E-mail: sarfaraz.hzzn@gmail.com

Copyright: © the author(s), publisher and licensee Medip Academy. This is an open-access article distributed under the terms of the Creative Commons Attribution Non-Commercial License, which permits unrestricted non-commercial use, distribution, and reproduction in any medium, provided the original work is properly cited.

ABSTRACT

Isolated distal ulna fractures are uncommon and the combination with flexor tendon injury, partial median nerve injury, and ulnar artery disruption is exceedingly rare. These injuries present a significant reconstructive challenge requiring careful planning for skeletal stabilization and soft-tissue management. A 44-year-old male sustained high-energy trauma to the right forearm. Clinical evaluation revealed an open injury over the distal forearm with exposed bone and soft tissue, flexor tendon disruption, median nerve sensory-motor deficit and compromised ulnar artery perfusion. Radiographs demonstrated a comminuted distal ulna fracture. Intraoperatively, a partial median nerve injury and ulnar artery injury, flexor digitorum superficialis tendons injury were confirmed, while the ulnar nerve remained intact. Due to extensive soft-tissue compromise, the fracture was initially stabilized using an external fixator. After soft-tissue recovery, staged internal fixation with plate and screws was performed along with ipsilateral autologous fibular bone grafting to restore distal ulna alignment and stability. Radiological union was achieved with satisfactory functional recovery of wrist and finger movements with mild neurological deficits. This case highlights the rarity of combined distal ulna comminution with flexor digitorum superficialis tendon injury, median nerve injury and ulnar artery disruption. A staged approach using temporary external fixation followed by delayed internal fixation can optimize outcomes in complex wrist trauma with significant soft-tissue compromise.

Keywords: Distal ulna fracture, Comminuted ulna fracture, Flexor digitorum superficialis tendon injury, Open forearm fracture, External fixator

INTRODUCTION

Distal forearm injuries are commonly encountered in orthopedic trauma practice; however, complex injuries involving simultaneous damage to bone, tendons, nerves, and vascular structures are rare. Fractures of the distal ulna are usually associated with distal radius fractures, whereas isolated comminuted fractures of the distal ulna are relatively uncommon.^{1,2} When such fractures occur following high-energy trauma, they may be associated with severe soft-tissue injury, which can compromise hand

function and limb viability. Traumatic injuries involving the flexor tendons, median nerve and ulnar artery generally occur due to high-energy mechanisms or penetrating trauma to the volar forearm. These injuries may result in severe functional impairment because of loss of finger flexion, sensory deficits and compromised vascular supply to the hand. Management of these complex injuries poses significant challenges, as treatment must address both skeletal stability and restoration of injured soft-tissue and neurovascular structures. In cases with extensive soft-tissue damage, staged surgical intervention is often

preferred, allowing adequate debridement and temporary fracture stabilization followed by definitive fixation once soft tissues recover.

Reports describing the coexistence of distal ulna comminution with flexor tendon injury, median nerve injury, and ulnar artery disruption are extremely limited in the literature. This case report describes a rare presentation of such a complex injury managed with a staged fixation strategy and highlights the importance of early diagnosis, careful surgical planning and multidisciplinary management to achieve optimal functional outcomes.

CASE REPORT

A 44-year-old male presented to the emergency department with complaints of severe pain, swelling and an open injury over the right distal forearm following a high-energy road-traffic accident involving direct impact to the forearm. The patient had no history of diabetes mellitus, hypertension, alcohol consumption or smoking.

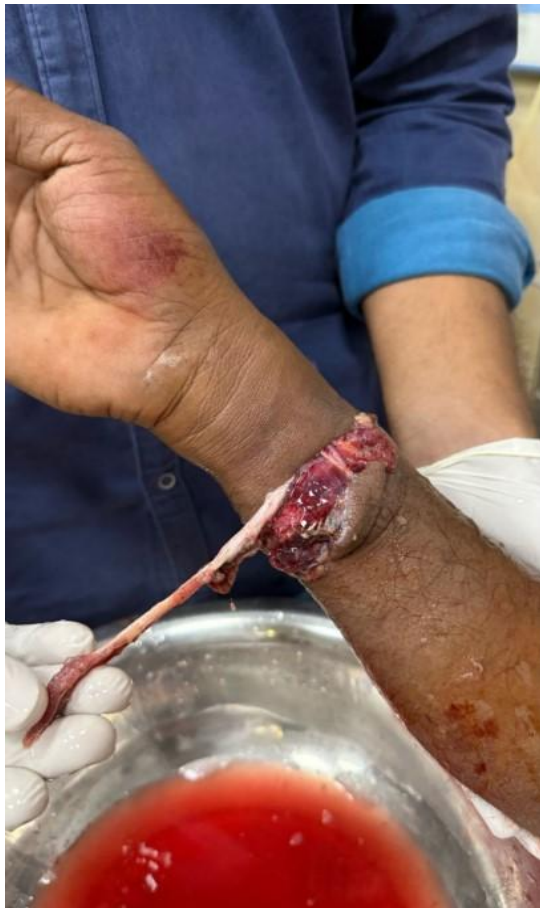

Figure 1: Showing compound injury over right forearm.

On examination, a compound wound was present over the distal aspect of the right forearm with visible soft-tissue damage and exposed bony fragments. There was diffuse tenderness, swelling and deformity over the distal forearm.

Active finger movements were limited due to pain and tendon injury. Sensory examination revealed decreased sensation in the distribution of the median nerve. Vascular assessment revealed absence of the ulnar artery pulse, while the radial artery pulse was palpable, suggesting adequate collateral circulation to the hand with capillary refill time of 2 seconds. No other associated injuries were identified.

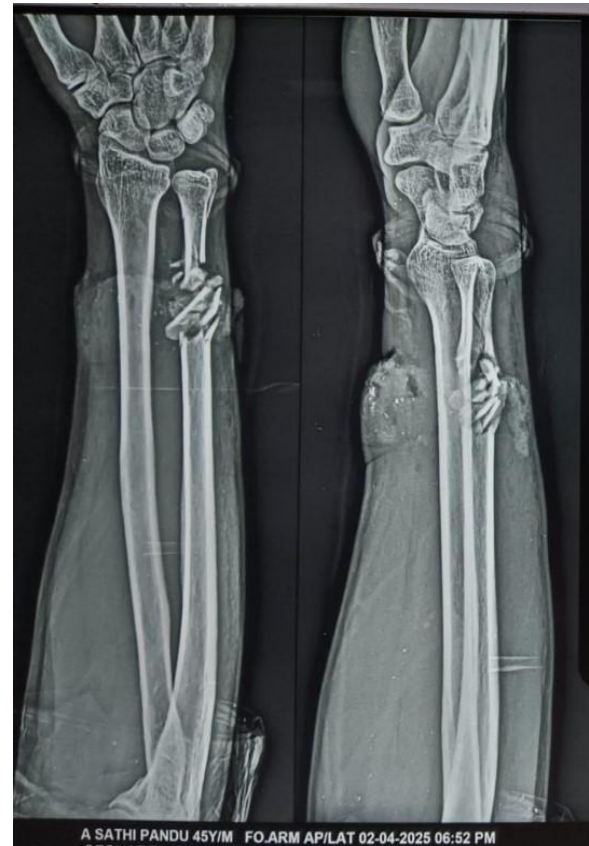

Figure 2: Radiograph of right forearm AP and LAT showing comminuted distal ulnar fracture.

Initial management included wound debridement, limb immobilization using a splint, administration of intravenous antibiotics and analgesics. Plain radiographs of the forearm revealed a comminuted fracture of the distal ulna with multiple fragments and DRUJ injury.

The patient underwent emergency surgical exploration. Thorough wound debridement and irrigation were performed under aseptic precautions. Intraoperatively, a comminuted fracture of the distal ulna was confirmed along with multiple soft-tissue injuries. A partial transection of the median nerve and complete transection of the ulnar artery were identified.

Because adequate perfusion of the hand was maintained through the radial artery, the ulnar artery was not repaired. The partially transected median nerve was left for spontaneous recovery as it was irreparable intraoperatively. Further exploration revealed flexor

digitorum superficialis (FDS) tendon tears involving the fourth and fifth digits.

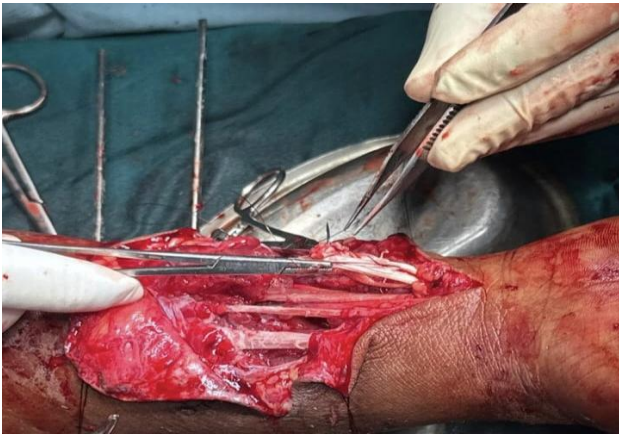

Figure 3: Showing FDS tendon repair.

Tendon reconstruction was performed in collaboration with Plastic surgeon by suturing the FDS tendons of the fourth and fifth digits to the FDS tendons of the second and third digits using the pulvertaft weave technique as end-to-end repair was not possible. Due to extensive comminution and soft-tissue injury, temporary fracture stabilization was performed using a spanning external fixator to maintain alignment and allow soft-tissue recovery. Postoperatively, the limb was immobilized and regular wound care was continued.

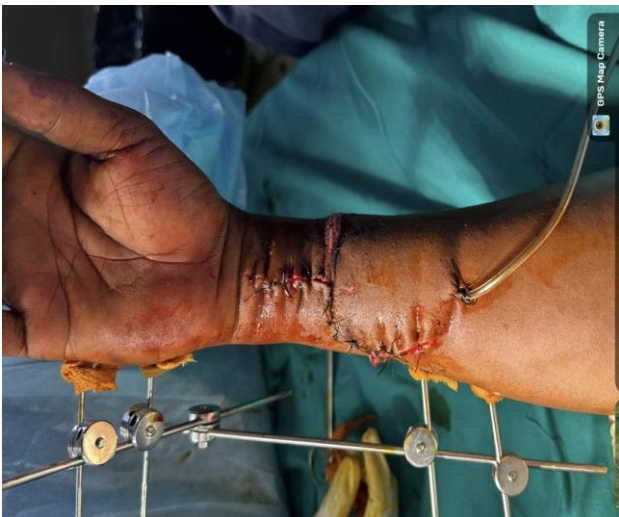

Figure 4: Showing spanning external fixator for ulna.

Even with regular dressings and wound care wound was infected and staphylococcus was isolated for which regular sterile dressings was done and treated with culture sensitive antibiotics. Further cultures came to be negative for any bacterial growth. After five months, once the soft tissues had healed adequately, definitive fixation was planned. The external fixator was removed and open reduction and internal fixation of the distal ulna was performed using a 10 holed recon locking plate and screws

and k wire fixation for DRUJ injury. Due to bone loss and delayed healing, an autologous fibular bone graft was used to augment fracture stability, ulnar alignment and promote union. Postoperatively, the limb was immobilized initially, followed by gradual physiotherapy to restore wrist and finger mobility. The patient was followed up regularly with clinical and radiological assessments.

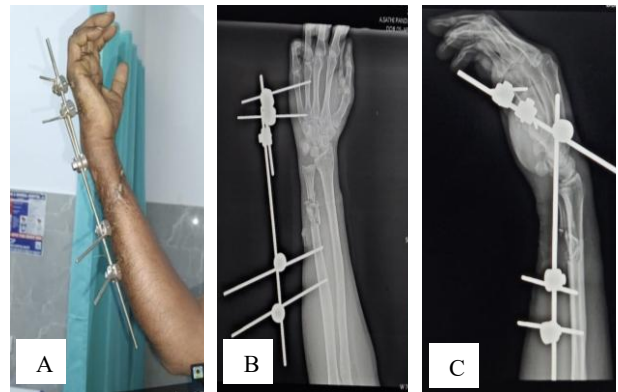


Figure 5 (A-C): Showing postoperative clinical image and radiological images (AP and LAT) of right forearm.

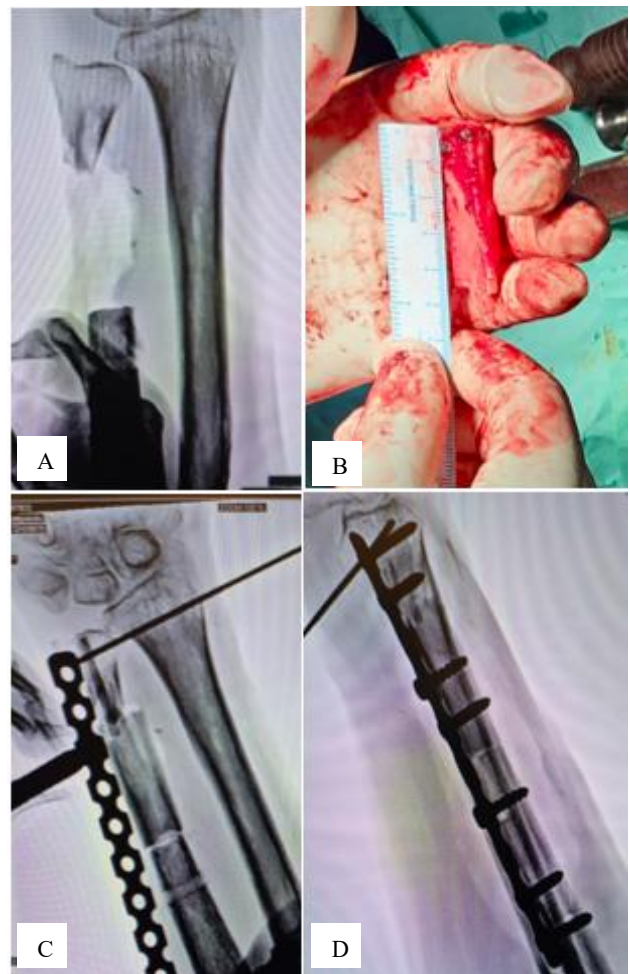


Figure 6 (A-D): Intraoperative images showing fibular graft placing and fixation.

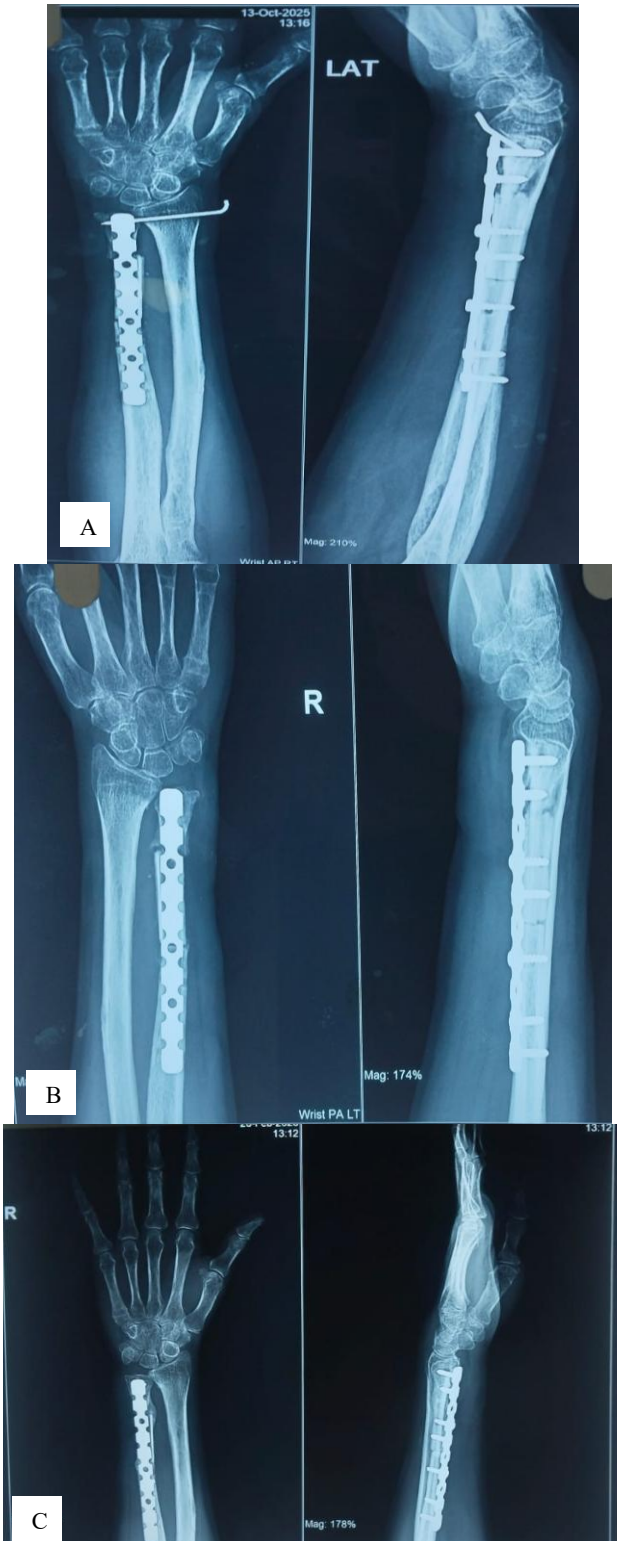

Figure 7 (A-C): Radiological images of right forearm AP and LAT on 0, 3, 6 months showing fracture union.

Progressive improvement in wrist and finger movements was observed during follow-up. Functional rehabilitation with range-of-motion exercises and grip-strengthening exercises was initiated. Radiological union of the fracture was achieved at approximately 11 months postoperatively.

At the final follow-up, the patient demonstrated satisfactory wrist and hand function with improved range of motion and grip strength, increased median nerve innervation and was able to perform activities of daily living without significant limitations.

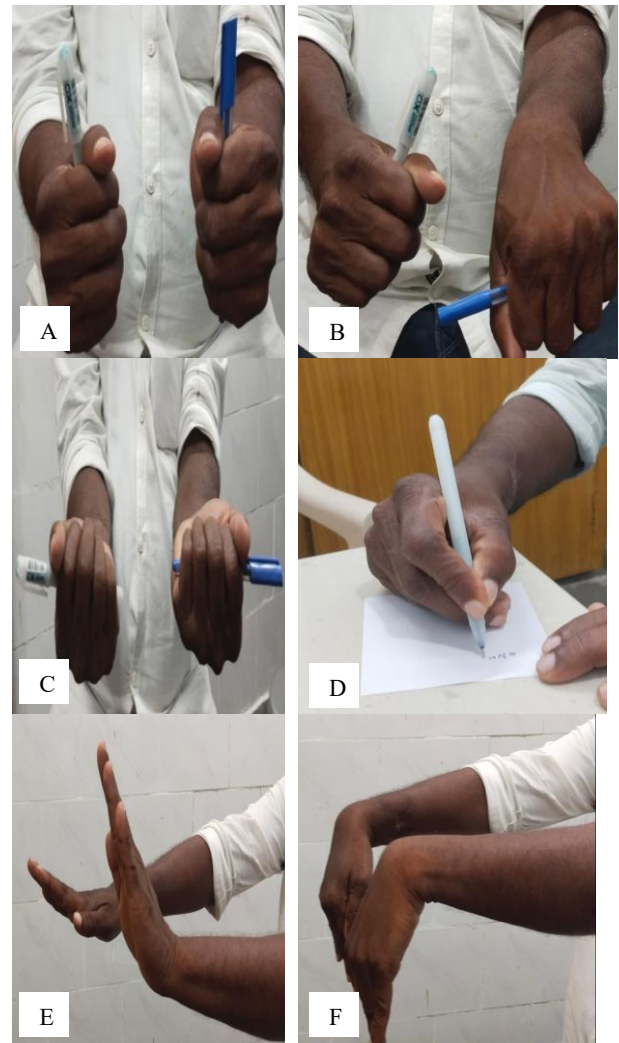


Figure 8 (A-F): Showing functional recovery.

DISCUSSION

Fractures of the distal ulna are relatively uncommon and are most frequently encountered in association with distal radius fractures. True isolated distal ulna fractures, particularly those with significant comminution, are rare and can present unique challenges in management due to their effect on distal radioulnar joint (DRUJ) stability and forearm rotation.^{1,2}

Disruption of the distal ulna, if inadequately treated, may lead to altered wrist biomechanics, chronic pain and restricted forearm rotation.³ High-energy trauma is the most common mechanism responsible for complex forearm injuries involving both skeletal and soft-tissue structures. Open fractures of the distal ulna are frequently associated with extensive soft-tissue damage because of

the close proximity of flexor tendons, neurovascular structures, and the confined volar compartment of the forearm.^{3,4} The intimate anatomical relationship between the distal ulna, flexor tendons, median nerve and ulnar artery makes these structures particularly vulnerable during high-energy trauma.

Management of distal ulna fractures depends on the fracture pattern, degree of displacement and associated soft-tissue injury. Stable and minimally displaced fractures may be managed conservatively, whereas displaced or comminuted fractures often require surgical fixation to restore alignment and forearm mechanics.^{2,3} Plate osteosynthesis has been shown to provide stable fixation in unstable distal ulna fractures, allowing early mobilization and improved functional outcomes.⁵

Flexor tendon injuries associated with forearm fractures are rarely reported but may occur due to sharp fracture fragments or direct traumatic laceration. Rupture of the flexor digitorum superficialis tendon has been described in association with forearm fractures and may lead to significant functional impairment if not addressed appropriately.^{6,7} Attritional rupture of flexor tendons has also been reported in cases of displaced distal ulna fragments causing mechanical irritation.⁸ Early recognition and timely reconstruction of tendon injuries are therefore essential to restore finger flexion and hand function.

Peripheral nerve injuries are another potential complication associated with forearm fractures. The median nerve, which runs along the volar compartment of the forearm, may be injured due to direct trauma, entrapment, or traction forces during fracture displacement.⁹⁻¹² Although uncommon nerve injuries following forearm fractures can result in sensory loss and motor dysfunction affecting hand function.^{13,14} In the present case, a partial transection of the median nerve was identified intraoperatively and was managed conservatively, allowing spontaneous recovery.

Vascular injuries associated with forearm fractures are rare but potentially serious. The ulnar artery contributes significantly to the superficial palmar arch and overall perfusion of the hand. Injury to this vessel may occur due to penetrating trauma or sharp fracture fragments.¹⁵ However, adequate hand perfusion can often be maintained through the radial artery and collateral circulation, allowing selective management of ulnar artery injuries in certain cases.¹⁶

The present case represents a rare combination of injuries, including an isolated comminuted distal ulna fracture with an open wound, flexor digitorum superficialis tendon tears of the fourth and fifth digits, partial median nerve injury, and ulnar artery laceration. Such a constellation of injuries is extremely uncommon and only sparsely described in the literature. In complex open fractures with severe soft-tissue compromise, staged management is often

recommended. Temporary stabilization using external fixation allows soft-tissue recovery and reduces the risk of infection before definitive internal fixation is performed.¹⁷ Once the soft tissues have healed adequately, plate osteosynthesis can restore the anatomical alignment and stability of the ulna, thereby facilitating fracture union and functional recovery.¹⁸

This case emphasizes the importance of careful clinical and intraoperative assessment in open distal forearm injuries. Associated injuries to flexor tendons, nerves and vascular structures may be easily overlooked if not systematically evaluated. Early recognition and appropriate management of these injuries, combined with stable fracture fixation and structured rehabilitation, are essential for achieving satisfactory functional outcomes in complex forearm trauma.^{19,20}

CONCLUSION

Isolated comminuted fractures of the distal ulna associated with flexor tendon, median nerve and vascular injuries are extremely rare and represent a complex pattern of forearm trauma. Successful management requires prompt recognition of associated soft-tissue injuries, meticulous surgical exploration and a carefully planned treatment strategy. In cases with extensive soft-tissue damage, staged management with initial wound debridement and temporary stabilization using external fixation allows adequate soft-tissue recovery before definitive fixation. Subsequent internal fixation with plate osteosynthesis and bone grafting can restore anatomical alignment and promote fracture union. Early tendon reconstruction and structured rehabilitation are essential to achieve satisfactory functional recovery. This case highlights the importance of a multidisciplinary and staged surgical approach in achieving good clinical and functional outcomes in complex distal forearm injuries.

Funding: No funding sources

Conflict of interest: None declared

Ethical approval: The study was approved by the Institutional Ethics Committee

REFERENCES

1. Biyani A, Simison AJM, Klenerman L. Fractures of the distal radius and ulna. *J Hand Surg Br.* 1995;20(3):357-64.
2. Logan AJ, Lindau TR. The management of distal ulnar fractures in adults: a review of the literature and recommendations for treatment. *Strateg Trauma Limb Reconstr.* 2008;3(2):49-56.
3. Richards TA, Deal DN. Distal ulna fractures. *J Hand Surg Am.* 2014;39(2):385-91.
4. Faierman E, Jupiter JB. Management of acute fractures involving the distal radioulnar joint and distal ulna. *Hand Clin.* 1998;14(2):213-29.
5. Fandridis EM, Dimou L, Stavropoulos S, Fernandez DL. Rupture of the flexor digitorum superficialis at

- the musculotendinous junction due to a forearm fracture: a case report. *J Wrist Surg.* 2014;3(2):121-4.
6. Williams J, Wharton R, Peev P, Horwitz M. Acute flexor tendon injury following midshaft radius and ulna fractures in a paediatric patient. *Trauma Case Rep.* 2018;15:1-3.
 7. Roberts JO, Hotokezaka S. Attritional flexor tendon rupture following distal radius fracture with volar displacement of the distal ulna. *J Hand Surg Am.* 1999;24(3):534-7.
 8. Hutchison RL, Wester CJ. Median nerve entrapment in the ulna in a both-bone pediatric forearm fracture: case report and review of literature. *Pediatr Emerg Care.* 2019;35(11):e220-2.
 9. Ardolino A, Webb D, Richards S. Median nerve entrapment in fracture callus following a paediatric forearm fracture: case report and review of literature. *Injury Extra.* 2009;40(11):210-2.
 10. Hurst JM, Aldridge JM. Median nerve entrapment in a pediatric both-bone forearm fracture: recognition and management in the acute setting. *J Surg Orthop Adv.* 2006;15(2):91-4.
 11. Lad P, Virkar N, Nighot A. Simultaneous median and ulnar nerve palsy as a late complication after pediatric forearm fracture fixation. *JBJS Case Connect.* 2025;15(1):e23.
 12. Hirasawa H, Sakai A, Toba N, Kamiuttanai M, Nakamura T, Tanaka K. Bony entrapment of the ulnar nerve after closed forearm fracture: a case report. *J Orthop Surg (Hong Kong).* 2004;12(1):110-2.
 13. Suganuma S, Ochi K, Ikuta Y. Ulnar nerve palsy associated with closed midshaft forearm fractures. *Orthopedics.* 2012;35(2):e283-6.
 14. Calderon Ardila D, Ballesteros Larrota DR, Calderon Ardila MA, Ballesteros Acufia LE. Traumatic injury of radial and ulnar artery with perfusion of the hand through the median artery: a case report. *Colomb Med (Cali).* 2021;52(2):e4054354.
 15. Strauch RJ, Moore JA. Pseudoaneurysm of the ulnar artery occurring after fractures of the distal radius and ulna: a case report. *J Hand Surg Am.* 1998;23(2):359-63.
 16. Geissler WB, Fernandez DL, Lamey DM. Distal radioulnar joint injuries associated with distal radius fractures. *Clin Orthop Relat Res.* 1996;(327):135-46.
 17. Ruchelsman DE, Raskin KB, Rettig ME. Outcome following distal ulna resection for comminuted distal ulna fractures. *Hand (N Y).* 2009;4(2):144-9.
 18. Court-Brown CM, Heckman JD, McQueen MM, Ricci WM, Tornetta P. *Rockwood and Green's Fractures in Adults.* 8th ed. Philadelphia: Wolters Kluwer; 2015.
 19. Canale ST, Beaty JH. *Campbell's Operative Orthopaedics.* 13th ed. Philadelphia: Elsevier; 2017.
 20. Wolfe SW, Hotchkiss RN, Pederson WC, Kozin SH. *Green's Operative Hand Surgery.* 7th ed. Philadelphia: Elsevier; 2017.

Cite this article as: Bontalakoti P, Rajavali SH, Vutharkar N, Marthy SVKS. A rare combination of comminuted distal ulna fracture with flexor tendons injury, median nerve injury and ulnar artery injury managed by staged fixation: a case report. *Int J Res Orthop* 2026;12:1150-5.