

Case Report

Intravascular ultrasound-guided mechanical thrombectomy for venous thoracic outlet syndrome presenting as Paget-Schroetter syndrome: a case report

Jaxon S. Boley^{1*}, Matthew Majer¹, Nick Abedi²

¹American University of the Caribbean School of Medicine, USA

²Vascular Surgery, Baptist Health (Lexington, KY), Kentucky

Received: 22 April 2026

Accepted: 26 May 2026

*Correspondence:

Dr. Jaxon S. Boley,

E-mail: jaxonboley@students.aucm.edu

Copyright: © the author(s), publisher and licensee Medip Academy. This is an open-access article distributed under the terms of the Creative Commons Attribution Non-Commercial License, which permits unrestricted non-commercial use, distribution, and reproduction in any medium, provided the original work is properly cited.

ABSTRACT

Paget-Schroetter syndrome is an uncommon but important manifestation of venous thoracic outlet syndrome, typically affecting young or physically active individuals and presenting with acute upper extremity swelling and pain due to effort-related subclavian vein thrombosis. Delayed recognition may result in persistent venous obstruction, recurrent symptoms, and long-term functional morbidity. We present the case of an otherwise healthy, physically active middle-aged male who developed acute right upper extremity swelling and pain secondary to extensive subclavian and axillary vein thrombosis. Initial duplex imaging demonstrated acute deep venous thrombosis involving the subclavian, axillary, and brachial veins. Despite anticoagulation and catheter-directed thrombolysis, the patient experienced persistent venous hypertension. He subsequently underwent intravascular ultrasound (IVUS)-guided mechanical thrombectomy using the RevCore and ClotTriever systems, with restoration of venous patency and confirmation of persistent subclavian vein compression at the thoracic outlet. The patient experienced rapid symptomatic improvement and later underwent definitive thoracic outlet decompression with first rib resection and scalenectomy two months later, without reported complications. This case highlights the importance of recognizing Paget-Schroetter syndrome as a compression-related upper extremity disorder, the value of intravascular ultrasound in defining the underlying anatomic lesion, and the role of mechanical thrombectomy followed by definitive decompression in management.

Keywords: Paget Schroetter syndrome, Upper extremity thrombosis, Mechanical thrombectomy, Subclavian vein thrombosis, Thoracic outlet compression

INTRODUCTION

Venous thoracic outlet syndrome is a compression disorder of the upper extremity in which narrowing of the subclavian vein at the thoracic outlet may lead to effort-related thrombosis, classically described as Paget-Schroetter syndrome.¹ It most commonly affects young, active individuals and is often associated with repetitive upper extremity motion.^{1,2} Early diagnosis and prompt treatment are important to prevent persistent venous obstruction, post-thrombotic morbidity, and long-term functional limitation of the affected limb.^{2,3}

Although definitive thoracic outlet decompression remains central to recurrence prevention, persistent venous obstruction after failed thrombolysis may require thrombus-directed endovascular intervention to restore patency and clarify the underlying anatomic compression.^{1,3,4}

We present a case highlighting the diagnostic and procedural value of IVUS-guided mechanical thrombectomy using contemporary thrombectomy devices in venous thoracic outlet syndrome presenting as Paget-Schroetter syndrome.

CASE REPORT

An otherwise healthy, physically active middle-aged male presented with acute onset right upper extremity swelling and discomfort. The patient reported no prior history of venous thromboembolism, hypercoagulable disorders, malignancy, or recent immobilization. His occupational and recreational history involved frequent upper extremity use. He endorsed a remote history of intermittent upper extremity paresthesia that had previously improved with physical therapy.

Initial evaluation and imaging

A right upper extremity venous duplex ultrasound performed on initial presentation demonstrated acute deep venous thrombosis involving the subclavian and axillary veins, with partial extension into the brachial venous system. The contralateral upper extremity veins were patent and compressible. Despite initiation of anticoagulation and catheter-directed thrombolysis therapy at an outside institution, the patient experienced persistent swelling and venous congestion.

Given the degree of symptoms and concern for underlying venous thoracic outlet compression with persistent venous obstruction, vascular surgery consultation was obtained.

Intervention

The patient was evaluated with repeat upper extremity venous duplex demonstrating occlusive acute thrombosis of the right subclavian, axillary, and proximal brachial veins. Given failed prior catheter-directed thrombolysis and persistent symptoms consistent with venous thoracic outlet obstruction, the patient underwent mechanical thrombectomy of the right subclavian, axillary, and brachial veins using a mechanical thrombectomy system. Initial intra-procedural venography demonstrated absent contrast opacification beyond brachial vein, with no flow through axillary/subclavian venous segments, confirming complete proximal venous occlusion (Figure 1).

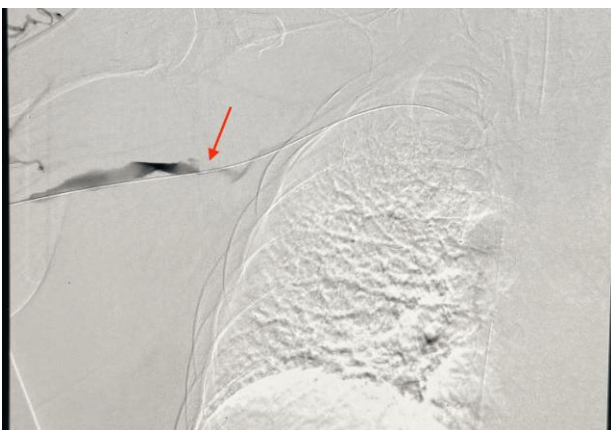

Figure 1: Initial venogram showing complete proximal venous occlusion.

Initial venogram demonstrating absent venous outflow beyond the brachial vein. The arrow indicates the cutoff point of contrast opacification, with no filling of the axillary or subclavian veins, consistent with complete proximal venous occlusion.

Crossing of the obstructed segment required both brachial and femoral venous access. The RevCore thrombectomy device was used to remove densely adherent thrombus from the obstructed venous segment (Figure 2), followed by the ClotTriever device to remove the remaining thrombus burden.

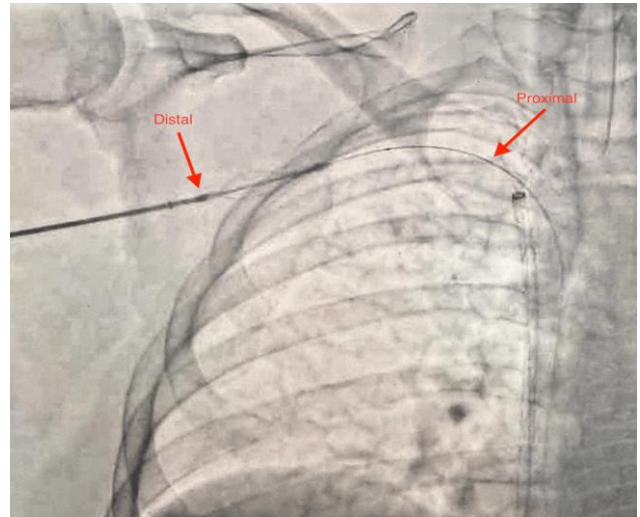


Figure 2: RevCore thrombectomy device across obstructed venous segment.

Fluoroscopic image demonstrating the RevCore thrombectomy device positioned across the obstructed right subclavian-axillary venous segment for removal of densely adherent thrombus. Labels indicate the distal and proximal orientation of the device across the occluded segment.

Intravascular ultrasound demonstrated severe compression of the subclavian vein at thoracic outlet, with only a small crescent-shaped residual lumen remaining (Figure 3).

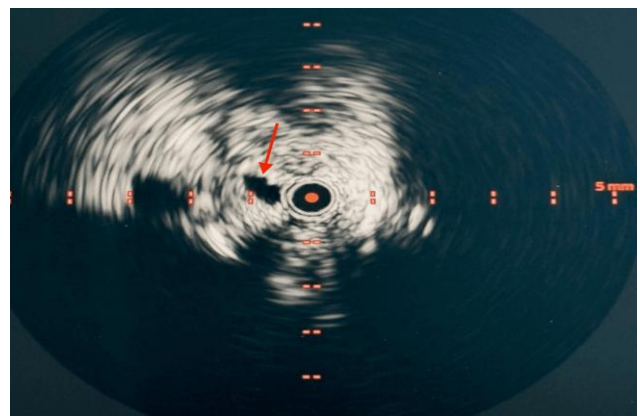


Figure 3: IVUS of thoracic outlet compression.

Intravascular ultrasound demonstrating severe compression of the subclavian vein at the thoracic outlet, seen as a small crescent-shaped residual lumen (arrow). IVUS: intravascular ultrasound.

Following thrombectomy, repeat IVUS demonstrated clearance of the axillary vein with improved luminal patency (Figure 4).

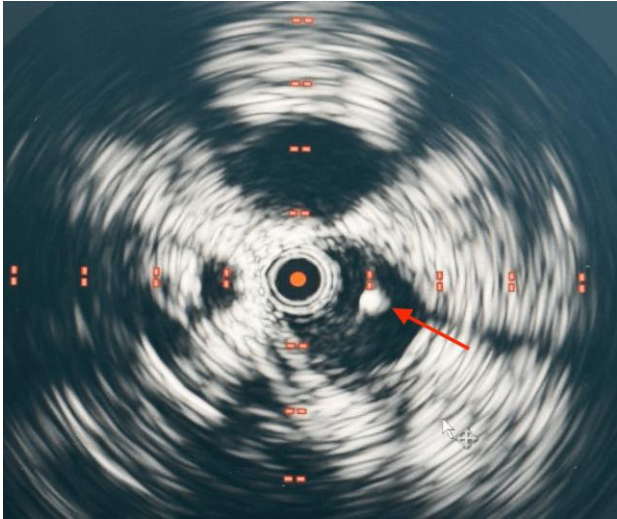


Figure 4: IVUS of improved axillary vein patency after thrombectomy.

Intravascular ultrasound after thrombectomy demonstrating clearance of the axillary vein with improved luminal patency. The arrow indicates the second intraluminal wire. IVUS: intravascular ultrasound.

Balloon angioplasty of the subclavian vein was then performed, and completion venography demonstrated re-established normal venous flow through the right axillary-subclavian venous system (Figure 5).

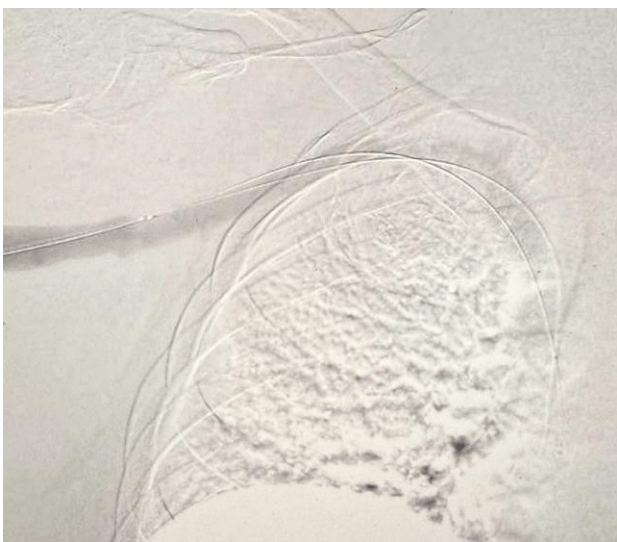


Figure 5: Completion venogram of restored venous flow.

Completion venogram after mechanical thrombectomy demonstrating re-established normal venous flow through the right axillary-subclavian venous system.

Persistent focal narrowing at the thoracic outlet remained evident, consistent with ongoing extrinsic compression. No procedural complications occurred.

Post-procedure course and follow-up

Following intervention, the patient experienced marked improvement in right upper extremity swelling and venous congestion. At early follow-up, distal edema had resolved with continued improvement proximally. At subsequent outpatient evaluation, the patient reported near-complete symptom resolution and had returned to work with activity modification. Based on IVUS findings and clinical course, definitive thoracic outlet decompression with right first rib resection and scalenectomy was performed on approximately two months later. No operative complications were reported.

DISCUSSION

Paget-Schroetter syndrome is a distinct form of primary upper extremity deep venous thrombosis caused by repetitive mechanical compression of the subclavian vein at the thoracic outlet.¹ Unlike secondary upper extremity thrombosis associated with indwelling catheters or malignancy, effort thrombosis occurs in otherwise healthy, physically active individuals and carries a risk of long-term morbidity if not promptly recognized and treated.^{1,5} Early recognition and prompt thrombus-directed therapy are essential to prevent chronic venous obstruction and long-term disability.^{2,3}

Duplex ultrasound is typically the first-line diagnostic modality; however, it may underestimate dynamic or positional venous compression.⁶ In this case, intravascular ultrasound provided critical real-time assessment of both thrombus burden and underlying extrinsic compression, demonstrating severe subclavian vein narrowing at the thoracic outlet and improved luminal patency following thrombectomy. IVUS therefore served both diagnostic and procedural roles by defining the anatomic cause of obstruction and confirming procedural success.⁷

Contemporary management favors early thrombus-directed therapy to restore venous patency and relieve acute symptoms, followed by definitive surgical decompression to address the underlying anatomic cause.^{1,3,4} Mechanical thrombectomy and balloon angioplasty were effective in this patient, resulting in rapid symptomatic improvement. However, without thoracic outlet decompression, recurrence rates remain high due to persistent extrinsic compression.^{2,4} Accordingly, mechanical thrombectomy alone may be insufficient when significant residual thoracic outlet compression persists, and definitive decompression is required to reduce recurrence risk.

First rib resection with scalenectomy remains the cornerstone of definitive treatment for venous thoracic outlet syndrome and has been shown to improve long-term venous patency and functional outcomes when performed after thrombus clearance.^{4,8} Subclavian vein reconstruction with patch angioplasty or bypass is occasionally required.^{1,9} This case highlights the importance of a staged approach in which IVUS-guided mechanical thrombectomy restores patency and clarifies the underlying anatomy after failed thrombolysis, while definitive thoracic outlet decompression addresses recurrence risk.

CONCLUSION

This case highlights the importance of recognizing Paget-Schroetter syndrome as a manifestation of venous thoracic outlet syndrome in physically active patients presenting with acute upper extremity swelling and pain. IVUS-guided mechanical thrombectomy provided effective thrombus clearance, restored venous patency, and helped define the underlying compression at the thoracic outlet. Definitive decompression with first rib resection and scalenectomy remained essential to address the underlying anatomic cause and reduce recurrence risk, completing management without reported complications.

Funding: No funding sources

Conflict of interest: None declared

Ethical approval: Not required

REFERENCES

1. Illig KA, Doyle AJ. A comprehensive review of Paget-Schroetter syndrome. *J Vasc Surg.* 2010;51:1538-47.
2. Urschel HC Jr, Razzuk MA. Paget-Schroetter syndrome: what is the best management? *Ann Thorac Surg.* 2000;69(6):1663-9.
3. Molina JE, Hunter DW, Dietz CA. Protocols for Paget-Schroetter syndrome and late treatment of chronic subclavian vein obstruction. *Ann Thorac Surg.* 2009;87(2):416-22.
4. Angle N, Gelabert HA, Farooq MM, Ahn SS, Caswell DR, Freischlag JA, et al. Safety and efficacy of early surgical decompression of the thoracic outlet for Paget-Schroetter syndrome. *Ann Vasc Surg.* 2001;15(1):37-42.
5. Mustafa S, Stein PD, Patel KC, Todd RO, Robert H, Allen S. Upper extremity deep venous thrombosis. *Chest.* 2003;123(6):1953-6.
6. Patel P, Braun C, Patel P, Meha B, Housne B, Wojtek W, et al. Diagnosis of deep vein thrombosis of the upper extremity: a systematic review and meta-analysis of test accuracy. *Blood Adv.* 2020;4(11):2516-22.
7. Ulloa JG, Gelabert HA, O'Connell JB, Patel R, Rigberg DA. Intravascular ultrasonography provides more sensitive detection of subclavian vein stenosis than venography in patients presenting with Paget-Schroetter syndrome. *J Vasc Surg Venous Lymphat Disord.* 2021;9(5):1145-50.
8. Peek J, Vos CG, Uittenbogaart M, van de Pavoordt HDWM, van den Akker PJ, de Vries JP. Outcome of surgical treatment for thoracic outlet syndrome: systematic review and meta-analysis. *Ann Vasc Surg.* 2017;40:303-26.
9. Azakie A, McElhinney DB, Thompson RW, Raven RB, Messina LM, Stoney RJ. Surgical management of subclavian-vein effort thrombosis as a result of thoracic outlet compression. *J Vasc Surg.* 1998;28(5):777-86.

Cite this article as: Boley JS, Majer M, Abedi N. Intravascular ultrasound-guided mechanical thrombectomy for venous thoracic outlet syndrome presenting as Paget-Schroetter syndrome: a case report. *Int J Res Orthop* 2026;12:1113-6.