

## Case Report

# Combined arthroscopic anterior cruciate ligament reconstruction and retrieval of an impacted intra-articular metallic fragment: a case of double mechanical derangement

Nakka John Leo, Kanagarla Siva Praful, Shaik Rizwana\*, V. Nageswara Rao

Department of Orthopaedics, GSL Medical College and General Hospital, Rajahmundry, Andhra Pradesh, India

**Received:** 12 March 2026

**Revised:** 14 April 2026

**Accepted:** 22 May 2026

**\*Correspondence:**

Dr. Shaik Rizwana,

E-mail: [rizwanaazan@gmail.com](mailto:rizwanaazan@gmail.com)

**Copyright:** © the author(s), publisher and licensee Medip Academy. This is an open-access article distributed under the terms of the Creative Commons Attribution Non-Commercial License, which permits unrestricted non-commercial use, distribution, and reproduction in any medium, provided the original work is properly cited.

### ABSTRACT

Intra-articular foreign bodies in the knee are a less common and frequently overlooked cause of mechanical symptoms. In the presence of ligament injuries, intra-articular foreign bodies make up a complex clinical scenario that requires a comprehensive surgical approach. This clinical case describes a 27-year-old male patient with chronic knee instability and true mechanical locking following trauma. Radiographic evaluation revealed a high-grade rupture of the anterior cruciate ligament (ACL) and an impacted intra-articular metallic fragment on the weight-bearing surface of the medial femoral condyle (MFC). The patient underwent a combined arthroscopic procedure for the fluoroscopy-guided removal of the impacted intra-articular metallic body, followed by anatomical ACL reconstruction with a peroneus longus autograft. This clinical case demonstrates the idea of “dual” mechanical derangement, in which both translational instability and mechanical focal attrition coexist due to ACL injury and intra-articular foreign body, respectively. Early recognition and combined treatment of both conditions are crucial to avoid progressive chondral damage and subsequent joint degeneration.

**Keywords:** Internal derangement of the knee, ACL reconstruction, Intra-articular foreign body, Metallic fragment, Peroneus longus graft, Mechanical locking

### INTRODUCTION

Intramedullary knee disorders are mostly related to ligament pathology, especially anterior cruciate ligament (ACL) tear, which causes joint instability and mechanical imbalance.<sup>4-11</sup> On the other hand, intra-articular foreign body is relatively rare but an important reason for mechanical derangement, causing symptoms like pain, locking, and limited mobility.<sup>1-5</sup> Metalliferous foreign bodies, mostly after traumatic penetration injury, might not create problems immediately but may eventually provoke synovitis, chondral lesions, and even mechanical blockage.<sup>6-10</sup> A case involving ACL deficiency with an intra-articular foreign body presents itself as a compound situation where translational instability interacts with

mechanical irritation to promote faster degeneration of the joint.<sup>4-6</sup> Imaging is important for proper diagnosis; however, the interference caused by metal will prevent MRI use and keep X-ray relevant.<sup>3,15</sup> It is imperative to identify such combinations and perform joint arthroscopy to correct the problem known as double mechanical derangement.

### CASE REPORT

#### *Patient presentation*

A 27-year-old physically active male patient complained of left knee instability for six months after a twisting injury sustained during manual labor. The patient complained of

recurrent effusion, locking, and true mechanical locking, especially in the terminal phase of knee extension. He denied any previous knee surgery but gave a history of a penetrating injury to the knee at the time of trauma, which was treated conservatively at a different facility.

### **Clinical examination**

The knee was found to have mild effusion without deformity. Point tenderness was noted over the medial femoral condyle. Range of motion was restricted in the terminal phase of extension by a hard mechanical block rather than pain, which is more suggestive of intra-articular mechanical obstruction. Stability testing revealed a positive Lachman test demonstrating Grade III anterior translation with a soft endpoint. The pivot shift test was positive (Grade II), and the anterior drawer test was also positive. The posterior drawer test was negative. Gross instability associated with mechanical locking suggested a combined ligamentous injury and intra-articular pathology.

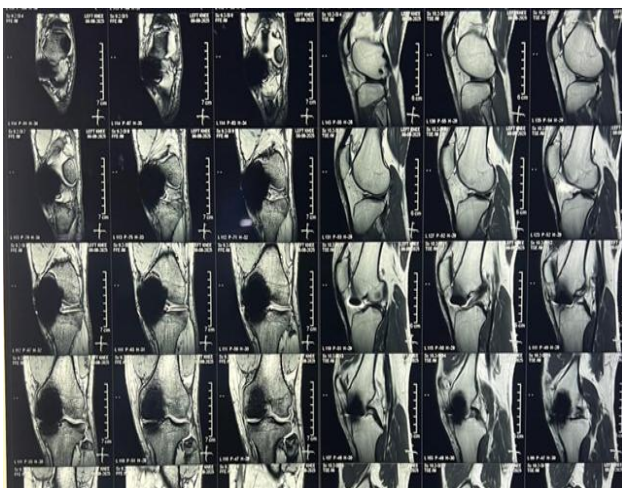
### **Imaging evaluation**

#### *Plain radiography*

Conventional anteroposterior and lateral radiographs showed a well-defined metallic density measuring 5 mm, located in the subchondral area of the weight-bearing surface of the medial femoral condyle. There were no obvious signs of degenerative changes. This supports the continued role of plain radiography in the assessment of knee injuries, especially with regard to the assessment of metallic foreign bodies, which can be underestimated on MRI.

#### *Magnetic resonance imaging*

MRI revealed a nearly complete rupture of the anterior cruciate ligament (ACL) with discontinuity of its fibers.



**Figure 1: MRI of left knee in coronal and sagittal sections.**

Secondary buckling of the posterior cruciate ligament was also noted, consistent with a chronically ACL-deficient knee. In addition, mild bone marrow edema was seen in the medial femoral condyle. A blooming artifact due to susceptibility effects from the metallic fragment precluded detailed evaluation of cartilage penetration and chondral surface integrity, although it drew attention to a potential problem with the chondral surface, which could not be accurately assessed due to artifacts from the metallic fragment.

### **Diagnosis**

A diagnosis of chronic rupture of the anterior cruciate ligament (ACL) with an impacted intra-articular metallic foreign body in the medial femoral condyle was made on the basis of clinical assessment and radiological evaluation. The coexistence of instability symptoms with objective mechanical locking was termed “double mechanical derangement.”

### **Therapeutic intervention**

#### *Intraoperative findings*

Diagnostic arthroscopy revealed complete rupture of the ACL with frayed ends, synovial hypertrophy in the medial compartment, and an impacted metallic foreign body in the articular cartilage and subchondral bone of the medial femoral condyle. The “ploughing effect” on the opposite medial tibial plateau due to the torn ACL was confirmed by dynamic testing and accounted for the patient’s mechanical locking and pain.

#### *Foreign body retrieval technique*

Because of the fragment’s impaction and weight-bearing position, the preservation of the articular cartilage was emphasized.



**Figure 2: Foreign body removed from the medial condyle of left femur.**

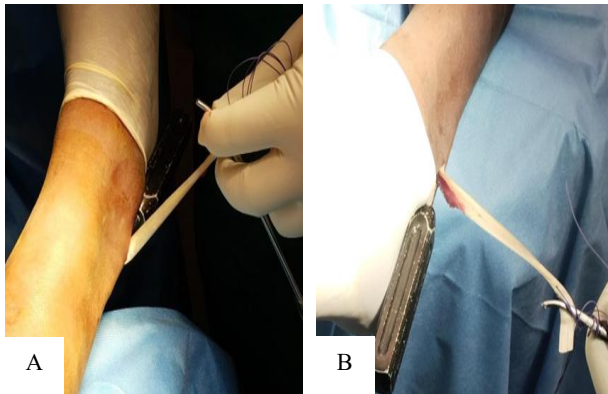
The fragment was accurately localized intraoperatively with the aid of fluoroscopy. The limited cartilage damage allowed access to the fragment, and a small pituitary

rongeur was used to remove it with minimal subchondral bone damage. Irrigation was done to remove microscopic metallic debris and to prevent synovial siderosis.

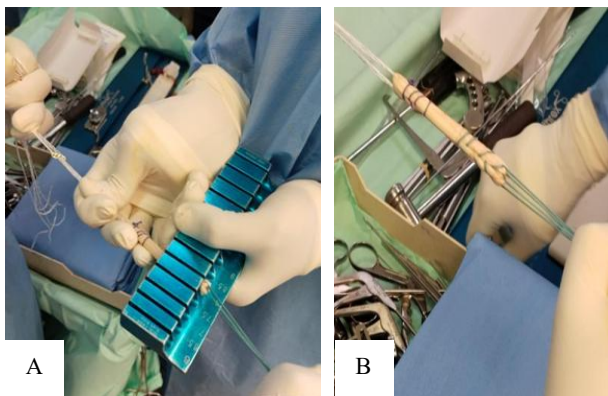
### ACL reconstruction

#### Graft choice

The ipsilateral peroneus longus autograft was used. This graft has high tensile strength, a large possible diameter, and low donor site morbidity, with previous studies showing maintained ankle stability and equivalent results to hamstring grafts.



**Figure 3 (A and B): Peroneus longus from ipsilateral side incised and stripped.**



**Figure 4 (A and B): Graft measured and looped end button; ethibond tied to quadruple graft.**

#### Surgical method

Anatomical femoral and tibial tunnels were created arthroscopically. Femoral tunnel fixation was performed with a suspensory cortical button, and tibial fixation with a biointerference screw. Graft tensioning was carried out in full extension to restore stability intraoperatively.

#### Rehabilitation after surgery

A standardized ACL rehabilitation protocol was followed, including early weight-bearing, recovery of full extension,

progressive strengthening, and proprioceptive exercises. The patient was allowed to progress to non-pivoting activities at three months, with a gradual return to sports at nine months.

### DISCUSSION

The commonest cause of internal derangement of the knee is ligament injury; ACL tear causing instability and impaired knee mechanics is well recognized.<sup>4-11</sup> On the other hand, the presence of an intra-articular foreign body, although uncommon, causes clinical problems related to mechanical issues, such as pain, locking, and limitation of mobility.<sup>1-5</sup> This case shows the coexistence of these two entities and represents a unique “double mechanical derangement” with a simultaneous presence of instability due to translational mechanism and mechanical impingement by intra-articular objects. The consequences of ACL deficiency are characterized by abnormalities in tibiofemoral mechanics, mainly consisting in an increased anterior sliding and rotational instability that causes further damage to the articular cartilage and meniscus.<sup>4-12</sup> At the same time, retained metal objects in the joint after penetrating injury may create focal mechanical irritation and cause real joint locking, cartilage abrasion, and recurrent joint effusions.<sup>6</sup> As was shown previously, these objects might remain clinically unappreciated despite being a significant source of chronic intra-articular pathology.<sup>1-6</sup>

Prompt detection and removal of intra-articular foreign bodies are key factors in preventing potential sequelae. The usefulness of arthroscopic debridement in providing effective management with little morbidity has been previously demonstrated.<sup>5-13</sup> Furthermore, apart from mechanical considerations, the presence of metallic bodies is associated with synovial siderosis and iron-dependent cytotoxicity, which also leads to cartilage degeneration.<sup>10</sup> This serves to underline the necessity for early action, even when there is only mild presentation. Imaging is key to diagnosis, but every approach has its drawbacks. Despite MRI being the current gold standard in ligament damage assessment, metallic susceptibility effects might lead to misdiagnosis, especially regarding the concurrent chondral changes.<sup>15</sup> In light of this fact, plain x-rays remain important diagnostic tools in the case of metallic foreign bodies.<sup>3</sup>

A one-step surgical technique involving arthroscopy for the treatment of both conditions is well-supported in the current literature. A combination of treatments will enable simultaneous repair of joint stability and removal of physical obstruction, leading to a decrease in patient morbidity and faster rehabilitation process.<sup>1-13</sup> The correct identification and precise extraction of the bone fragment can minimize the risk of injury to cartilage, while irrigation can help avoid any metal residue from remaining within the joint cavity.<sup>10</sup> ACL reconstruction using anatomical techniques ensures joint stability and biomechanics, which are necessary for long-term results.<sup>11</sup> The application of

the peroneus longus tendon in ACL reconstruction surgery, as used in this patient's treatment, has been recently proven in literature to be equal in terms of biomechanics and function when compared to hamstring autografts, with no side effects on the donor site.<sup>7,16,17</sup> The current case highlights the need for a thorough assessment in patients with signs and symptoms of mechanical problems in the knee joint, especially post-injury. The appreciation of dual pathology is paramount, as not treating both problems simultaneously would lead to continued problems and early onset of arthritis. The term "double mechanical derangement" is helpful in appreciating the relationship between the two, which allows for a one-stage solution.

### ***Peroneus longus autograft as a new option***

The use of the peroneus longus tendon for this case warrants specific mention. Historically, hamstring and bone-patellar tendon-bone grafts have dominated the grafting options for anterior cruciate ligament reconstruction, but recent literature shows that the peroneus longus tendon has a sufficient graft diameter, is biomechanically favorable, and also has high ultimate tensile strength, making it a new viable alternative. The importance of multiple donor site morbidities related to ankle instability has been greatly reduced through previous research, which showed that patients with peroneus longus tendon grafts have significantly improved ankle function and high levels of patient satisfaction after surgery. In the present case, the peroneus longus tendon graft provided excellent intraoperative stability, and the patient had no donor site complications, further supporting the use of this graft option in selected cases.

The clinical implications of this case highlight several important learning points. There should be a high index of suspicion for intra-articular foreign bodies in patients with a history of penetrating trauma, even when initial management has been conservative. In cases where the joint is unstable yet also demonstrates mechanical locking, a combined pathology should be considered rather than attributing symptoms to an isolated ligament injury alone. Plain radiographs remain an indispensable tool for identifying radiopaque foreign bodies, which may be missed or obscured on MRI. Furthermore, delayed diagnosis or delayed surgical intervention may result in progressive and irreversible cartilage damage, ultimately increasing the risk of requiring joint replacement.

### **CONCLUSION**

This case represents a good outcome in the context of a rare but important pattern of injury: ACL rupture with impacted intra-articular metallic foreign bodies. The injury was treated in a single-stage procedure performed arthroscopically. Proper identification and simultaneous treatment, referred to as "double mechanical derangement," are critical to restoring function and maintaining the integrity of the involved joint.

*Funding: No funding sources*

*Conflict of interest: None declared*

*Ethical approval: Not required*

### **REFERENCES**

1. Sinha S, Naik AK, Sharma V. Arthroscopic management of intra-articular foreign bodies of the knee. *Indian J Orthop.* 2014;48(4):393-7.
2. Kumar A, Yadav CS, Raj R, Singh S. Retained metallic foreign body in knee joint presenting as mechanical locking. *J Clin Orthop Trauma.* 2015;6(4):274-7.
3. Sharma P, Khatri K, Farooque K, Sharma V. Role of plain radiographs in detection of intra-articular foreign bodies of the knee. *Indian J Radiol Imaging.* 2012; 22(4): 315-8.
4. Nagi ON, Dhillon MS, Aggarwal S. Chronic ACL deficiency and secondary articular damage. *Indian J Orthop.* 2003;37(3):178-82.
5. Rai SK, Yadav R, Verma R. Arthroscopic removal of metallic foreign body from knee joint: A case report. *J Orthop Case Rep.* 2017;7(2):36-9.
6. Singh H, Jindal N, Garg S. Mechanical locking of knee due to retained foreign body. *Indian J Orthop Surg.* 2016;2(1):62-5.
7. Shah VM, Bhalodiya HP. Functional outcome of ACL reconstruction using peroneus longus autograft. *Indian J Orthop.* 2020;54(4):497-503.
8. Rajan D, Prakash M, Srinivasan R. Peroneus longus tendon as an autograft for ACL reconstruction: Early Indian experience. *J Clin Orthop Trauma.* 2019;10(2):S241-5.
9. Patel NK, Doddabasappa SN, Shetty GM. Imaging evaluation of internal derangement of the knee. *Indian J Radiol Imaging.* 2014;24(4):301-12.
10. Dhillon MS, Bali K, Prabhakar S. Synovial siderosis of the knee secondary to a retained metallic foreign body. *Indian J Orthop.* 2011;45(6):583-5.
11. Johnson DL, Fu FH. Anterior cruciate ligament reconstruction: Why do failures occur?. *Instr Course Lect.* 1995;44:391-406.
12. Shelbourne KD, Gray T. Minimum 10-year results after ACL reconstruction. *Am J Sports Med.* 2009;37(3):471-80.
13. Pujol N, Beaufils P. Management of intra-articular foreign bodies of the knee. *Orthop Traumatol Surg Res.* 2009;95(7):529-35.
14. Jackson DW, Schaefer RK. Cyclops syndrome: Loss of extension following ACL reconstruction. *Arthroscopy.* 1990;6(3):171-8.
15. Guyer B, Smith M, Fishman EK. Imaging of metallic foreign bodies in joints. *Radiographics.* 1991;11(5):927-39.
16. Sun K, Zhang J, Wang Y, Liu H, Li Z, Cao X. Peroneus longus tendon autograft versus hamstring tendon autograft for ACL reconstruction. *Am J Sports Med.* 2019;47(4):1004-13.
17. Anghong C, Chernchujit B, Apivatgaroon A. Peroneus longus tendon graft for ACL

reconstruction: Biomechanical and clinical study. *Knee Surg Sports Traumatol Arthrosc*. 2015;23(12):3723-9.

18. Pujol N, Beaufils P. Management of intra-articular foreign bodies of the knee. *Orthop Traumatol Surg Res*. 2009;95(7):529-35.
19. Noyes FR, Barber SD, Mangine RE. Bone-patellar tendon-bone and hamstring grafts for ACL reconstruction. *Am J Sports Med*. 1997;25(3):355-64.
20. Helms CA, Major NM, Anderson MW, Kaplan PA. *Musculoskeletal MRI*. 2nd ed. Philadelphia: Saunders. 2009;421-35.

**Cite this article as:** Leo NJ, Praful KS, Rizwana S, Rao VN. Combined arthroscopic anterior cruciate ligament reconstruction and retrieval of an impacted intra-articular metallic fragment: a case of double mechanical derangement. *Int J Res Orthop* 2026;12:1182-6.