

## Original Research Article

# The radiological prevalence and co-pathology associations of acromioclavicular joint arthritis in symptomatic shoulders: preliminary observations from an MRI-based study

Mandeep Singh Dhillon, Aman Hooda, Nikunj Gupta, Harsh Mander\*,  
Abhishek Prasad, Mehar Dhillon

Department of Orthopaedics Fortis, Mohali, Punjab, India

**Received:** 15 February 2026

**Revised:** 04 April 2026

**Accepted:** 22 May 2026

### \*Correspondence:

Harsh Mander,

E-mail: [harshmander@live.com](mailto:harshmander@live.com)

**Copyright:** © the author(s), publisher and licensee Medip Academy. This is an open-access article distributed under the terms of the Creative Commons Attribution Non-Commercial License, which permits unrestricted non-commercial use, distribution, and reproduction in any medium, provided the original work is properly cited.

## ABSTRACT

**Background:** Acromioclavicular joint (ACJ) arthritis is a frequent but often overlooked cause of shoulder pain in older adults. Differentiating symptomatic ACJ degeneration from incidental, age-related changes is challenging, particularly when other conditions such as rotator cuff (RC) tears are present.

**Methods:** Forty-eight patients (mean age 61.6 years) with shoulder pain underwent standardized shoulder MRI. Three independent, blinded radiologists graded ACJ arthritis severity using the Shubin-Stein system. Inter-rater reliability was assessed with Fleiss' kappa. Associations with RC tears, glenohumeral (GH) arthritis, labral pathology, and biceps tendon pathology were analyzed.

**Results:** ACJ arthritis (grade  $\geq 2$ ) was found in 93.8% of patients, with 54.2% showing moderate-to-severe changes. The prevalence observed was higher than that reported in several asymptomatic cohorts. Inter-rater agreement for the Shubin-Stein classification was almost perfect ( $\kappa=0.821$ ). Increasing age was significantly associated with greater arthritis severity ( $p=0.003$ ). Severe ACJ arthritis was strongly correlated with full-thickness or massive RC tears ( $p=0.001$ ), but not with GH arthritis, labral pathology, or biceps pathology.

**Conclusions:** MRI-detectable ACJ arthritis is highly prevalent in symptomatic shoulders over age 50 and often coexists with significant RC pathology. The Shubin-Stein classification system shows high inter-rater reliability, supporting its clinical utility. These findings demonstrate the need for comprehensive shoulder evaluation, as concurrent ACJ pathology can affect diagnosis and intervention.

**Keywords:** Acromioclavicular joint, Shoulder pain, Shoulder MRI, Acromioclavicular joint arthritis, Shubin-Stein classification

## INTRODUCTION

Shoulder pain is a common musculoskeletal complaint in adults, especially those over 50.<sup>1</sup> While rotator cuff disease, adhesive capsulitis, and glenohumeral arthritis are well-known causes, the role of the acromioclavicular (AC) joint is often overlooked.<sup>2</sup> Overlapping symptoms from multiple sources create diagnostic difficulties and may lead to dissatisfaction with management outcomes. Anatomical studies by DePalma and colleagues have documented that deterioration of the intra-articular disk between the

acromioclavicular joint begins as early as the second decade of life.<sup>3</sup> This early breakdown of the disk predisposes the AC joint to accelerated wear and tear. Cadaveric and radiographic studies have consistently reported a high prevalence of AC joint degeneration, with some estimates reaching as high as 90% in individuals over 50 years of age.<sup>4</sup> Morphological studies have further detailed these age-related changes, noting a significant increase in degenerative features and anterior acromial spur formation in older specimens.<sup>5</sup> Concurrently, the radiographic joint space of the AC joint has been shown to

decrease significantly with advancing age in both men and women.<sup>6</sup>

Continuous wear and tear of the joint and the development of inferiorly directed osteophytes over the AC joint lead to repetitive trauma to the tendons, resulting in degeneration.<sup>7,8</sup> Thus, the two pathologies may not only coexist but may also be causally related. This observation raises a key clinical question: Does the AC joint contribute directly to shoulder pain, or are degenerative changes merely incidental findings associated with aging?

While age-related AC joint changes are well documented, few studies have specifically characterized the radiological features of the AC joint using MRI in symptomatic patients. This study of 48 patients acknowledges limitations including small sample size, single-centre design, and potential selection bias. MRI offers superior soft tissue contrast and can detect bone marrow edema, which may better indicate symptomatic pathology than degenerative changes alone. Reliable radiological classification systems are fundamental for both clinical and research use.

This observational study addresses these deficiencies by documenting the incidence of AC joint pathology in symptomatic patients. The primary aims were to determine the radiological prevalence and severity of AC joint arthritis in symptomatic patients over the age of 50 using the MRI-based Shubin-Stein classification system; to evaluate the inter-rater reliability of the Shubin-Stein classification when applied by three independent, blinded observers, thereby assessing its robustness as a diagnostic tool; and to investigate associations between MRI-defined AC joint arthritis and other intra-articular pathologies. To ensure consistency and improve reproducibility, a consensus process was used, and in cases of disagreement, the final grade was determined by majority vote. This approach provides a clear framework for future studies.

## METHODS

### *Study design and ethical approval*

This study was a prospective, single-centre, observational study conducted at the Department of Orthopaedics, Fortis Hospital, Mohali, Punjab, India, a tertiary care referral centre. Data were collected from all eligible patients presenting over 9 months. The study protocol, patient information sheet, and informed consent documents received full approval from the Institutional Ethics Committee before patient enrolment. Procedures were performed in compliance with relevant laws and institutional guidelines and had been approved by the appropriate institutional committee (IEC/2025/OAS/06). All participants provided written informed consent before their inclusion in the study, appreciating their voluntary participation and the use of their anonymized health records for research purposes. The inclusion and exclusion criteria were applied as specified:

### *Inclusion criteria*

The study included patients presenting with a symptomatic shoulder, such as pain or reduced range of motion, who were older than 50 years of age. Both dominant and non-dominant shoulders were included in the analysis.

### *Exclusion criteria*

Patients were excluded from the study if they had an asymptomatic shoulder, a history of acute trauma or previous surgery to the affected shoulder, a primary complaint of shoulder instability, or evidence of active infection. After applying these criteria, 48 patients were included in the analysis. Primary data were extracted from a prospectively maintained patient database for the study period.

### *Radiological evaluation*

All patients underwent standardized MRI of the symptomatic shoulder. Three independent, blinded observers ((musculoskeletal radiologists)) evaluated the scans. The imaging protocol included T1-weighted, T2-weighted with fat saturation, and STIR sequences with a 3 mm slice thickness to optimize contrast for detecting degenerative changes. The AC joint was graded for degenerative arthritis using the MRI-based Shubin-Stein classification system, which defines four grades of arthritis:<sup>9</sup>

*Grade 1 (normal):* Preserved joint space, no capsular distension, and no osteophyte formation (Figure 1A).

*Grade 2 (mild):* Capsular distension or minor degenerative changes without marked joint space narrowing (Figure 1B).

*Grade 3 (moderate):* Joint space narrowing, marginal osteophyte formation, and potential subacromial fat effacement (Figure 1C).

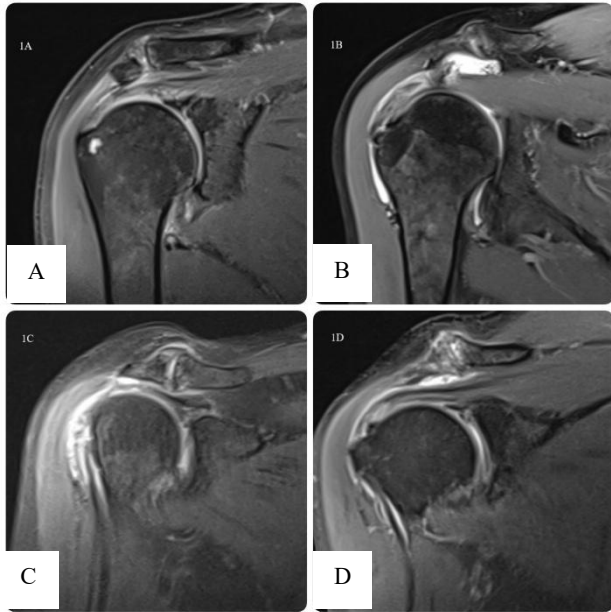
*Grade 4 (severe):* Severe joint space narrowing or bony contact, large osteophyte formation, capsular distension, and marked irregularity of articular surfaces (Figure 1D).

All other pathologies were identified on MRI and evaluated, including rotator cuff (RC) tear status, glenohumeral (GH) arthritis, labral pathology, and biceps tendon pathology.

### *Statistical analysis*

All statistical analyses were carried out using SPSS Statistics for Windows, Version 28.0 (IBM Corp., Armonk, NY). A two-tailed p-value below 0.05 was deemed indicative of statistical significance for all inferential analyses. The choice of Fleiss' kappa thresholds helps guide non-statistical readers through the results by delivering a clear interpretation: a kappa value of 0.821

indicates near-perfect reliability and offering confidence in the consistency of the observers' evaluations. Frequencies and percentages were computed for all categorical variables, encompassing sex, the prevalence of AC joint arthritis, and the prevalence of all recorded associated diseases. The mean, standard deviation (SD), and range were computed for the continuous age variable.



**Figure 1: MRI findings of AC joint arthrosis according to grades Shubin-Stein classification: (A) grade I, (B) grade II, (C) grade III and (D) grade IV.**

**Inter-rater consistency**

Fleiss' Kappa ( $\kappa$ ) was computed to evaluate the degree of concordance among the three musculoskeletal radiologists using the four-category Shubin-Stein grading scale. This statistical test was selected because it is primarily intended to assess inter-rater agreement for category ratings assigned by more than two raters.<sup>10</sup> The degree of agreement was assessed using the validated benchmarks set forth by Landis and Koch:  $\kappa$  values of 0.01-0.20 indicate slight agreement, 0.21-0.40 fair, 0.41-0.60 moderate, 0.61-0.80 substantial, and 0.81-1.00 almost perfect agreement.<sup>11</sup>

**Prevalence and association analysis**

For all analyses investigating the prevalence and associations of AC joint arthritis, a single consensus grade was first established for each patient. This was determined by taking the mode (the most frequent rating) of the three observers' grades (musculoskeletal radiologists). The association between categorical variables was assessed using the chi-square ( $\chi^2$ ) test of independence. When the assumptions of the chi-square test were not met, Fisher's exact test was used as an appropriate alternative. To compare the mean age across groups, an independent-

samples t-test was used for two-group comparisons. To compare the mean age across the four consensus grades of AC joint arthritis, a one-way Analysis of Variance (ANOVA) was employed.

**RESULTS**

A total of 48 patients who met the full inclusion criteria were enrolled and analyzed in this study. The cohort comprised 20 males (41.7%) and 28 females (58.3%). The mean age of the patients was 61.6 years with a standard deviation of 7.9 years, and the age range was from 50 to 85 years. All patients presented with a primary complaint of shoulder pain. The detailed radiological characteristics of the study population are summarized in Table 1. The demographic characteristics of the study population are summarized in Table 2.

**Table 1: Baseline radiological characteristics of the study cohort (n=48).**

Characteristics	Overall cohort
<b>Radiological findings, N (%)</b>	
ACJ arthritis (grade>1)	45 (93.8)
Full-thickness/massive RC tear	26 (54.2)
Partial-thickness RC tear	16 (33.3)
Glenohumeral (GH) arthritis	6 (12.5)
Labral pathology	19 (39.6)
Biceps tendon pathology	12 (25.0)

ACJ=Acromioclavicular; RC=Rotator Cuff; SD=Standard Deviation.

**Table 2: Demographic profile of the study population (n=48).**

Variables	Values
<b>Total patients</b>	48
<b>Mean age (years)</b>	61.6±7.9
<b>Age range (years)</b>	50-85
<b>Male, N (%)</b>	20 (41.7)
<b>Female, N (%)</b>	28 (58.3)

**Inter-rater reliability of ACJ arthritis grading**

Assessment of agreement among the three blinded observers in grading AC joint arthritis using the Shubin-Stein classification was a principal objective of this study. The analysis produced a Fleiss' Kappa coefficient of  $\kappa=0.821$  (95% CI: 0.723-0.919), which was statistically significant ( $p<0.001$ ). This result confirms that the Shubin-Stein classification is a highly reliable and reproducible tool for grading AC joint arthritis on MRI among different observers. The clinical effects of adopting a  $\kappa$  value above 0.80 as a threshold for daily reporting call for further consideration when evaluating the reliability of diagnostic methods.

**Prevalence and severity of ACJ arthritis**

According to the consensus radiological grading, 45 of 48 patients had signs of AC joint arthritis (a Shubin-Stein grade of 2 or higher), indicating that 93.8 % (95% Confidence interval) of this symptomatic group had imaging evidence of ACJ arthritis. The distribution in severity classes showed that most individuals had moderate-to-severe degenerative alterations. In particular, 26 patients (54.2% of the overall cohort) were categorized

as having either Grade 3 (moderate) or Grade 4 (severe) arthritis. Out of 48 individuals, only 3 (6.2%) had a normal joint (Grade 1). 19 patients (39.6%) were classified as having mild arthritis (Grade 2), indicating that this was the predominant manifestation. Fifteen patients (31.3%) had moderate arthritis (Grade 3), while eleven patients (22.9%) had severe arthritis (Grade 4).

**Table 3: Association of severe ACJ arthritis (grades 3-4) with concomitant MRI pathologies.**

Concomitant MRI pathology	Mild ACJ arthritis (grades 1-2) (n=22)	Severe ACJ arthritis (grades 3-4) (n=26)	P value
<b>Full-thickness/massive RC tear</b>			
Present, N (%)	6 (27.3)	20 (76.9)	0.001
Absent, N (%)	16 (72.7)	6 (23.1)	
<b>Glenohumeral (GH) arthritis</b>			
Present, N (%)	2 (9.1)	4 (15.4)	0.449*
Absent, N (%)	20 (90.9)	22 (84.6)	
<b>Labral pathology</b>			
Present, N (%)	8 (36.4)	11 (42.3)	0.741
Absent, N (%)	14 (63.6)	15 (57.7)	

P values are from the chi-square test, except for \* which denotes Fisher's exact test. RC=Rotator Cuff.

### Prevalence of concomitant pathologies

The other diagnosis from the MRI reports revealed a high burden of coexisting pathologies in this patient population. A rotator cuff tear of some degree was present in 42 patients (87.5%). Of these, full-thickness or massive tears were the most common, identified in 26 patients (54.2% of the total cohort). Labral pathology was noted in 19 patients (39.6%), and biceps tendon pathology was present in 12 patients (25.0%). Radiographic evidence of glenohumeral arthritis was the least common major co-pathology, found in 6 patients (12.5%). The frequencies of the observations are detailed in Table 1.

### Associations with ACJ arthritis

Analysis of demographic factors showed a significant relationship between patient age and the severity of AC joint arthritis. The mean age of patients with severe arthritis (Grades 3-4; n=26) was 64.7±7.5 years, which was significantly higher than the mean age of patients with mild arthritis (Grades 1-2; n=22), which was 58.0±6.9 years (independent samples t-test, p=0.003). There was no statistically significant association found between patient sex and the presence or severity of AC joint arthritis (p>0.05). A statistically significant association was observed between the severity of AC joint arthritis and the presence of rotator cuff tears. As shown in Table 3, patients with severe AC joint arthritis (Grades 3-4) were significantly more likely to have a full-thickness or massive rotator cuff tear compared to patients with mild AC joint arthritis (Grades 1-2). Specifically, 76.9% of patients with severe ACJ arthritis had a full-thickness/massive RC tear, whereas only 27.3% of those with mild ACJ arthritis had a tear of this severity

( $\chi^2=12.05$ , p=0.001). No significant associations were found between the severity of AC joint arthritis and the presence of glenohumeral arthritis, labral pathology, or biceps tendon pathology.

### DISCUSSION

Despite the ubiquity of shoulder complaints in older adults, the acromioclavicular (AC) joint remains underrepresented in the literature. A focused PubMed search for “incidence of acromioclavicular joint arthritis” yielded only six results, with only three directly relevant to prevalence or imaging-based studies. This conspicuous scarcity highlights a clear knowledge gap. Although symptomatic ACJ osteoarthritis is estimated to exceed 40% in individuals older than 50, the joint has been widely described as the “forgotten joint” of the shoulder girdle.<sup>9</sup>

In this context, our MRI-based cohort demonstrates that ACJ arthritis is extremely common in symptomatic shoulders. Shubin-Stein et al found that in symptomatic patients, none had a normal ACJ on MRI, with 52% moderate and 28% severe degeneration.<sup>9</sup> Hoogland et al similarly reported prevalence rates of MRI-detected ACJ arthrosis as high as 98% in spinal cord injured patients and 92% in non-disabled, symptomatic individuals. Another salient finding is the frequent clustering of ACJ arthrosis with rotator cuff tears and biceps tendon pathology.<sup>12</sup> This supports a notion of coexisting pathology clusters involving the ACJ and cuff, which may compound shoulder pain. Establishing a link between imaging severity and potential rehabilitation pathways could benefit clinical practice by enabling tailored interventions based on MRI findings. Mild cases might be managed with conservative therapies such as physical therapy and pain

management, though moderate to severe cases could require further assessment and intervention. By coordinating treatment strategies with imaging severity, clinicians can optimize outcomes for patients with ACJ-dominant pathology.

This prospective, observational study provides a focused radiological analysis of the acromioclavicular joint in symptomatic patients aged 50 or older. The investigation yielded three principal findings. First, the MRI-based Shubin-Stein classification system for AC joint arthritis demonstrated almost perfect inter-rater reliability ( $\kappa=0.821$ ) among three independent, blinded observers, attesting to its value as a reproducible assessment tool. Second, the radiological prevalence of AC joint arthritis in this symptomatic population was exceedingly high at 93.8%, with over half of the cohort (54.2%) exhibiting moderate to severe (Grade 3 or 4) degenerative changes. Third, a strong and statistically significant association was identified between the severity of AC joint arthritis and advanced patient age, as well as a substantial correlation with the presence of full-thickness or massive rotator cuff tears.

The finding of a 93.8% prevalence of radiological AC joint arthritis is consistent with the rates of up to 90% reported in previous studies of older, often asymptomatic, populations.<sup>4,13</sup> The critical distinction of the current study is its exclusive focus on a symptomatic cohort. This reveals that while radiographic changes are nearly universal with age, their presence in a patient presenting with shoulder pain cannot be dismissed as an incidental finding. The high proportion of patients with moderate-to-severe disease (54.2%) further indicates that substantial structural pathology of the AC joint is common in subjects seeking care for shoulder pain. Rossano et al reported arthroscopic findings in 218 patients with symptomatic acromioclavicular joint arthrosis, of whom all but 5 had concurrent pathologies, such as rotator cuff tendinopathy and labral changes, underscoring the importance of proper clinical correlation of shoulder joint-related symptoms.<sup>4</sup>

Importantly, for ideal management, it should be noted whether the AC joint is a pain generator in symptomatic patients. A study of 84 symptomatic patients with shoulder pain found that those with AC degeneration reported higher VAS pain scores.<sup>14</sup> Another study reporting 62 patients with a diagnosis of shoulder impingement was performed in a secondary care centre, evaluating the results of various shoulder tests (Neer, Hawkins-Kennedy, empty can, full can, external rotation resistance, lift-off, and cross-body adduction tests) before and after injecting in the ACJ or subacromial space. A significant difference was observed in the outcomes of all tests following the ACJ injection. The visual analogue scale also improved significantly, illustrating the importance of identifying the underlying pathology and of precisely examining the AC joint for pain.<sup>15</sup>

The demonstration of almost perfect inter-rater reliability for the Shubin-Stein classification supports the conclusions of the original study by Shubin-Stein et al, indicating that symptomatic patients tend to show more severe MRI findings.<sup>9</sup> Interestingly, it is important to note that Shubin et al in 2001 even reported an incidence of 82% (41/50) in asymptomatic shoulders with increased incidence with aging; however, the grade of degeneration was not reported.<sup>13</sup>

This poses the question of whether we should suspect AC joint changes in all elderly populations, asymptomatic or symptomatic. Choo et al performed a prospective study to differentiate asymptomatic patients (79/146) with negative physical examination findings for AC joint pathology from symptomatic patients (67/146) on 3-T MRI. The degree of superior capsular distention was the only significant finding in symptomatic patients, with a cutoff value of 2.1 mm, suggesting that 3T MRI may be an effective tool for diagnosing symptomatic patients.<sup>16</sup>

Perhaps the most clinically compelling result is the strong association between severe AC joint arthritis and the presence of full-thickness rotator cuff tears. As described by Neer and others, the formation of inferiorly directed osteophytes from the acromion and distal clavicle a hallmark of moderate-to-severe AC joint arthritis can physically narrow the supraspinatus outlet.<sup>7</sup> This can result in mechanical abrasion and attritional wear of the underlying supraspinatus tendon during arm elevation, possibly causing or accelerating the progression of rotator cuff tears. Our data, showing that 77% of patients with severe ACJ arthritis also had a full-thickness tear, strongly supports this concept of a "pathology cluster," where advanced degenerative disease in one structure is linked to severe pathology in an adjacent one. Gartsman and Hammerman found that untreated AC joint degeneration has the potential to impair outcomes of rotator cuff surgery.<sup>17</sup> Oh et al demonstrated that arthroscopic distal clavicle excision significantly improves outcomes in patients with AC joint arthrosis refractory to conservative therapy.<sup>18</sup> This finding reinforces our emphasis on a comprehensive preoperative MRI evaluation of the AC joint in elderly patients and the need to address both pathologies when clinically indicated.

Clinicians evaluating MRI scans that reveal a large rotator cuff tear may be inclined to attribute all patient symptoms to this single finding. However, the results of this study highlight the need for a diagnostic approach that extends beyond identifying the most conspicuous pathology on MRI.

This all-encompassing view is critical for distinguishing asymptomatic from symptomatic ACJ pathology patients with concomitant shoulder pathologies. Patients who undergo rotator cuff repair without a concurrent procedure to address symptomatic AC joint arthritis may develop persistent postoperative pain.<sup>19</sup> The presence of severe degenerative changes, especially when correlated with

clinical signs like localized tenderness, ought to prompt consideration of a combined surgical approach, such as rotator cuff repair with a concomitant distal clavicle excision.<sup>20</sup> This all-encompassing approach, which addresses all potential pain generators, is more likely to yield a successful and complete resolution of the patient's symptoms.

Several limitations of this study should be acknowledged. First, the relatively small sample size (n=48) may restrict the generalizability of the findings. Second, the single-center design introduces potential selection bias, as the study population consists of patients presenting to a tertiary care referral center, which may reflect more advanced or symptomatic disease. Third, the cross-sectional observational design prevents inference of causality between AC joint arthritis and associated shoulder pathologies. Age may act as a confounder in the observed association between ACJ severity and RC tears. Future multicenter studies with larger cohorts and integrated clinical-radiological correlation are necessary to validate these findings.

## CONCLUSION

This MRI-based observational study confirms that radiologically significant acromioclavicular joint arthritis is an extremely common finding in symptomatic patients over the age of 50, with more than half of the cohort demonstrating moderate-to-severe degenerative changes. The Shubin-Stein classification has demonstrated high reliability and reproducibility in classifying this pathology, corroborating its application in both clinical and research settings.

The correlation identified between severe AC joint arthritis and full-thickness rotator cuff tears suggests a possible mechanistic connection between these two common disorders. These findings highlight the importance of a thorough radiological evaluation of the entire shoulder complex, as the AC joint is a frequent and significant co-pathology that must be considered in the differential diagnosis and treatment planning for this complex patient population. Therefore, it is recommended that radiologists routinely grade ACJ on all shoulder MRI scans to ensure that meaningful findings are integrated into clinical practice, potentially increasing patient outcomes via addressing this often-overlooked source of shoulder pain.

## ACKNOWLEDGEMENTS

The authors would like to express their sincere gratitude to senior radiologist (AP) and his musculoskeletal radiology team for their independent, rigorous, and systematic classification of acromioclavicular joint pathology based

on MRI using the Shubin-Stein system, which formed the foundation of the radiological analysis in this study.

*Funding: No funding sources*

*Conflict of interest: None declared*

*Ethical approval: The study was approved by the Institutional Ethics Committee (IEC/2025/OAS/06)*

## REFERENCES

1. Belhobek GH, Richmond BJ, Piraino DW, Freed H. Special diagnostic procedures in sports medicine. *Clin Sports Med.* 1989;8(3):517-40.
2. Tirabassi J, Aerni G. Shoulder Conditions: Glenohumeral Joint Osteoarthritis and Adhesive Capsulitis. *FP Essent.* 2020;491:17-21.
3. DePalma AF. Surgical anatomy of acromioclavicular and sternoclavicular joints. *Surg Clin North Am.* 1963;43:1541-50.
4. Rossano A, Manohar N, Veenendaal WJ, Van den Bekerom MPJ, Ring D, Fatehi A. Prevalence of acromioclavicular joint osteoarthritis in people not seeking care: A systematic review. *J Orthop.* 2022;32:85-91.
5. Nicholson GP, Goodman DA, Flatow EL, Bigliani LU. The acromion: Morphologic condition and age-related changes. A study of 420 scapulas. *J Shoulder Elbow Surg.* 1996;5(1):1-11.
6. Petersson CJ, Redlund-Johnell I. Radiographic joint space in normal acromioclavicular joints. *Acta Orthop Scand.* 1985;54(5):431-3.
7. Neer CS. Impingement lesions. *Clin Orthop Relat Res.* 1983;(173):70-7.
8. Chen AL, Rokito AS, Zuckerman JD. The role of the acromioclavicular joint in impingement syndrome. *Clin Sports Med.* 2003;22(2):343-57.
9. Shubin Stein BE, Ahmad CS, Pfaff CH, Bigliani LU, Levine WN. A comparison of magnetic resonance imaging findings of the acromioclavicular joint in symptomatic versus asymptomatic patients. *J Shoulder Elbow Surg.* 2006;15(1):156-9.
10. McHugh ML. Interrater reliability: the kappa statistic. *Biochem Med (Zagreb).* 2012;22(3):276-82.
11. Landis JR, Koch GG. The measurement of observer agreement for categorical data. *Biometrics.* 1977;33(1):159-74.
12. Eriks-Hoogland I, Engisch R, Brinkhof MWG, Van Drongelen S. Acromioclavicular joint arthrosis in persons with spinal cord injury and able-bodied persons. *Spinal Cord.* 2013;51(2):159-63.
13. Shubin Stein BE, Wiater JM, Pfaff HC, Bigliani LU, Levine WN. Detection of acromioclavicular joint pathology in asymptomatic shoulders with magnetic resonance imaging. *J Shoulder Elbow Surg.* 2001;10(3):204-8.
14. Engin O, Ilengir AH, Dirim Mete B. The association between ultrasonographic findings and pain, physical function, and symptoms in patients with shoulder pain. *Acta Radiol.* 2024;65(12):1521-8.

15. Ulal AM, Erke S, Uyar S, Nacr B, Yılmaz, Erdem HR. The effect of acromioclavicular joint degeneration on orthopedic shoulder tests. *Eklemler Hastalıkları Cerrahisi*. 2013;24(2):77-81.
16. Ulaşlı AM, Erkeç S, Uyar S, Nacı B, Yılmaz Ö, Erdem H. Can symptomatic acromioclavicular joints be differentiated from asymptomatic acromioclavicular joints on 3-T MR imaging?. *Eur J Radiol*. 2013;82(7):e184-91.
17. Gartsman GM, Hammerman SM. Arthroscopic decompression and distal clavicle resection: A 5- to 13-year follow-up study. *J Shoulder Elbow Surg*. 2000;9(5):303-6.
18. Oh JH, Kim SH, Lee HK, Shin SH, Gong HS. Treatment of symptomatic AC joint pathology: The role of arthroscopy. *J Shoulder Elbow Surg*. 2010;19(1):47-53.
19. Pearson ZC, Agarwal AR, Garcia A, Mikula JD, Rupp MC, Best MJ. Evaluating the effect of rotator cuff repair with concomitant distal clavicle resection on 2- and 4-year reoperation rates. *JAAOS Glob Res Rev*. 2024;8.
20. Kibler WB, Sciascia AD, Morris BJ, Dome DC. Treatment of symptomatic acromioclavicular joint instability by a docking technique: Clinical indications, surgical technique, and outcomes. *Arthroscopy*. 2017;33(3):696-708.

**Cite this article as:** Dhillon MS, Hooda A, Gupta N, Mander H, Prasad A, Dhillon M. The radiological prevalence and co-pathology associations of acromioclavicular joint arthritis in symptomatic shoulders: preliminary observations from an MRI-based study. *Int J Res Orthop* 2026;12:983-9.