

Case Series

Functional outcome of fractures of the hand treated with Joshi's external stabilization system

Ravish V. N.*, Bharath Raju G., Sachin Prakash Yadrami

Department of Orthopaedics, Kempegowda Institute of Medical Sciences, Bangalore, Karnataka, India

Received: 22 August 2025

Revised: 29 November 2025

Accepted: 05 May 2026

*Correspondence:

Dr. Sachin Prakash Yadrami,

E-mail: Sachin02spy@gmail.com

Copyright: © the author(s), publisher and licensee Medip Academy. This is an open-access article distributed under the terms of the Creative Commons Attribution Non-Commercial License, which permits unrestricted non-commercial use, distribution, and reproduction in any medium, provided the original work is properly cited.

ABSTRACT

Hand is a distinct organ both for powerful grasp in lifting heavy objects as well as delicate pinch and hook functions. Hand injury is extremely common. Fractures of metacarpals and phalanges are probably the most common fractures in the skeletal system. Some of the causes of hand injuries are crush/compression injuries, blunt trauma, fall, road traffic accidents, sports related activity and explosions/fire arm injuries. Various modes of treatment have been used for hand fractures which include K wire fixation, mini plates, external fixator application. We have studied 20 patients with hand fracture treated with Joshi's external stabilization system (JESS). The study is conducted by the Department of orthopaedics KIMS, Bangalore. Detailed history collected from all patients. Thorough examination and investigations done. X-Ray of hand (AP, and Oblique views). The surgery is performed under regional and local anesthesia patients called for follow up at 4,8, 12 and 24 weeks JESS removal is done at 4-6 weeks depending on the status of fracture healing. In our study the functional outcome is based on the ASSH-TAF rating were predominantly good to excellent with 65% participants having excellent and 45% good outcome JESS is an effective alternative treatment for fractures of the hand. It is cheap and easily available. Technically, it is less demanding. It also reduces surgical trauma and protects the vascular integrity and has good-to-excellent functional outcome.

Keywords: JESS, Metacarpal, Phalanx, ASSH-TAF

INTRODUCTION

Hand fractures, namely those of the metacarpals and phalanges, are the most prevalent type of injury, accounting for 10-30% of all fractures. In the younger age range, where males are more likely to be injured, the incidence of hand injuries is seen to be higher.^{1,2} Fractures of the hand are a typical occurrence in emergency departments, and they can be caused by a variety of factors, including vehicle accidents, injuries sustained from machines, injuries sustained from crushes, attacks, and injuries resulting from explosions.^{3,4} The majority of the time, these injuries are disregarded as lesser injuries, which ultimately leads to the development of a functional limitation in the hand.¹⁻⁴ The healing of the wound, the

union of the bones, and most importantly, the restoration of the functions are the greatest goals that can be achieved through the treatment of hand injuries. Plaster and splints are the most common conservative treatments for hand injuries; however, surgical intervention is necessary for fractures that are unstable, comminuted, intra-articular, and open. This is necessary to preserve the functions of the hand by allowing soft tissue and bone to heal in the optimal position and allowing early range of motion of the joints.^{5,6} Depending on the fracture pattern and the condition of the soft tissue, there are a variety of surgical approaches that can be utilized to fixate the fracture. These techniques include the use of Kirschner (K) wires fixing, micro plates, and external fixator application. Each of these repair methods has its own set of advantages and disadvantages.

The external fixator, which operates on the principle of ligamentotaxis, is a device that is both successful and useful for the fixing of fractures, particularly in intra-articular fractures, displaced comminuted fractures, and open fractures, which are situations in which we must deal with both bone and soft tissue injuries.

Operational technique

Once other musculoskeletal and visceral injuries have been ruled out, a thorough history is collected, covering the amount of time that has passed since the injury, the mechanism of trauma, hand dominance, prior hand trauma or surgery, the functional condition of the affected limb, the occupation, the most recent meal, and the circumstances leading up to the injury. Hydrogen peroxide or regular saline is used as a disinfectant for the initial thorough cleaning of the wound. Following the preliminary assessment, basic preoperative blood parameters such as routine blood and virus markers are measured and X-rays of the affected areas are taken. Following an assessment for tissue injury and wound contamination, large pollutants are eliminated and a mild wash using regular isotonic fluid is administered. Up until the patient's time for surgery, an antiseptic dressing was used. Furthermore, the hand is supported with slab and lime is elevated to reduce the oedema.

The optimal location for pin placement and application of the external frame design is chosen following the initial wound wash and debridement. This is done with extreme precision in order to ease follow-up dressings and, if needed, perform additional surgeries such as skin and bone grafting. Traction and manipulation are used to decrease the fracture under C-arm guidance, and it is then further aligned. As the surgeon inserts the pins one at a time, the helper keeps the reduction in place. Percutaneous K-wires (1.2 mm, 1.5 mm, and 1.8 mm) with bicortical purchase were placed proximal and distal to the fracture site in order to preserve reduction. The connecting rod is kept in an extended position across I.P. joints. breaks affecting the metacarpophalangeal joints, fixators are positioned in functional posture at 70-80 degrees of flexion on MCP joints. The K-wires are installed in accordance with the safe zones, as recommended by Dr. B. B. Joshi and colleagues. Dorso laterally positioned K-wires are placed in the proximal and middle phalanges.

The lateral bands or the oblique retinacular ligament may be impaled by this. However, after the frame and pins are removed, these structures resume their intended function. For the metacarpal fractures, dorsal or dorsolateral pins were utilized. In order to prevent damage during pin insertion, superficial veins are pushed away with the loose skin covering them. Without transfixing the tendons, extensor tendons are located and retracted on both sides when the wires are passed through. The distance between connecting systems and skin is maintained at 5-7 mm. With less resistance from the surrounding frame, this spacing enables simpler wound and pin tract treatment. All

cables are clipped, and the only wire that should protrude past the link joints is 4-5 mm. The plastic tubing is used to cap the ends of the wires and pins. The frame is maintained as near to the link joints and clamps close to the skin as much as possible. More stability is imparted by a closer frame. Stability is further enhanced by adding an additional external rod.

CASE SERIES

Case 1

A 25-year-old male presented with a history of blunt trauma to the right hand following a punch against a wall. Physical examination revealed swelling and tenderness over the ulnar border. Radiographs confirmed a displaced fracture at the base of the fifth metacarpal. The patient underwent closed reduction and Joshi's external stabilizing system (JESS) fixation under regional anesthesia. Serial follow-ups demonstrated progressive healing. At 6 months post-operatively, the patient achieved complete clinico-radiological union with excellent grip strength and a full range of motion.

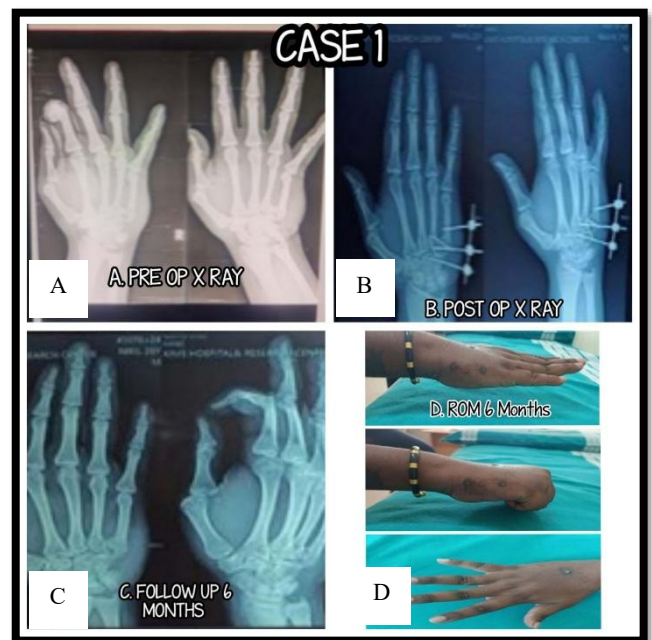


Figure 1: (A) pre-operative X-ray showing displaced fracture of the 5th metacarpal base following axial trauma, (B) post-operative radiograph demonstrating stable reduction with JESS fixator in situ and (C and D) 6-month follow-up showing bony union and optimal functional recovery.

Case 2

A 36-year-old male presented following a road traffic accident (RTA) with displaced fractures of the 4th and 5th proximal phalanges of right hand. Under regional anaesthesia, the 4th phalanx underwent K-wire fixation, while the 5th was stabilized using JESS. Serial follow-up

revealed a notable disparity in recovery: the JESS-fixed 5th phalanx achieved optimal functional outcomes at 6 months, whereas the K-wire-fixed 4th phalanx reached a comparable outcome at 9 months.

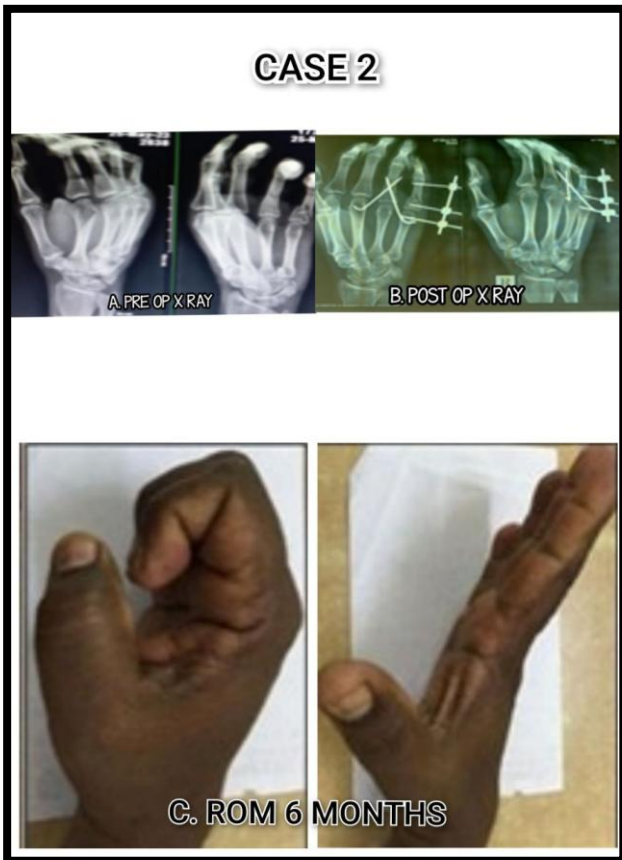


Figure 2: (A) AP and oblique views showing displaced proximal phalanx fractures of the 4th and 5th digit, (B) immediate post-op X-ray showing 4th phalanx stabilized with K-wires and 5th phalanx stabilized with JESS frame utilizing ligamentotaxis and (C) complete radiological union and full range of motion (ROM) in the 5th digit (JESS) with ongoing remodelling and persistent stiffness in the 4th digit (K-wire).

Case 3

A 56-year-old male presented following a road traffic accident with displaced fractures of the 3rd, 4th, and 5th proximal phalanges of the right hand. Under regional anaesthesia, the 3rd and 4th phalanges were stabilized with K-wires, while the 5th was managed with a JESS fixator.

Post-operative follow-up revealed that the 5th phalanx (JESS) achieved full functional recovery by the 6th month. In contrast, the 3rd and 4th phalanges (K-wire) reached comparable functional outcomes at the 9th month, likely due to prolonged stiffness associated with peritendinous adhesions.

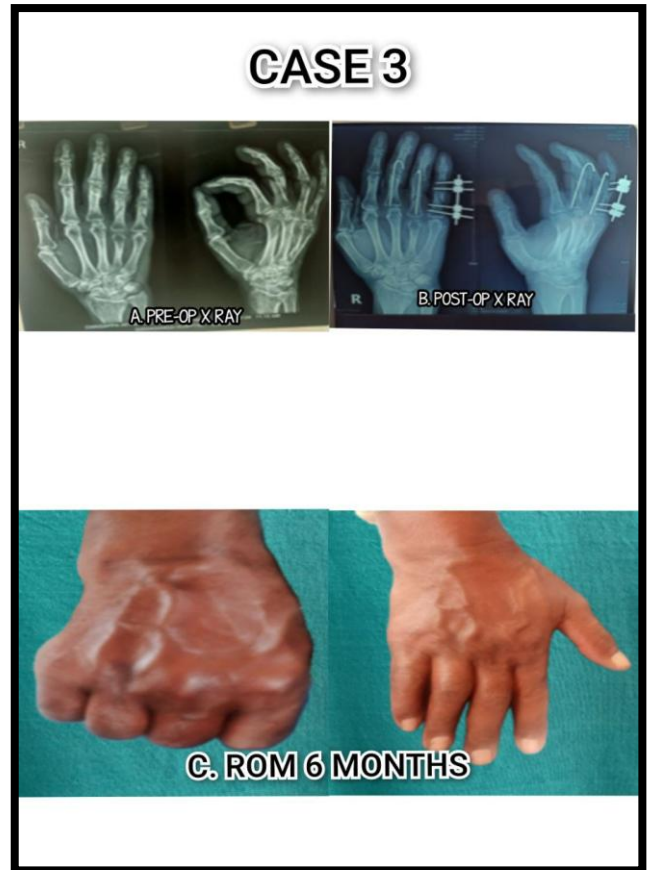

Figure 3: (A) AP and oblique views showing displaced fractures of the 3rd, 4th, and 5th proximal phalanges, (B) immediate post-operative X-ray showing K-wire fixation (3rd, 4th) and JESS frame (5th) with restored digital alignment and anatomical reduction of all three digits and (C) 6-month clinical assessment: full ROM in the 5th digit; residual stiffness in the 3rd and 4th digits.

Case 4

A 43-year-old male presented following a skid-and-fall injury to the left hand. Radiographs revealed a displaced fracture at the base of the second proximal phalanx. The patient underwent JESS fixation under regional anaesthesia to achieve stable reduction. Serial follow-up showed progressive bony union. At 6 months post-operatively, the patient demonstrated excellent functional recovery.

Figures 5 to 9 collectively illustrate the study findings, including the frequency distribution of age, which shows a peak incidence in the 3rd and 5th decades reflecting the most commonly affected working-age population, and the mode of injury, where road traffic accidents and direct trauma were identified as the predominant causes of hand fractures. The distribution of fracture types demonstrated a higher frequency of Type 1 and Type 2 injuries, which commonly required surgical stabilization. Functional outcomes assessed using the ASSH-TAF rating at 24 weeks showed that most patients achieved “Excellent”

results, indicating favourable recovery. Additionally, the frequency distribution of pin tract infection revealed a low incidence rate, highlighting the safety and effectiveness of the Joshi's External Stabilizing System (JESS).

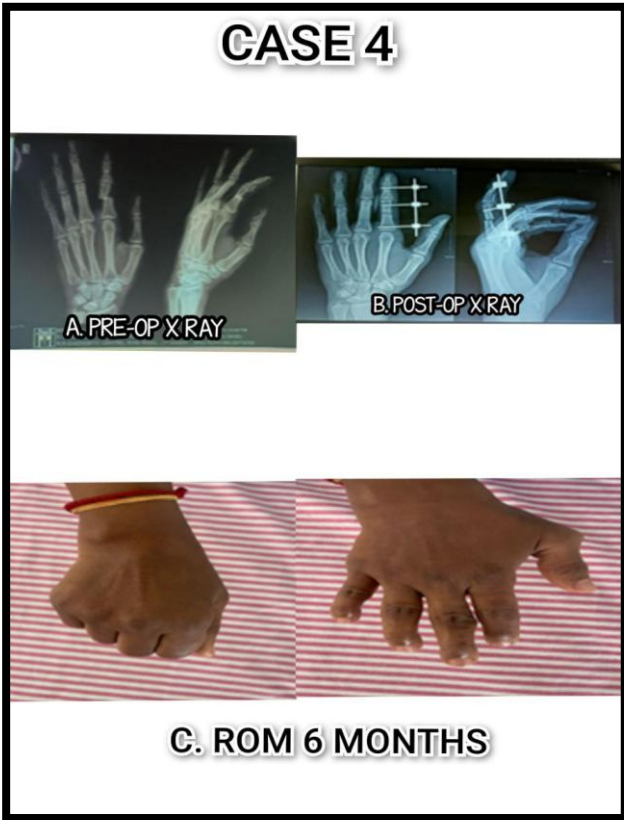

Figure 4: (A) AP and lateral views of the left hand showing displaced fracture at the base of the 2nd proximal phalanx, (B) immediate post-operative X-ray showing JESS fixator in situ providing stable distraction and alignment and (C) 6-month clinical assessment: complete clinico-radiological union of the 2nd digit with full range of motion at the MCP and IP joints of 2nd digit.

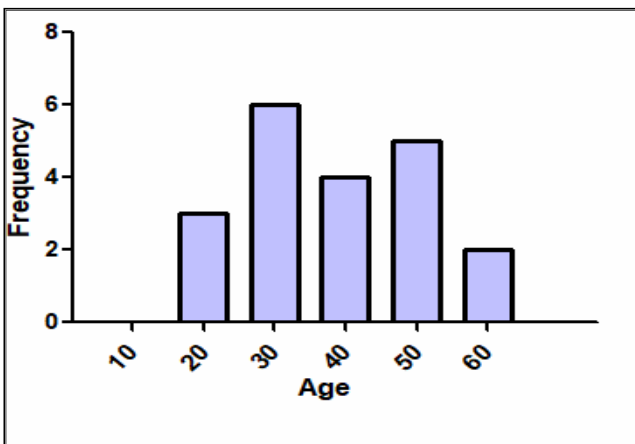


Figure 5: Frequency distribution of age.

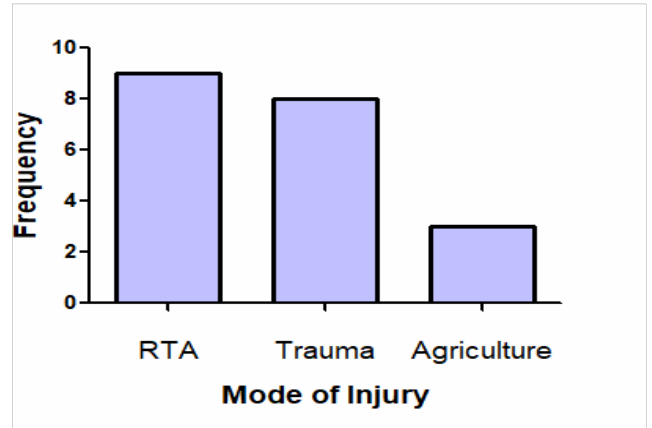


Figure 6: Frequency distribution mode of injury.

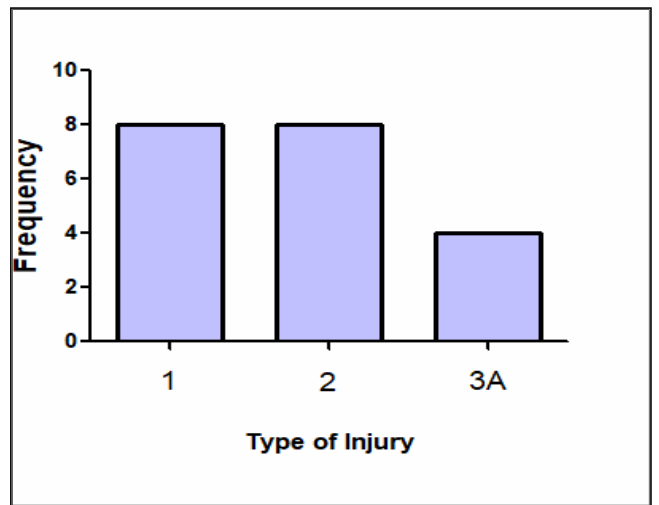


Figure 7: Frequency distribution type of fracture.

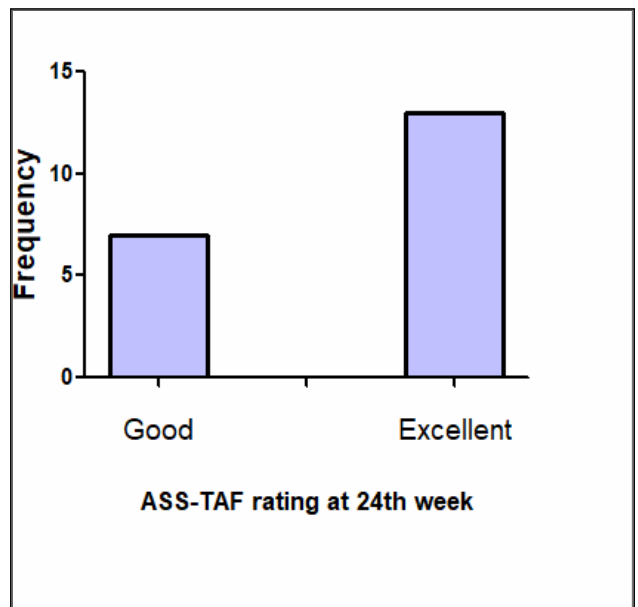


Figure 8: Frequency distribution of ASSH-TAF rating at 24th week.

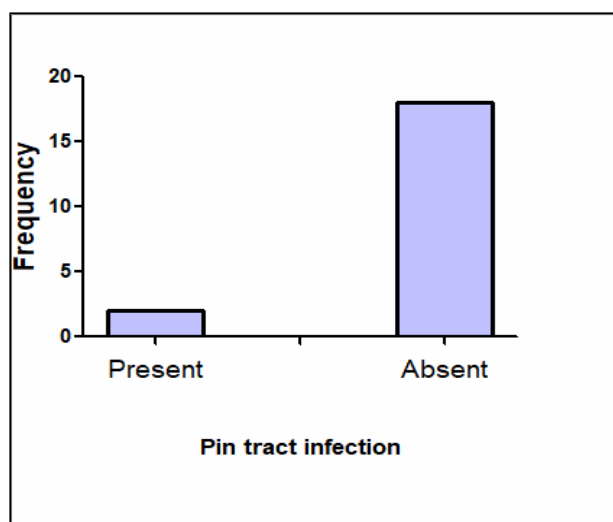


Figure 9: Frequency distribution of pin tract infection.

DISCUSSION

Age significantly impacts hand fractures, influencing both the type of fracture sustained and treatment outcomes. Younger individuals, particularly those involved in high-impact activities or sports, are more susceptible to metacarpal fractures. In our study, 45% of injuries occurred in adults aged 20-40 years, while older individuals accounted for the remaining 55%. Similarly, a study by Schuind et al. 5 found that hand fractures were most common in men aged 15-35 years, with RTA being significant cause in younger age groups and falls predominating in older adults yielded satisfactory outcomes.

In our study, male patients outnumbered female patients, with only 15% of the injuries occurring in females. Similarly, a study by Schuind et al and Parson et al revealed that males experience hand fractures at a significantly higher rate than females, with males constituting approximately 80% and 85% of all cases.^{5,11} This disparity is often attributed to males' higher participation in high-risk activities such as sports and physical labor. The study further highlighted that younger males are particularly prone to metacarpal fractures due to their involvement in vigorous activities. Conversely, females are more susceptible to fractures related to conditions like osteoporosis or falls.

In our study, 45% of hand injuries were attributed to road traffic accidents (RTAs), resulting in severe fractures, lacerations, and crush injuries often due to collisions or vehicle ejections causing complex fractures or soft tissue damage. This aligns with the findings of Salunkhe et al which highlighted the significant contribution of high-impact activities, such as RTAs, to the prevalence of hand fractures.⁷ These findings emphasize the importance of understanding the diverse causes of hand injuries to tailor personalized treatment approaches effectively.

In our comprehensive study, we examined the incidence of hand injuries and observed a significant disparity between the right and left hands. The data indicated that 65% of injuries occurred on the right hand, while 35% affected the left hand. This finding suggests a higher vulnerability or usage of the right hand in activities leading to injury. Study done by Schuind et al and Parson et al correlates with our study.^{5,8} Hand fractures are classified as either extra-articular or intra-articular based on their involvement with the joint surface. In a recent study, 70% of fractures were extra-articular, occurring outside the joint capsule and not affecting the articular surface. Conversely, 30% were intra-articular, extending into the joint surface and potentially causing joint instability or post-traumatic arthritis if not treated properly. These findings are consistent with Schuind et al and Salunkhe et al studies.^{5,7}

According to ASSH-TAF (Association for the Study of Internal Fixation Technical Commission on Standardization of Terminology of Fracture Treatment) criteria, JESS is assessed for its overall effectiveness in promoting fracture healing, preventing malunion or nonunion, and facilitating early mobilization and rehabilitation. In the present study, by the 4th week, 55% of the population achieved a fair rating, 40% a good rating, and 5% an excellent rating. By the 8th week, good ratings increased to 75%, and excellent ratings to 20%. By the 12th week, 45% were rated good and 50% excellent. By the 24th week, 65% received an excellent rating, indicating the effectiveness of JESS in recovering hand fractures. These results are consistent with the findings of an evaluation by Lee and Chen, who reported similar improvements over time with JESS treatment.⁹ Pin tract infections are a potential complication associated with external fixation devices such as JESS. These infections result from bacteria entering the skin around the pins or wires used to secure the external fixator to the bone. In our study, only 10% of the population developed pin tract infections. Early identification and prompt treatment are crucial to minimize complications. A study by Davis and Miller reported similar infection rates and emphasized the need for proper pin care to prevent infections.¹⁰ The timing for frame removal in JESS for hand fractures is determined by various factors, including the type and location of the fracture, healing progress, and individual patient considerations. In our study, 25% of the population had their frames removed within 4 weeks, 15% within 5 weeks, 50% within 6 weeks, and 5% within 8 weeks. A study by Garcia and Johnson also highlighted the importance of individualized assessment for frame removal timing to ensure optimal recovery.¹¹

CONCLUSION

This study was undertaken to assess the functional outcome of fractures of hand treated with JESS (Joshi's external stabilization system). In our study 50% excellent functional outcome at the end of 12 weeks and 65% excellent functional outcome at the end of 24 weeks which is significant improvement and in our study one patient had

pin tract infection. In our study JESS is an effective method for treating hand fractures which includes metacarpal and phalanges fractures which includes closed open, intra- articular and extra- articular fractures with majority of JESS fixators are removed within 6 weeks of time duration and 65% of fracture healing noticed at the time of frame removal.

JESS fixator is a versatile, cheap less technically demanding with small learning curve and easily available which provides adequate stability and allows early physiotherapy and ROM exercises after fixator removal provides excellent functional outcome. Overall, personalized treatment approaches, considering patient – specific factors, are essential for optimizing recovery and minimizing complications.

Funding: No funding sources

Conflict of interest: None declared

Ethical approval: Not required

REFERENCES

1. Díaz-García R, Waljee JF. Current management of metacarpal fractures. *Hand Clin.* 2013;29(4):507-18.
2. Fitoussi F, Ip WY, Chow SP. External fixation for comminuted phalangeal fractures. A biomechanical cadaver study. *J Hand Surg Br Eur Vol.* 1996;21(6):760-4.
3. Joshi BB. Percutaneous internal fixation of fractures of the proximal phalanges. *Hand.* 1976;8(1):86-92.
4. Naidu KVD. Management of metacarpal and phalangeal fractures with JESS fixator: A prospective study. *Int J Orthop Sci.* 2018;4(1):383-7.
5. Schuind F, Donkerwolcke M, Burny F. External minifixation for treatment of closed fractures of the metacarpal bones. *J Orthop Trauma.* 1991;5(2):146-52.
6. Gudmundsen TE, Borgen L. Fractures of the fifth metacarpal. *Acta Radiol.* 2009;50(3):296-300.
7. Salunkhe RM, Joshi H, Pisal TK, Biswas SK, Patel JJ, Singh A. A prospective study of dynamic treatment of fracture phalanx and metacarpals of the hand with Kirschner-wire fixation/external fixator and finger splint: daycare management (30 cases). *Med J Dr DY Patil Univ.* 2016;9(6):708-13.
8. Parsons SW, Fitzgerald JA, Shearer JR. External fixation of unstable metacarpal and phalangeal fractures. *J Hand Surg Br Eur Vol.* 1992;17(2):151-5.
9. Shah D. Functional outcome of fracture of metacarpals and phalanges managed with JESS fixator. *Int J Orthop Traumatol Surg Sci.* 2019;5(2):176-82.
10. Meals RA, Meuli HC. Carpenter's nails, phonograph needles, piano wires, and safety pins: the history of operative fixation of metacarpal and phalangeal fractures. *J Hand Surg Am.* 1985;10(1):144-50.
11. Tennant CE. Use of steel phonograph needle as a retaining pin in certain irreducible fractures of the small bones. *JAMA.* 1924;83:193.

Cite this article as: Ravish VN, Raju BG, Yadrami SP. Functional outcome of fractures of the hand treated with JESS (Joshi's external stabilization system). *Int J Res Orthop* 2026;12:1082-7.