

Original Research Article

Flexible intramedullary nails: the panacea for paediatric femoral shaft fractures

Jagdeep Singh¹, Jagandeep S. Virk^{2*}, Anoop Kalia¹, Naveen Mittal²

Department of Orthopaedic Surgery, ¹GGSMCH, Faridkot, Punjab, India; ²GMCH, Chandigarh, India

Received: 01 April 2017

Accepted: 15 April 2017

***Correspondence:**

Dr. Jagandeep S. Virk,

E-mail: jaganvirk_09@yahoo.co.in

Copyright: © the author(s), publisher and licensee Medip Academy. This is an open-access article distributed under the terms of the Creative Commons Attribution Non-Commercial License, which permits unrestricted non-commercial use, distribution, and reproduction in any medium, provided the original work is properly cited.

ABSTRACT

Background: Management of pediatric femoral shaft fractures continues to evolve with time with flexible intramedullary nailing being one of the options to treat a specific age group of children. Grey zone exists concerning the cost effectiveness and appropriate timing of nail removal in treating such fractures. The objective of the study was to evaluate the treatment outcome of fracture shaft of the femur in children in the age group of 5- 12 years with flexible intramedullary nail.

Methods: The study comprised of 30 consecutive cases of acute fractures of the femoral shaft in children of the age group of 5 to 12 years. Only closed fractures of the mid-diaphyseal region of the femur were included while supracondylar, subtrochanteric and pathological fractures were excluded. Flexible intramedullary nails of stainless steel (n=24) or titanium (n=6) were used for fixation of these fractures.

Results: Evaluation of the results was done according to the criteria by Flynn et al. 21(70%) out of 30 patients had an excellent result and remaining 9 (30%) had a satisfactory result. All fractures united with a full range of motion at the hip and knee joint without any major complications.

Conclusions: Intramedullary elastic nailing of simple diaphyseal femur fractures in children is an effective method with negligible complications. Treatment cost can be significantly lowered by using the much cheaper stainless steel flexible nails rather than the more expensive titanium nails.

Keywords: Femur, Elastic nails, Reduction, Union

INTRODUCTION

Fracture shaft of the femur is one of the most common fractures encountered in orthopedic practice. The average rate of fracture shaft of the femur in children is 19.15/100000 population per year with a preponderance in boys.¹ Common causes of fracture shaft of the femur in children are falling from height and accidents.

Not many years ago the use of traction and application of hip spica cast were standard treatments for all femoral shaft fractures in children.² However, the management of femoral shaft fractures in children above the age of five years has tilted more towards an operative option in the last two decades attributed to low incidence of malunion,

short hospital stays, cost effectiveness and early ambulation.³

Use of locked intramedullary nail fixation in skeletally mature children is not debatable. But the use of a variety of surgical implants for the age group of 5 to 12 years is still a grey area which includes plates, external fixators and flexible intramedullary nails, the latter having some advantages over the former two methods.⁴⁻⁶ Our method of treatment was fixation by flexible intramedullary nails of stainless steel or titanium which can be performed either by the antegrade or retrograde method. This surgical procedure is technically simple, time-saving and can be done in a closed manner.

Two divergent flexible intramedullary nails (FIN) provide three point fixation and stability in femoral shaft of children and adolescents.⁷ The major advantage of FIN is in healing with abundant callus, attributed to non-rigid fixation resulting in rapid fracture union and early return to function.⁸ Closed reduction and fixation of fracture lead to an early union as fracture hematoma is not disturbed.

The study was aimed at studying the clinical, radiological and functional outcome with flexible nails in the treatment of femoral shaft fractures in children aged between 5 and 12 years.

METHODS

This is retrospective study of prospectively collected data. The patients included in study were those operated from January 2008 to December 2014 which comprised of 30 consecutive cases of fresh diaphyseal fracture of the femoral shaft which were of closed type in children up to the age of 5 to 12 years at the first author's institute. A complete examination of all the patients with such fractures was done both clinically, radiologically and a brief history of the patient was recorded. Any associated injury was managed accordingly. The thickness of the elastic nail to be used in a particular patient was determined according to the size of the medullary canal of the femur. To determine the size of the elastic nails, the femoral diaphyseal internal diameter was measured on both antero-posterior and lateral radiographs and was divided by 2 and 0.5 mm was subtracted from that calculation for the eventual nail diameter as determined by Kasser and Beaty.⁹ The surgery was performed under general anesthesia with the patient on a radiolucent table in supine position. The nails were inserted in a retrograde fashion with medial and lateral entries 2.5 cm above the physis under image intensifier control till the fracture site was reached. The fracture was reduced by manipulation and traction under image intensifier control. The fracture was reduced and the nails were pushed into proximal fragment. Subsequently, the two nails were pushed into the proximal end of the femur so that the tip of the nail that entered from the lateral side directed towards trochanteric apophysis and the medial side nail pointing towards the calcar region of the femoral neck. Distally the nail was cut so that 1 cm of nail remained outside the cortex. The extra osseous portion of the nail was bent slightly away from the bone for easy removal after fracture union. Post-op x-rays were taken next day. Quadriceps exercise and movement of adjacent joints was started as soon as the patient was comfortable. Sutures were removed on 12th postoperative day.

Follow-up of the patients was done at 3 weekly intervals till union occurred (Figure 1 and Figure 2). Both clinical and radiological examinations were done at each visit. The patient was allowed partial weight bearing approximately 4 weeks to 6 weeks postoperatively

depending on fracture configuration and patient tolerance.

Final evaluation of the results was done according to the criteria laid down by Flynn et al (2001) as shown in Table 1.⁴

Table 1: Flynn criteria (2001).

	Excellent	Satisfactory	Poor
Limb length inequality	<1cm	<2cm	>2cm
Mal-alignment	Up to 5°	5-10°	10°
Pain	None	None	Present
Compliance	None	Minor	Major complication and/or lasting morbidity

RESULTS

Most of the patients i.e. 17 out of 30 (56.7%) were belonging to the age group of 5-7 years. Males were more commonly involved as compared to females in this study with the ratio being 2:1 in favor of males (Figure 1). The majority of the children had an injury due to roadside accidents in 20 cases (66.6%) followed by fall from height in 7 cases (23.4%) and fall while playing in 3 cases (10%) (Figure 2). Right side limb (66.6%) was involved more as compare to left limb (33.4%). The most common fracture pattern seen was the transverse fracture recorded in 28 cases (93.3%) followed by the oblique fracture seen in 2 cases (6.7%) (Table 2). Most of the fractures occurred in middle 1/3 region of the femur (93.3%) followed by upper 1/3 (6.7%) (Table 3).

The average stay in hospital in days was 11.4 days with the shortest stay of 8 days and longest stay of 26 days. 5 patients (16.6%) sustained associated injury along with fracture shaft femur. These associated injuries did not affect the final outcome of treatment. Most of the fractures united with the average period of 9.6 weeks (Figure 3).

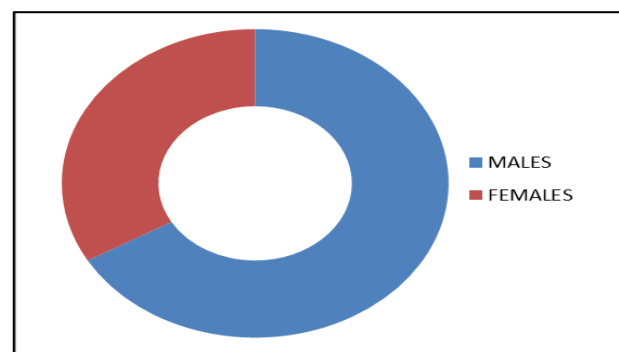


Figure 1: Gender distribution of the patients.

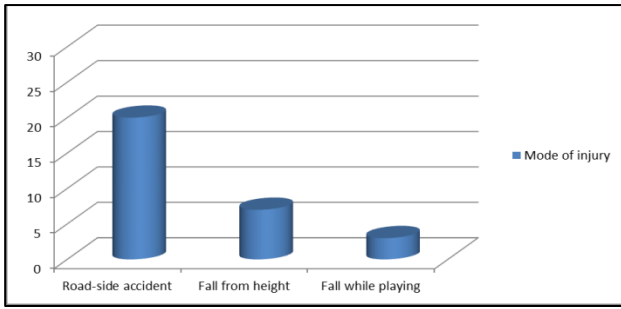


Figure 2: Distribution of patients according to the mode of injury.

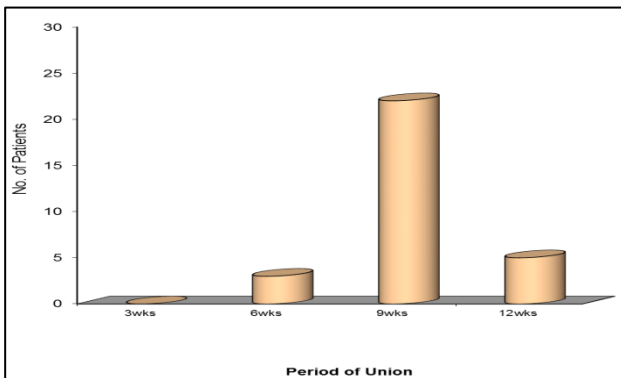


Figure 3: Graph showing duration to radiological union in all cases.

Table 2: Type of fracture.

Type of fracture	No. of cases	%
Transverse	28	93.3
Oblique	2	6.7
Spiral	0	0
Comminuted	0	0
Segmental	0	0
Total	30	100

Table 3: Site of fracture.

Site of fracture	No of cases	%
Upper 1/3	2	6.7
Middle 1/3	28	93.3
Lower 1/3	0	0
Total	30	100

Nine patients (30%) had minor complications out of which 7 patients (77.8%) had nail protrusion and focal infection followed by quadriceps wasting developing in 4 cases out of these 7 cases and knee stiffness developed in 2 cases (22.2%). All these complications were temporary which were controlled over a period of time. No major complications like nonunion, septic arthritis and deep soft tissue infection were encountered in this study. Limb length discrepancy had occurred in 6 patients (20%) out of which lengthening was more common in 5 patients (16.6%) out of which 3 patients (60%) had 0.5 cm

lengthening and 2 patients (40%) had a lengthening of 1cm. Shortening of 0.5 cm was only seen in 1 patient (3.4%). Two patients had malunion in the form of 5 degrees anterior angulation in one patient and the second patient had 5 degrees of lateral angulation. This angulation being less than 10 degrees was not of much clinical significance.

Implant removal was done in all the patients post-operatively at an average period of 8.37 months (Table 4).

Table 4: Time of implant removal.

Time of implant removal after surgery	No of patients	%
Upto 6 months	6	20
Within 7-12 months	23	76.7
Beyond 12 months	1	3.3
Total	30	100

The evaluation of the results according to the criteria laid down by Flynn et al, we concluded that 21 (70%) out of 30 patients had excellent result, while 9 (30%) out of 30 had satisfactory result. There was no patient who had a poor result (Table 5).

Table 5: Results.

Results	No of patients	%
Excellent	21	70
Satisfactory	9	30
Poor	0	0
Total	30	100

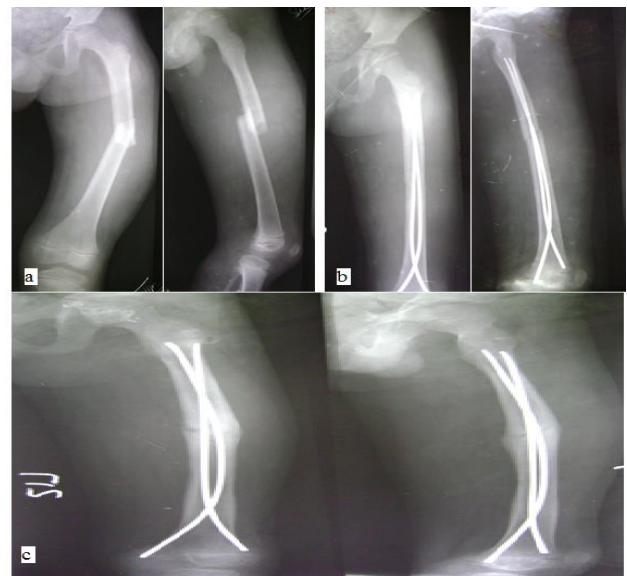


Figure 4: (a) Shows 6 year old male with mid-shaft, transverse fracture of the femur, (b) shows immediate postoperative X- rays, (c) shows good callus formation at 3 months post-op.

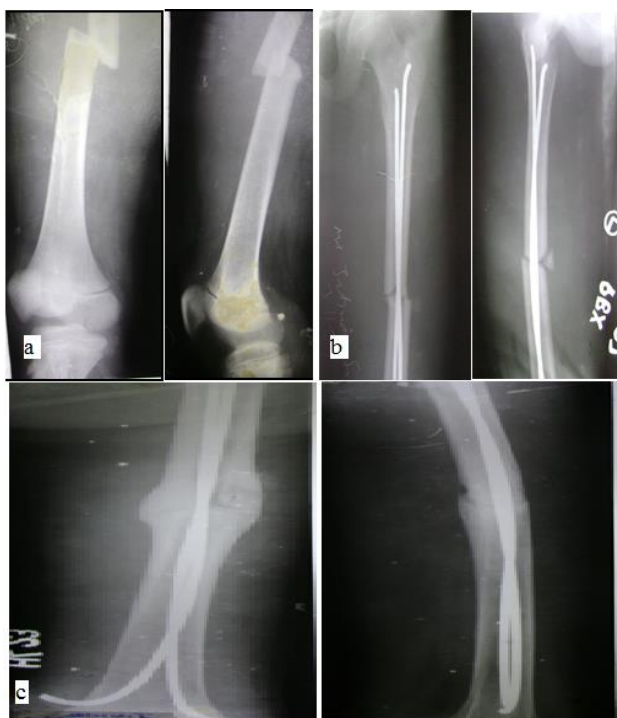

Figure 5: (a) Pre-op X-ray of a 10 years old child showing mid-shaft transverse fracture femur, (b) immediate post-op X-rays, (c) 6 weeks follow up X-ray showing good callus formation and union.

DISCUSSION

Pediatric femoral shaft fractures are one of the common major pediatric injuries managed by the orthopedic surgeon in emergency. The femoral shaft fractures in adults are mostly treated by surgical methods while in pediatric cases mainly conservative methods are adopted due to better acceptance by parents and children.¹⁰ The flexible intramedullary nail (FIN) also known as elastic stable intramedullary nails (ESIN) are ideal for pediatric femoral shaft fractures due to their ease of use and preventing complications associated with casting and traction required in a conservative method. Literature is flooded with number of studies which consider it as the safe and best method, in the management of patients with age group of 5-12 years.¹¹⁻¹³

External fixation is recommended only for open and severely comminuted fracture.⁵ Rigid intramedullary nailing like rush nailing, interlocking nails provides good results but it can damage the blood supply to the femoral head resulting in AVN (avascular necrosis) or cause growth arrest at the greater trochanter resulting in coxa valga. However, there have been proponents for using interlocking nail in the 11-16 years of age group, avoiding the piriformis fossa as entry site, with good results.¹⁹

Compression plating is associated with extensive soft tissue dissection for opening, reduction, fixation of

fracture and requires a similar major operation for removal.¹⁵

Ideal treatment for fracture shaft of the femur is one which controls length, alignment, rotation along with providing angular stability to the fracture. Our method of treatment fulfills these requirements effectively and our results are similar to previous done studies. One such study emphasized that titanium elastic nail is superior in terms of union, scar acceptance, and overall patient satisfaction compared to traction and casting.¹² Similarly, another study documented good functional outcomes in 79 femoral fractures managed with flexible intramedullary nails.¹⁶

The transverse fracture was the most common type of fracture pattern seen in our study as well as in the other previous study.^{17,18} This is due to the fact that at the time injury, the patient might have suffered direct impact and axial loading. Literature also showed that mid-shaft femur is the commonest site of fracture in children.¹⁷ It could be due to gentle anterior curve in the shaft of the femur in middle 1/3 where the force gets concentrated during the injury.

Average hospital stay of patients was 11.4 days in this study which is comparable with other studies.^{19,20} A comparative concluded that mean hospital stay was lower in operative group with an average only 15 days as compare to average 29 days in non-operative group.²⁰ This decreased hospitalization time has a definite advantage of operative management in children over conservative treatment.

In this study average period for radiological union was 8.5 weeks which almost coincides with the union results of other studies with no significant stiffness at the knee and hip joint was noted in cases at their last follow-up.^{13,21} This is primarily due to early mobilization of the patient which can be initiated as compared to other conservative treatments.

We have used stainless steel elastic nails in 24 patients and titanium elastic nails in 6 patients. Most of the patients coming to our hospital were from nearby villages and belonged to a lower socio-economic status with affordability being an issue. Stainless steel nails are much cheaper, almost one third the cost of titanium nails. On reviewing the literature there seems to be a divide on which type of nail is better. One such study described biomechanical properties of titanium and emphasized that due to lower modulus of elasticity, these nails are often considered to be superior to the much stiffer stainless steel nails for intramedullary fracture fixation attributed to better fracture stability on torsional and axial compression testing. However, all these studies were done in-vitro.²²

In contrast to this another study recommended the use of stainless steel when fixing paediatric femoral shaft

fractures as these nails provide a rigid construct due to stiffer in nature and gives good stability as well as prevent deformity at fracture site than their titanium counterpart.²³ An increased incidence in complications rate has been documented by observers as the weight and age of patient progresses with use of titanium nails.²⁴

Few studies indicated that the cheaper stainless steel elastic nails are clinically superior to titanium nails for pediatric femoral fixation primarily because of a much lower rate of malunion²⁵ and provide good, cheap alternative to these expensive nails.²⁶ A more careful insertion technique is all that is required in stainless steel nails as compared to the titanium nails due to the inadvertent danger of perforating the second cortex with these much stiffer implants.

All our patients had implant removal after fracture union at the end of one year follow up. However, this practice has been questioned in a retrospective study involving 25 fractures treated with Titanium elastic nailing system (TENS) concluding that the survivorship free of revision due to persistent pain was 72% at 5 years of follow-up. No significant difference was seen in residual symptoms of pain among those who underwent nail removal or those who didn't.²⁷ Literature is not on clear consensus about the duration of implant removal, however most of the authors have recommended implant removal after fracture union between 6 months to one year.²⁸⁻³⁰ Even in our study only 7 patients had early implant removal due to superficial infection and nail protrusion. Rest of the patient had implant removal between 6 to 12 months. We did not make any specific protocol of implant removal, it was primarily due to the parents apprehension regarding the implants in their child's limb which pushed us to remove the implants in 23 patients having no complaints after fracture union. This observation has definitely raised a question on the cost effectiveness of flexible nails for which further studies need to be done. One study documented that it is possible to remove nails 3 months after surgery and in literature nails have been removed as early as 6 weeks because of adequate union at fracture site by that period. However, the nail should only be removed when the fracture has become consolidated because there have been reports of re-fracture in cases of early removal of nails.³

Nail protrusion and local infection was most common problem encountered in this study. Review of these cases showed in these cases nails were protruding out and excessively bent. All the patients were relieved of symptoms on removal of nails and skin ulceration required trimming under anesthesia. These problem can be prevented by avoiding the too much bending of nail ends and by leaving the only 1cm of nail end outside the bone ensuring its approximation against the supracondylar flare of the femur. A similar study described that there was an association between the prominence and skin erosion and nail pain.³¹ Nail ends near the knee caused limitation in last 30 degrees of knee

flexion in 2 patients in our study which on further analysis was related to nails cut too long and excessively bent at the ends with complete relief on removal of nails post fracture union. There is no incidence of major complications like nonunion, deep infection, re-fracture, physeal arrest which is backed by many other similar studies.^{17,32,33}

Lengthening was common in patients treated with FIN as compared with shortening mainly because hyperemia of femoral physis and eventually stimulation of growth plate which causes lengthening of limb in such patients.^{17,28}

The study was limited by restricting it to the functional outcomes of flexible nails only, with no exact correlation to its cost effectiveness. Further studies are to be conducted by comparing the cost effectiveness of operative treatment with flexible nails and conservative treatment.

CONCLUSION

Intramedullary flexible nails are an effective method for treatment of femoral shaft fractures in a clearly selected patient age group of 5 to 12 years. It has negligible complications but still, there are certain questions regarding cost effectiveness which remain unanswered as a second surgery is required to remove the nails mainly due to the apprehension and anxiety of parents of the children. However, the cost of treatment can be significantly lowered by using the much cheaper stainless steel flexible nails rather than the more expensive titanium nails, since there was not much difference in the clinical, radiological and functional outcome between the two implant materials. Further studies are required to be done for the same.

Funding: No funding sources

Conflict of interest: None declared

Ethical approval: The study was approved by the institutional ethics committee

REFERENCES

1. Hinton RY, Lincoln KA, Crockett MM, Sponseller P, Smith G. Fracture of the femoral shaft in children. Incidence, mechanism and socio-demographic risk factors. *J Bone Joint Surg (Am)*. 1999;81:500-9.
2. Buckley SL. Current trends in the treatment of femoral shaft fractures in children and adolescents. *Clin Orthop Relat Res*. 1997;338:60-73.
3. Flynn JM, Hresko T, Reynolds RA, Blasler RD, Davidson R, Kasser J. Titanium elastic nails for pediatric femur fractures: a multicenter study of early results with analysis of complications. *J Pediatr Orthop*. 2001;21:4-8.
4. Kanlic EM, Anglen JO, Smith DG, Morgan SJ, Pesántez RF. Advantages of submuscular bridge plating for complex pediatric femur fractures. *Clin Orthop Relat Res*. 2004;426:244-51.

5. Wright JG, Wang EE, Owen JL, Stephens D, Graham HK, Hanlon M, et al. Treatments for paediatric femoral fractures: a randomised trial. *Lancet.* 2005;365(9465):1153-8.
6. Salem KH, Lindemann I, Keppler P. Flexible intramedullary nailing in pediatric lower limb fractures. *J Pediatr Orthop.* 2006;26(4):505-9.
7. Lee S, Mahar AT, Newton PO. Ender nail fixation of pediatric femur fractures a biomechanical analysis. *J Pediatr Orthop.* 2001;21(4):442-5.
8. Yamaji T, Anodo K, Nakamura T, Washimi O, Terada N, Yamada H. Femoral shaft fracture callus formation after intramedullary nailing a comparison of interlocking and Ender nailing. *J Orthop Sci.* 2002;7(4):472-6.
9. Kasser JR, Beaty JH. Femoral shaft fractures. In: Rockwood and Wilkins Fractures in Children. 5th ed. New York: Lippincott Williams and Wilkins; 2001: 941-980.
10. Flynn JM, Skaggs DL, Sponseller PD, Ganley TJ, Kay RM, Leitch KK. The surgical management of paediatric fractures of the lower extremity. *Instr Course Lect.* 2003;52:647-59.
11. Flynn JM, Luedtke LM, Ganley TJ, Dawson J, Davidson RS, Dormans JP, et al. Comparison of titanium elastic nails with traction and a spica cast to treat femoral fractures in children. *J Bone Joint Surg Am.* 2004;86(4):770-7.
12. Buechsenschuetz KE, Mehlman CT, Shaw KJ, Crawford AH, Immerman EB. Femoral shaft fractures in children: traction and casting versus elastic stable intramedullary nailing. *J Trauma Acute Care Surgery.* 2002;53(5):914-21.
13. Oh CW, Park BC, Kim PT, Kyung HS, Kim SJ, Ihn JC. Retrograde flexible intramedullary nailing in children's femoral fractures. *Int Orthop.* 2002;26(1):52-5.
14. Buford D, Christensen K, Weather P. Intramedullary nailing of femoral fractures in adolescents. *Clin Orthop Relat Res.* 1998;350:85-9.
15. Caglor O, Aksoy MC, Yazici M, Surat A. Comparison of compression plate and flexible intramedullary nail fixation in pediatric femoral shaft fractures. *J Pediatr Orthop.* 2006;15(3):210-4.
16. Narayanan UG, Hyman JE, Wainwright AM, Rang M. Complications of elastic stable intramedullary nail fixation of pediatric femoral fractures and How to avoid them. *J Pediatr Orthop.* 2004;24:363-9.
17. Ozturkmen Y, Doqural C, Balioglu MB, Karli M. Intramedullary stabilization of diaphyseal fracture of femur with elastic Ender nails. *Acta Orthop Traumatol Turc.* 2002;36(3):220-7.
18. Rathjen KE, Riccio AI, De La Garza D. Stainless steel flexible intramedullary fixation of unstable femoral shaft fractures in children. *J Pediatr Orthop.* 2007;27(4):432-41.
19. Bopst L, Reinberg O, Lutz N. Femur fracture in preschool children: experience with flexible intramedullary nailing in 72 children. *J Pediatr Orthop.* 2007;27(3):299-303.
20. Reeves RB, Ballard RI, Hughes JL, Jackson. Internal fixation versus traction and casting of adolescent femoral shaft fractures. *J Pediatr Orthop.* 1990;10:592-5.
21. Gogi N, Khan SA, Varshney MK. Limb length discrepancy following titanium elastic nailing in paediatric femoral shaft fractures. *Acta Orthop Belg.* 2006;72(2):154-8.
22. Mahar A, Lee S, Lalonde F, Impelluso T, Newton P. Biomechanical comparison of stainless steel and titanium nails for fixation of simulated femoral fractures. *J Pediatr Orthop.* 2004;24(6):638-41.
23. Kanlic EM, Anglen JO, Smith DG, Morgan SJ, Pesántez RF. Advantages of submuscular bridge plating for complex paediatric femur fractures. *Clin Orthop Relat Res.* 2004;426:244-51.
24. 24. Beaty JH, Kasser JR. Rockwood and Wilkins' Fractures in Children. 6th edition. Philadelphia, PA: LWW; 2006.
25. Wall EJ, Jain V, Vora V, Mehlman CT, Crawford AH. Complications of titanium and stainless steel elastic nail fixation of pediatric femoral fractures. *J Bone Joint Surg (Am).* 2008;90(6):1305-31.
26. Ríos AU, Arango DF, Molina CO, Posada AD. Femoral shaft fractures treated with stainless steel flexible nails in children aged between 5 and 12 years at the HUSVP: a two-year follow-up. *J Children's Orthop.* 2009;3(2):129-35.
27. Morshed S, Humphrey M, Corrales LA, Millett M, Hoffinger SA. Retention of flexible intramedullary nails following treatment of pediatric femur fractures. *Arch Orthop Trauma Surg.* 2007;127(7):509-14.
28. Heybeli M, Muratl HH, Celebi L, Gulcek S, Bicimoglu A. The results of intramedullary fixation with titanium elastic nails in children with femoral fractures. *Acta Orthop Traumatol Turc.* 2004;38(3):178-87.
29. Jalan D, Chandra R, Sharma VK. Results of titanium elastic nailing in paediatric femoral diaphyseal fractures report of 30 cases. *Chinese J Traumatol.* 2013;16(2):77-83.
30. Haushian S, Gothgen CB, Pedergem NB, Haring S. Femoral shaft fracture in children treated with ESIN in 31 cases. *Acta Ortho Scand.* 2004;75(3):249-51.
31. Luhmann SJ, Schootman M, Schoenecker PL, Dobbs MB, Gordon JE. Complications of titanium elastic nails for pediatric femoral fracture. *J Pediatr Orthop.* 2003;24(4):443-7.
32. Jubel A, Andermahr J, Isenberg J, Schiffer G, Prokop A, Rehm KE. Experience with elastic stable intramedullary nailing (ESIN) of shaft fractures in children. *Der Orthopade.* 2004;33(8):928-35.
33. Herndon WA, Mahnken RF, Yngve DA, Sullivan JA. Management of femoral shaft fractures in the adolescent. *J Pediatric Orthop.* 1989;9(1):29-32.

Cite this article as: Singh J, Virk JS, Kalia A, Mittal N. Flexible intramedullary nails: the panacea for paediatric femoral shaft fractures. *Int J Res Orthop* 2017;3:411-6.