

Original Research Article

Tuberculosis of calcaneum: a case series and review of literature

Anurag Tiwari^{1*}, Nishit Bhatnagar², Yugal Karkhur², Ammar Aslam³,
Amit Sharma², Dhananjaya Sabat²

Department of Orthopaedics, ¹All India Institute of Medical Sciences, Bhopal, Madhya Pradesh, ²Maulana Azad Medical College, ³Jamia Hamdrad University, New Delhi, India

Received: 20 April 2017

Revised: 01 May 2017

Accepted: 04 May 2017

***Correspondence:**

Dr. Anurag Tiwari,

E-mail: dranurag.tiwari@gmail.com

Copyright: © the author(s), publisher and licensee Medip Academy. This is an open-access article distributed under the terms of the Creative Commons Attribution Non-Commercial License, which permits unrestricted non-commercial use, distribution, and reproduction in any medium, provided the original work is properly cited.

ABSTRACT

Background: The purpose of this study was to review the cases of isolated tuberculous osteomyelitis of calcaneum in terms of clinical features, radiological features, treatment and outcome.

Methods: Medical records of 9 patients (7 males and 2 females) aged 4 to 45 years (mean 21.33 years) who presented with isolated calcaneal tuberculous osteomyelitis were reviewed. Clinical features, laboratory tests result, findings of imaging modalities, and histopathological examination were noted. The location of involvement of tuberculosis and treatment offered were noted. Multifocal tuberculosis and articular involvement were excluded.

Results: All patients presented with pain and swelling around the heel; three of them presented with a discharging sinus. Patients had involvement of calcaneal body (n=5), tuberosity (n=2), and anterior process (n=2). The erythrocyte sedimentation rate of all patients was elevated. All the patients were treated conservatively with immobilization and chemotherapy.

Conclusions: Isolated calcaneal tuberculosis is rare and the prognosis with non-operative treatment is good.

Keywords: Tuberculosis, Osteomyelitis, Calcaneum, Isolated

INTRODUCTION

In spite of recent strides in the fight against tuberculosis (TB), it still remains a major public health problem in south Asia. Tuberculosis has the propensity to involve virtually any organ, tissue or bone in the body. Only 2% of all the cases of tuberculosis are accounted for by osteoarticular TB.¹ Of these osteoarticular TB, less than 10% are localized in the foot and ankle.² Tuberculosis of the calcaneus can have varied presentation and can be mimicked by other heel pathologies. This coupled with a lack of awareness on the part of the surgeon often delays the diagnosis and can hence lead to an unsatisfactory clinical outcome and residual functional disability.³ Even after a thorough literature search we could find only a handful of case reports and only two case series describing this rare clinical condition.

METHODS

The medical records of nine patients (7 males and 2 females), aged between 4 to 45 years, who were diagnosed with isolated calcaneal tuberculosis (right –4 and left –5) between March 2010 and July 2015, were reviewed. Diagnosis had been confirmed by cytological (Ziehl-Neelsen staining) or histopathological examination (core biopsy or open biopsy) or cartridge based nucleic acid amplification test (CBNAAT). Multifocal tuberculosis and adjacent joint involvement were excluded from the study. Radiographs anteroposterior and lateral view of affected heel (Figure 1) was done on day 1 and repeated every 3 months. Magnetic Resonance Imaging (MRI) was performed to look for the extent of destruction, collection or joint involvement (Figure 2).

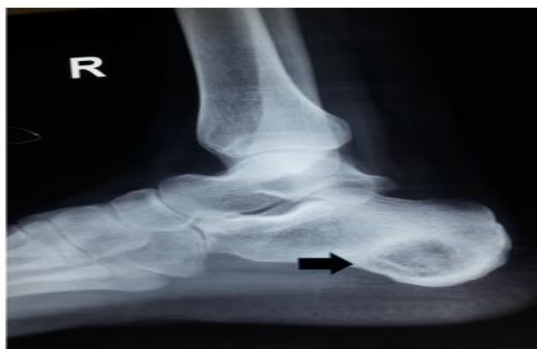

Figure 1: Lateral view radiograph of ankle before starting the treatment. Black arrow in the image showing a well-defined pure osseous lytic lesion in the body of calcaneum.

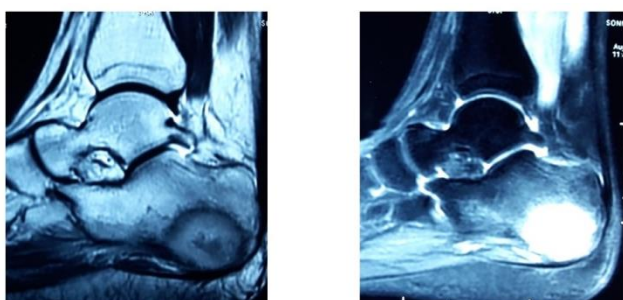


Figure 2: MRI sagittal view T1 and T2 weighted image of same patient showing the hypointense on T1 and hyperintense lesion on T2 in the centre of body of calcaneum.

All of the clinical notes, laboratory tests result, findings of imaging modalities, and histopathological examination, were noted. The location of involvement of tuberculosis and treatment offered, including chemotherapy and surgical intervention when applicable was noted. The clinical and radiological evaluation at the final follow-up visit was recorded.

All patients were managed non-operatively with anti-tubercular chemotherapy. Anti-tubercular therapy comprised of an intensive and continuation phase. During intensive phase the following drugs were given for a period of 2 months, isoniazid, rifampicin, pyrazinamide, and ethambutol. In continuation phase, isoniazid and rifampicin was continued for 10-16 months depending on clinical and hematological response. Below knee slab was applied to all patients in the first 6 weeks of starting anti tubercular therapy. Patients were also advised crutches assisted non-weight bearing ambulation to offload the heel during first 6 weeks of chemotherapy. After 6 weeks, partial weight bearing was allowed, and was gradually shifted to full weight bearing ambulation depending on pain tolerance.

Surgical intervention was reserved for patients with severe bone destruction or presence of abscess. The aim

of the treatment was to control the disease activity and to obtain a supple, painless and near normal weight bearing foot. The disease was labelled as healed when the local and systemic symptoms disappeared, along with radiological evidence of osteosclerosis, obliteration of cavities, and restoration of trabeculae.

RESULTS

The presenting symptoms in all the patients were pain and swelling around the heel, along with the ‘heel up’ sign. In addition, three patients had discharging sinuses (Figure 3). History of fever, loss of appetite and weight loss was present in the two female patients only. History of trauma to the heel was given by three patients. Inguinal lymphadenopathy was found in five patients. Delay between onset of symptoms and definitive diagnosis ranged from 1 month to 14 months. Past history of tuberculosis was present in one patient. All patients were found to be immunocompetent. ESR was raised in all patients at time of diagnosis (mean 57; range 46 – 74 mm in first hour).

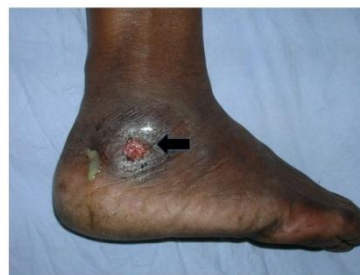

Figure 3: Clinical photograph of foot and ankle of a patient. Black arrow showing a discharging sinus over the lateral aspect of heel.

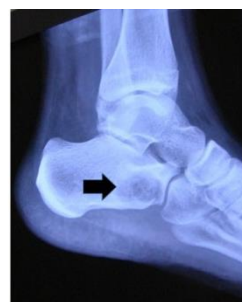

Figure 4: Lateral view radiograph of ankle showing the involvement of anterior process of the calcaneum, as shown by the arrow in image.

Radiographic imaging revealed involvement of body of calcaneus in 5 patients, tuberosity in 2 patients and 2 patients had involvement of anterior process (Figure 4). The demographic data, presenting symptoms, laboratory test results of all the patients were tabulated in Table 1.

The mean follow-up period was 26.1 months (range: 12 months to 48 months). All patients responded to ATT and

disease healed. Significant heel varus deformity was sequelae in one patient. In one patient, who had past history of tuberculosis, intensive phase was given for 3

months, which included Streptomycin (0.75 gm) for the first 2 months in addition to the above mentioned drugs.

Table 1: Details of all the patients included in the study.

S. No	Age(in years)	Gender	Side	Involved part	Presentation	Diagnosis	Treatment	Outcome	Follow up
1	40	M	Left	Body	Pain Swelling	Biopsy	ATT ^s	Healed with heel varus deformity	48 months
2	15	F	Left	Anterior process	Pain Swelling	Biopsy	ATT	Healed	48 months
3	45	M	Left	Body	Sinus	CBNAAT*	ATT	Healed	48 months
4	24	F	Right	Body	Pain Swelling	Biopsy	ATT	Healed	18 months
5	11	M	Left	Calcaneal Apophysis (Tuberosity)	Pain Swelling	Biopsy	ATT	Healed	17 months
6	20	M	Right	Tuberosity	Pain and bump	Biopsy	ATT	Healed	17 months
7	4	M	Left	Body	Sinus	ZN staining	ATT	Healed	15 months
8	7	M	Right	Body	Sinus	ZN staining	ATT	Healed	12 months
9	26	M	Right	Anterior process	Pain Swelling	Biopsy	ATT	Healed	12 months

Patients were able to resume full weight bearing ambulation after a mean period of 12 weeks (8 weeks to 18 weeks). In the three patients with sinus, the sinuses healed in a mean period of 8 weeks (4 weeks to 12 weeks). ESR showed a declining trend in all patients after initiating anti tubercular therapy. It returned within normal range after a mean period of 6 months (range 4 - 12 months).

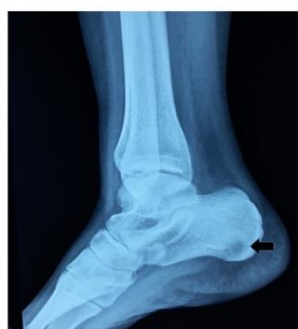

Figure 5: Lateral view radiograph of ankle of same patient as shown in Figure 1, after 9 months of ATT, showing the reminalisation and obliteration of cavity, as marked by black arrow.

Remineralisation of bone was seen in 5 patients at 3 months. Marginal sclerosis of cavity was evident at 6 months in 6 patients and at 9 months in 2 patients (Figure 5). In one patient, complete resolution of the cavity had occurred but heel varus due to asymmetric collapse of

bone was present at final follow-up. No evidence of recurrence in any patient.

DISCUSSION

Tuberculosis despite being curable and preventable continues to be a leading cause of morbidity and mortality, especially in the developing world. Most commonly it affects the lungs, but it can be found at extrapulmonary sites as well. Osteoarticular tuberculosis usually affects the spine and large joints like hip or knee. Involvement of foot and ankle is uncommon.⁴ This is a disease that must be diagnosed promptly before the pathological process destroys the bone or joint. However, since osteoarticular TB is a paucibacillary disease and has a non-specific clinical presentation, the diagnosis is often delayed.⁵

Low socioeconomic level and immunosuppression are risk factors for osteoarticular TB.^{6,7} Tuberculosis of the bone usually begins in the cancellous portion of the bone via blood stream or direct inoculation.⁸

Calcaneal tuberculosis can present with painful swelling of the heel, stiffness, sinuses, leg muscle wasting. Symptomatology is typically chronic and insidious, associated with constitutional features like fever, night sweats and weight loss.⁹ Some patients may also present with inability to bear weight, toe walking and what is known as the ‘heel-up’ sign leading to a misdiagnosis of pyogenic calcaneal osteomyelitis.¹⁰

Tuberculosis of the calcaneum has also been known to masquerade as Haglund's deformity, pyogenic osteomyelitis/abscess, fungal infections and benign or malignant tumors.¹¹

The largest series of calcaneal tuberculosis reported by Arora et al, describes an almost equal distribution of the disease between the two sexes.¹² It is described in both pediatric as well as adult age groups, however the presentation may differ between the two. Subtalar joint involvement and pathological fractures are more common in adult patients. The infective focus in children is well controlled and has better healing potential because of thick intact periosteum and a large cartilaginous scaffold.¹³ Though the involvement is usually unilateral, Agarwal et al have also described a case of bilateral calcaneal tuberculosis.¹³

Tubercular pathological process can affect any portion of the calcaneum or the entire bone. Broadly there are three patterns of involvement of the bone. A central granuloma type, which is the most common pattern, also has the best prognosis. The other two patterns, a diffuse seeding type with multiple lytic lesions and a periarticular granuloma type with soft tissue component, have poorer prognosis since they can progress to subtalar involvement and deformities.¹³

Calcaneal tuberculosis usually leads to formation of sequestrum that usually gets resorbed after 6 months of anti-tubercular chemotherapy. However, resolution of cavities takes a longer time and can be incomplete. Residual cavities may get filled up with fibrous or fibro-osseous tissue and have no clinical significance.^{3,5,14,15}

Calcaneal TB can be mimicked by bacterial infections, histiocytosis, metastatic disease, symptomatic Haglund's deformity etc.^{11,16} Therefore investigations, laboratory based as well as imaging play an important role in diagnosis. Plain radiographs can show small lytic lesions of variable sizes in the metaphyseal regions with blurred margins.¹⁷ Higher imaging modalities like a CT scan can reveal a sequestrum, minor cortical breaks and moth eaten appearance.¹⁸ Tc-99 m MDP scintigraphy is helpful in early diagnosis and monitoring response during follow-up.¹⁹ Magnetic resonance imaging helps in ruling out malignancies and confirms the pathology to be infective in nature.²⁰

Histopathological or microbiological diagnosis can be established using FNAC, core biopsy, CT guided biopsy or open biopsy.^{12,13}

As mentioned, the prognosis and outcome depend on an early diagnosis and management. Antitubercular chemotherapy is the mainstay of treatment. Up to 18 months of anti-tubercular chemotherapy has been recommended to prevent recurrence.¹³ Most authors agree upon a regime lasting for a period of 9-12 months.^{21,22} Surgical intervention should be reserved for patients non

responsive to ATT, those with deformity and painful joint involvement. Incision and drainage, sinus tract excision, curettage, sequestrectomy and debridement with or without arthrodesis are the various surgical options available to the orthopaedic surgeon.⁵ In our case, all the patients were managed non-operatively. Isolated tuberculous osteomyelitis is rare. The diagnosis is difficult and has to be made with good correlation of clinical, radiographic, and laboratory findings. Prognosis is good with non-operative management.

Funding: No funding sources

Conflict of interest: None declared

Ethical approval: The study was approved by the institutional ethics committee

REFERENCES

1. Tuli SM. Tuberculosis of the Skeletal System (2nd edition) New Delhi: Jaypee Brothers Medical Publishers; 1991: 3-122.
2. Martini M, Adjrard A. Tuberculosis of the ankle and foot joint. In: Martini M (ed.). Tuberculosis of the Bones and Joints. Berlin: Springer Verlag; 1988.
3. Dhillon MS, Aggarwal S, Prabhakar S, Bachhal V. Tuberculosis of the foot: an osteolytic variety, Indian J Orthop. 2012;46:206-11.
4. Choi WJ, Han SH, Joo JH, Kim BS, Lee JW. Diagnostic dilemma of tuberculosis in the foot and ankle. Foot Ankle Int. 2008;29:711-5.
5. Dhillon MS, Nagi ON. Tuberculosis of the foot and ankle. Clin Orthop Relat Res. 2002;398:107-13.
6. Peh WCG, Cheung KMC. Progressive shoulder arthropathy. Ann Rheum Dis. 1995;54:168-73.
7. Benbouazza K, El Maghraoui A, Lazrak N, Bezza A, Allali F, Hassouni F, et al. Les aspects diagnostiques de la tuberculose ostéoarticulaire. Analyse d'une série de 120 cas identifiés dans un service de rhumatologie. Sem Hop Paris. 1999;75:1057-64.
8. Agarwal N, Jain SK. Tuberculous osteitis of skull: A case report. Indian J Tuberc. 2009;49:105.
9. Manzella JP, Vanvoris LP, Hruska JF. Isolated calcaneal tuberculous osteomyelitis. A case report. J Bone Joint Surg Am. 1979;61(6):946-7.
10. Rasool MN. Hematogenous osteomyelitis of the calcaneus in children. J Pediatr Orthop. 2001;21:738-43.
11. Gillott E, Ray P. Tuberculosis of the calcaneum masquerading as Haglund's deformity: a rare case and brief literature review. BMJ Case Rep. 2013;2013:bcr2013009252.
12. Arora A, Dhami I, Kumar S, Nadkarni B, Arora G, Mathur NC. Calcaneal tuberculosis: a study of 39 cases. J Bone Joint Surg Br. 2001;84(3):233.
13. Agarwal A, Kant KS, Suri T, Gupta N, Verma I, Shaharyar A. Tuberculosis of the calcaneus in children. J Orthop Surg (Hong Kong). 2015;23(1):84-9.

14. Gad MS, Ezzat F, Shalabi S. Tuberculous osteomyelitis of the calcaneus (case report). *Pan Arab J Orthop Trauma.* 2007;2:125–7.
15. Dhillon MS, Tuli SM. Osteoarticular tuberculosis of the foot and ankle. *Foot Ankle Int.* 2001;22:679–86.
16. Abdelwahab IF, Klein MJ, Hermann G, Abdul-Quader M. Focal tuberculous osteomyelitis of the calcaneus secondary to direct extension from an infected retrocalcaneal bursa. *J Am Podiatr Med Assoc.* 2005;95(3):285–90.
17. Kadu VV, Saindane KA, Godghate N, Godghate NN. Tuberculosis of Calcaneum – A Rare presentation. *J Orthop Case Reports.* 2016;6(1):61-2.
18. Agarwal A, Qureshi NA, Khan SA, Kumar P, Samaiya S. Tuberculosis of the foot and ankle in children. *J Orthop Surg (Hong Kong).* 2011;19:213–7.
19. Trikha V, Gupta V, Rastogi S, Kumar R. Tuberculosis of calcaneus: assessing treatment response by Tc-99m MDP scintigraphy. *Clin Nucl Med.* 2004;29(8):506.
20. Mittal R, Gupta V, Rastogi S. Tuberculosis of the foot. *J Bone Joint Surg Br.* 1999;81(6):997-1000.
21. Tuli SM. General principles of osteoarticular tuberculosis. *Clin Orthop.* 2002;398:11–9.
22. Chater L, Arroud M, Afifi MA. Tuberculosis of the calcaneus in children. *Int J Mycobacteriol.* 2014;3(1):57-9.

Cite this article as: Tiwari A, Bhatnagar N, Karkhur Y, Aslam A, Sharma A, Sabat D. Tuberculosis of calcaneum: a case series and review of literature. *Int J Res Orthop* 2017;3:761-5.