

Original Research Article

Comparison study of compound fractures of tibial shaft treated by titanium and stainless steel interlocking nails

Pratik J. Vinchhi¹, Sharvil H. Gajjar^{1*}, Tirth Vyas², Yatin Patel³

Department of Orthopaedics, ¹GCS Medical College and Hospital, Ahmedabad, Gujarat, ²Port Trust hospital Mumbai, Maharashtra, ³Government Medical College, Surat, Gujarat, India

Received: 20 March 2017

Revised: 21 April 2017

Accepted: 07 April 2017

*Correspondence:

Dr. Sharvil H. Gajjar,

E-mail: sharvilgajjar@yahoo.co.in

Copyright: © the author(s), publisher and licensee Medip Academy. This is an open-access article distributed under the terms of the Creative Commons Attribution Non-Commercial License, which permits unrestricted non-commercial use, distribution, and reproduction in any medium, provided the original work is properly cited.

ABSTRACT

Background: The purpose of the present study was to compare the outcomes of compound fractures of tibia shaft managed by Solid Titanium and Stainless Steel interlocking intramedullary nailing.

Methods: This is a retrospective study of 45 patients with 45 open fractures of tibia shaft operated primarily by either Solid Titanium or Stainless steel tibia interlocking nail.

Results: In Our Study we had 45 patients with 45 open tibial fractures. All were male. 35 patients were from 20-50 years age group. Mean age was 36.4 years. In this study of 45 open tibial fractures following strict protocol of thorough debridement, primary wound closure and Solid Titanium or stainless steel interlocking nailing; it was observed at final follow up that patients operated by titanium nail compared to stainless steel had 6.45% vs. 14.29% infection rate, 12.9% vs. 21.89% rate of non-union and 3.22% vs. 7.14% screw breakage rate. According to modified ketenjian's criteria in our study out of 31 patients operated by Titanium interlocking nail 17 (54.84%) excellent, 10 (32.26%) Good, 3(9.68%) fair and 1(3.22%) poor functional results while out of 14 patients managed by stainless steel nail 8 (57.14%) excellent, 3 (21.43%) good, 1 (7.14%) fair and 2 (14.28%) poor functional results.

Conclusions: In open tibial fractures titanium interlocking implants offer lower complication rate as compared to stainless steel implants and better overall patient outcome.

Keywords: Open fracture, Tibia, Titanium, Stainless steel, Interlocking nail, Modified Ketenjian's criteria

INTRODUCTION

Tibial shaft fractures are one of the most common long bone fractures with incidence of 26/100000 per year.¹ 23% of tibia fractures are open fractures.¹ They are often difficult to treat especially open fractures due to subcutaneous location with minimal soft tissue coverage and precarious blood supply. Open fractures mainly affect young adults due to road traffic accident. It is mainly due to increased high velocity two wheeler usage.² Open fractures of tibial shaft often complicate and add to morbidity often leading to unemployment and economical issues.

There are many ways of treating tibial shaft fractures like ender's nailing, TEN nailing, interlocking nailing, external Fixator and plating.³ Each technique has its unique advantages and disadvantages. A recommendation about tibial shaft fractures management are getting updated with time and still depends largely on fracture location, morphology and soft tissue coverage and are still controversial.

Open Reduction and internal fixation by plating disrupts the periosteal blood supply.⁴ Intramedullary nailing disrupts endosteal supply but being a load sharing implant it gives better option than plating and endosteal

blood supply has enormous capacity to regenerate. Titanium nails provide added advantage over Stainless Steel nails of not allowing slime layer to form over nails and thus reducing chances of infection theoretically. Moreover interlocking nails provide advantage of rotational stability over unlocked nailing.⁵

Metallurgy: titanium vs. stainless steel

Stainless steel and titanium are commonly use metals to make orthopaedic implants.

There are at least 50 alloys with different grades of stainless steel. ASTM F-55, F-56 (Grade 316 and 316L) is used commonly to make orthopaedic implants. Stainless steel is steel with 10.5% chromium with nickel added; which imparts corrosion resistance.

Titanium alloy commonly used to make implants is Ti6Al4VELI (ASTM F-136).

Stainless steel has double the modulus of elasticity as titanium. So titanium implant cause less stress shielding and also are less prone to fatigue failure.⁶ Thus titanium implants allow more micro motion, at fracture site, thanks to its lesser stiffness as compared to stainless steel and thus hasten callus formation.^{7,8} Stainless steel is cheaper but it corrodes on long term and has higher rate of allergic reaction. Moreover stainless steel has potential to cause toxicity on long term because of its nickel and chromium content. Titanium implants offer advantage of less corrosion and allergic reaction and so no need to remove implant for fear of long term toxicity and thus also reducing chance of infection. Thus titanium is more biocompatible as compared to stainless steel.

Oliver et al studied differences in results of stainless steel and titanium shanz pins in distal radial fractures and shown higher rate of pin loosening and pin tract infection in stainless steel group and concluded that use of titanium pin lowers rate of infection.⁸

Soultanis et al studied difference in results of titanium and stainless steel instrumentation of spine and concluded that stainless steel is associated with higher inflammatory response, higher infection rate and implant loosening and thus titanium to be better.⁹

From above literature we can conclude that unreamed, solid and preferably titanium nails would be the ideal choice for open tibial fractures. The purpose of the present study was to compare the outcome of compound fractures of tibia managed by Titanium and Stainless steel interlocking intramedullary nailing.

METHODS

This is a study of 45 patients with 45 open fractures of tibia operated primarily by titanium and Stainless steel tibia interlocking at GCS medical college and hospital

Ahmedabad from January 2015 to August 2016. There were 5 female patients also with open tibial fractures but were lost to follow up. All patients were followed up from minimum 7 months to maximum 32 months with mean follow of 20 months.

Management protocol

Inclusion criteria

Patients with open tibial shaft fractures, adults, no distal neurovascular deficits, grossly non contaminated wound, fractures that operated within first 24 hours of injury were included in this study.

Exclusion criteria

Exclusion criteria were fractures of tibia not amenable to interlocking nail, means very high or low level in shaft, children or tibias with open physis, open grade 3 c Gustillo Anderson injuries, wound with soiling especially patients with delayed presentation after injury.

We had developed the following protocol in this study. At the time of arrival of patient we assessed general condition of the patient first in form of vitals. Also assessed for associated injuries like head, abdomen, pelvic or other injuries. Local examination consists of wound assessment and distal movements and pulsations. All wounds were initially washed with saline, povidone iodine and hydrogen peroxide under aseptic precautions and sterile dressings were kept. Fractured limb was immobilized in an above knee slab. All patients were given injection tetanus toxoid and anti-tetanus human immunoglobulin and adequate antibiotic coverage.

After assessment by anesthetic team if possible we used to take patient in operation theatre for interlocking nailing as early as possible.

Operative procedure

Under all aseptic precautions patients were shifted to operation theatre. Appropriate preoperative antibiotic prophylaxis was given. Fracture table, Supine position, after spinal/general anesthesia. Fracture reduction was attempted prior to painting and draping. Wound again thoroughly washed with povidone iodine and saline. Painting and draping done. Around 3cm incision over tibia upper end. Skin, subcutaneous tissue cut and patellar tendon split. With awl entry taken after entry point confirmation under IITV. Entry part widened with reamers. Guide wire inserted and passed through fracture site till near tibial plafond. No reaming of medullary canal across fracture was performed. Appropriate sized nail inserted and passed till tibial plafond. Distal interlocking screws inserted first. Then back hammer done to allow for fracture collapse when appropriate. After reduction confirmation, proximal locking done. Patellar tendon split closed. Rest skin suturing done.

Distal pulsation again checked. Patient shifted outside operation theatre with below knee slab.

Postoperative protocol

Patients were immobilized in below knee slab and allowed non weight bearing walking after 24 hours. Quadriceps and toe exercises encouraged as soon as patient is out of anesthesia. All patients were followed up every month for 3 months with X-rays. At every follow up patients were assessed radiologically as well as clinically. Some patients were lost to follow up in between so assessment could not be carried out regularly and so time to fracture union could not be calculated exactly from current study.

No tenderness at fracture site and solid bridging callus at fracture site in X-ray were considered as criteria for union.¹¹⁻¹³ Fractures not showing union between 24 and 36 weeks were considered delayed union and fractures not united at 9 months with no signs of progression of union for last 3 months both clinically as well as radiologically were considered nonunion.^{10,11,14} Shortening >10 mm, Rotation >15 degrees, AP angulation >5 degrees, Varus-Valgus angulation >5 degrees were considered as malunion.¹⁰ After 6 weeks full weight bearing walking was allowed in patients showing signs of union with no other injuries. Interlocking tibia nails solid titanium were used in all cases. Reaming was not done in any cases.

Final follow up: outcomes were assessed by modified Ketenjian’s criteria, and rated as excellent, good, fair or poor based on pain, knee/ankle stiffness, swelling/deformity and gait of patient.

- Excellent: No notable abnormality.
- Good: Occasional pain with prolonged use, joint motion 75% of normal, trivial swelling, normal gait.
- Fair: Pain with ordinary activity, joint motion 50% of normal, small amount of swelling, slight limp.
- Poor: Constant pain, joint motion less than 50% of normal, any visible deformity, limp, gait on cane or crutches.

RESULTS

Age, sex and cause of fracture

In our study of 45 patients with 45 open tibial fractures, 35 (77.78%) patients were in 20-50 years age group. All patients in current study were male. 5 females also had open tibia fracture but could not be included in the study, as they were lost to follow up. In this study, 40 (88.89%) patients had open tibia fracture due to road traffic accident and rest of the fractures was due to assault or fall from height. None occurred by simple fall or sports injury.

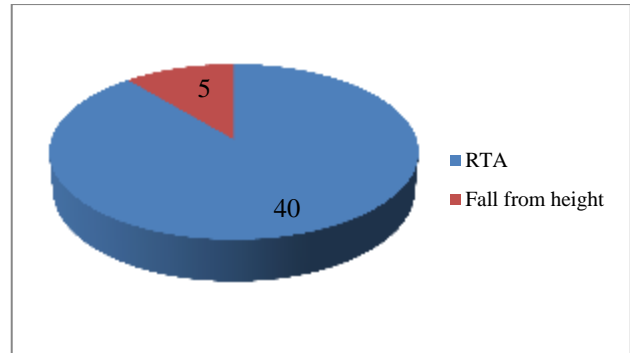


Figure 1: Mode of injury.

Local wound condition

2 patients of 31 operated by titanium nail had wound necrosis while 2 of 14 patients operated by stainless steel had wound necrosis. Both patients operated by titanium nail had open grade 3 while stainless steel nail had open grade 2 Gustillo Anderson injuries. All 4 patients eventually developed deep infection. All 4 patients were treated by local rotation flap. At final follow up only one patient with stainless steel nail had persistent discharge and was treated by nail removal and external fixator. All patients with open grade 1 injuries had complete wound healing. We used to close the open wound primarily after nailing after thorough wash with normal saline.

Following our protocol of thorough debridement and primary closure with immediate rigid fixation by titanium nail 29 (93.55%) tibias had good wound healing while with stainless steel nailing 12 (85.71%) patients had good wound healing at the final follow up.

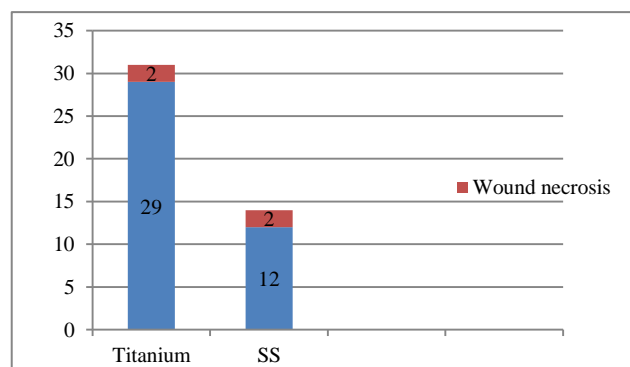


Figure 2: Wound necrosis.

Time for full weight bearing

Time for full weight bearing in current study varied from 15 days to 11 months with average time of 14.9 weeks. 4 patients in our study required flap in which average time to full weight was 33 weeks. In this study 9 polytrauma patients had ipsilateral or contralateral lower or upper

limb fractures. Among these patients average time to full weight bearing was 20 weeks. Moreover there are patients in this study who started weight bearing on their own in the 1st postoperative month and some others who were afraid and delayed full weight bearing despite surgeon's advice. As and when possible, especially in isolated tibial shaft fractures non weight bearing crutch walking was started within the first 2 weeks.

Fracture union

Of 31 patients operated by titanium interlocking nails 27 fractures (87.1%) showed good radiological and clinical signs of bone union. Exact time to radiological union could not be judged as some patients had irregular follow up. 4 (12.9%) patients with delayed/nonunion were noted, 2 of them had infection at open wound site with wound necrosis, both of which had open grade 3b fractures. Both were treated by debridement and flap coverage and both got united later. Other 2 patients had comminution at fracture site, by bone grafting both were united.

11 (78.57%) patients of 14 operated by stainless steel nails had fracture united. Out of 3 nonunions (22.27%), 2 had infected open wound, both of which had open grade 2 fractures. Flap coverage with debridement was done in both of infected patients; one of them had persistent discharge at final follow up. 2 patients were needed for bone grafting and one patient with persistent infection was treated by removal of implant and external fixator.

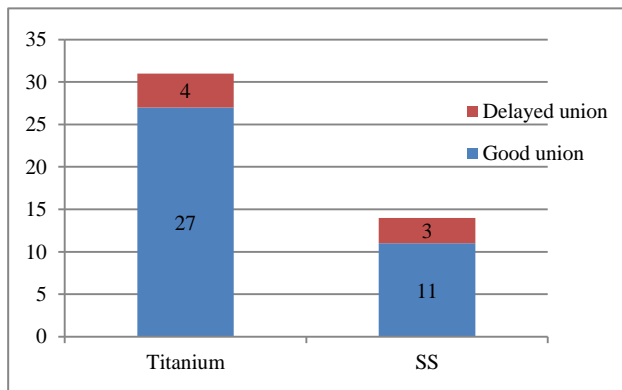


Figure 3: Rate of union.

Functional outcome

In current study 39% fractures were open grade 1, 48.39% open grade 2 and 12.9% open grade 3. In our study patients with open grade 1 fractures had 100% wound healing, 0% infection and 0% of non/delayed union; with open grade 2 fractures 13.33% patients had major wound problem, 13.33% infection and 13.33% nonunion and in open grade 3 fractures 50% had wound problems and 50% infection and nonunion. This explains the impacts of soft tissue injury on functional outcome and rate of complications.

Complications

Nonunion

Nonunion was observed in 4 (12.9%) patients treated by titanium nails while 3 (21.89%) patients treated by stainless steel nails had nonunion. 2 patients in each group had infected nonunion while 2 treated by titanium and one treated by stainless steel had aseptic nonunion. All 3 aseptic nonunions were having fractures of proximal third of tibial shaft and were having improper reduction.

Infection

2 (6.45%) patients operated by titanium nails had infection while 2 (14.29%) of patients treated by stainless steel nail had infection out of all only one patient had developed persistent infection with nonunion and implant removal and external fixator. 2 patients of open grade 3 treated by titanium nails had no infection at final follow up.

Implant failure

1 patient in each group had proximal static screw breakage. Both had 8 mm diameter nail. None cases of nail breakage was observed during current study. Screw breakage was not observed in any patients with nonunions.

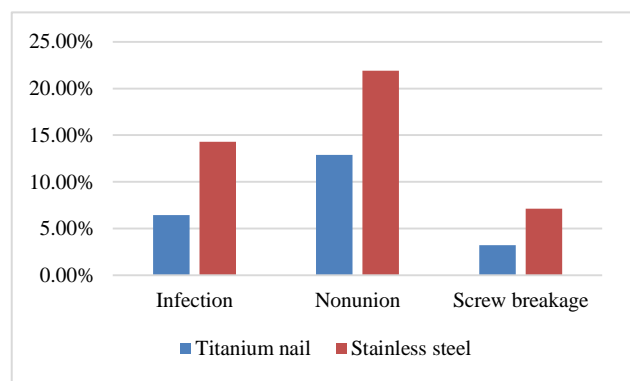


Figure 4: Complications comparison of titanium and Stainless steel Nailing.

Fracture location and outcome

Proximal third location was associated with worst outcome and had highest rate of aseptic nonunion. Though patients with middle third fractures had more complications, they had better functional outcome. 1 (3.23%) patient of titanium nail and 1 (7.15%) patient of stainless steel nail had aseptic nonunion. Because of more rigid construction by stainless steel it could allow less micro movements and thus could be delaying fracture healing.

Patients with open grade 1 fractures required less secondary procedures had fewer complications and best results. Open grade 3 fractures had highest rate of infection and nonunion.

Functional outcome

According to modified Ketenjian’s criteria in our study out of 31 patients operated by Titanium interlocking nail 17 (54.84%) excellent, 10 (32.26%) good, 3 (9.68%) fair and 1 (3.22%) poor functional results while out of 14 patients managed by stainless steel nail 8 (57.14%) excellent, 3 (21.43%) good, 1 (7.14%) fair and 2 (14.28%) poor functional results.

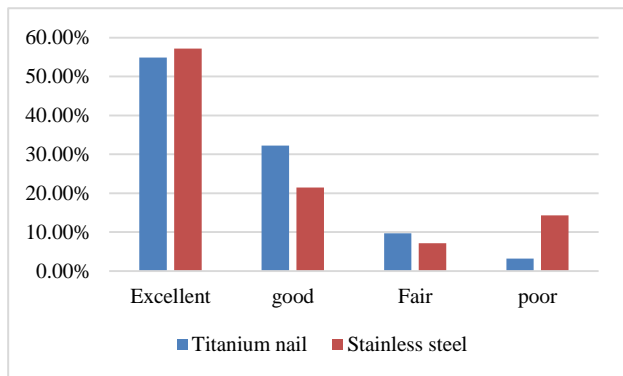


Figure 5: Functional outcomes according to modified Ketenjian's criteria.

DISCUSSION

This is a retrospective study of 45 patients with 45 open fractures of tibia shaft operated primarily by either Solid Titanium or Stainless steel tibia interlocking nail.

Mean age of patients in our study was 36.4 years, which is comparable to Whittle et al (34 years), Joshi et al (30 years) and Vineet et al (40.3 years). People in this age group are socially active and drive vehicles more.^{5,16,17} These factors contribute to higher incidence of open tibial fractures in this group.

All patients in current study were male. 5 females also had open tibia fracture but could not be included in the study, as they were lost to follow up. If they would have been included, then there would have been 90% males; which is comparable to other studies. Vineet et al (92.5% male), Joshi et al (2.86% male) and Whittle et al (72.34%) have also shown higher incidence in males.¹⁵⁻¹⁷ Due to high use of two wheelers, male are affected usually more commonly.

In this study, 40 (88.89%) patients had open tibia fracture due to road traffic accident and rest of the fractures was due to assault or fall from height. None occurred by simple fall or sports injury. Vineet et al (87.5% due to road traffic accident) and Joshi et al (100% due to road traffic accident) have also shown road traffic accidents as

the main cause for open tibial fractures. In study of Whittle et al 87.23% open tibial fractures were due to road traffic accidents.^{16,17}

Time for full weight bearing in current study varied from 15 days to 11 months with average time of 14.9 weeks. 4 patients in our study required flap in whom average time to full weight was 33 weeks. In this study 9 polytrauma patients had ipsilateral or contralateral lower or upper limb fractures. Among these patients average time to full weight bearing was 20 weeks. Moreover there are patients in this study who started weight bearing on their own in the 1st postoperative month and some others who were afraid and delayed full weight bearing despite surgeon’s advice. As and when possible, especially in isolated tibial shaft fractures nonweight bearing crutch walking was started within the first 2 weeks. These results were contradictory to those observed in a study by Court-Brown et al, where 90% of patients showed full weight bearing by 6-weeks and only 10 % showed joint stiffness six months after the surgery.¹ However, some patients did show weight bearing from 15 days post-surgery itself. Factors contributing to delay in full weight bearing are fracture type, severity of soft tissue injury, polytrauma with ipsilateral or contralateral lower limb or axial injury and patients’ psychology.

Comparing the nonunions/delayed unions in patients operated with stainless steel nails vs. patients operated with titanium nails, it was observed that percentage of nonunion/delayed union was more in patients operated with stainless steel nails (22.7%) than with titanium nails (12.9%). Nonunion and delayed union rate was 4% in study of whittle et al, 21.42% in study of Joshi et al and 10% in study by Vineet et al.¹⁷

It was observed that the functional outcomes in patients operated with stainless steel nails was better than the patients operated with titanium nails. However, the difference was not so remarkable i.e. 57.14% patients with stainless steel nails showed excellent outcome compared to 54.84% patients with titanium nails showed excellent outcome. The functional outcome was compared on the basis of modified Ketenjian’s criteria.¹⁸

2 (6.45%) patients operated by titanium nails had infection while 2 (14.29%) of patients treated by stainless steel nail had infection out of all only one patient had developed persistent infection with nonunion and implant removal and external fixator. These results were comparable to those observed by Veliskasis in his study which had 10% patients developing deep infections.¹⁸

CONCLUSION

In this study of 45 open tibial fractures following strict protocol of thorough debridement, primary wound closure and Solid Titanium or stainless steel interlocking nailing; it was observed that at final follow up that patients operated by titanium nail compared to stainless

steel had a much smaller infection rate, rate of nonunion and screw breakage rate.

In this study, 2 open grade 3b patients were operated by Titanium nails, while there was no patient in this study with open grade 3 patient operated by stainless steel nails. Still Titanium implants have given lesser complication rate and better functional outcome. Thus we can conclude that open tibial fractures can be managed effectively and with good success by titanium interlocking nails, which can be preferred over stainless steel.

Funding: No funding sources

Conflict of interest: None declared

Ethical approval: The study was approved by the institutional ethics committee

REFERENCES

1. Court Brown CM, McBirnie J. The epidemiology of tibial fractures. *J Bone Joint Surg Br.* 1995;77:417-21.
2. Zettas JP, Zettas P, Thanosophon B. Injury patterns in motor cycle accidents. *J Trauma.* 1979;19:833-6.
3. Rockwood Charles A Jr, Green David P. Rockwood & Green's Fractures in Adults. Bucholz RW, Heckman JD, Court-Brown CM, editors. Fractures of the Tibia and Fibula. 6th Edition. Philadelphia: Lippincott Williams & Wilkins; 2006: 2081.
4. Rockwood Charles A Jr, Green David P. Rockwood & Green's Fractures in Adults. Bucholz RW, Heckman JD, Court-Brown CM, editors. Bone and joint healing. 6th Edition. Philadelphia: Lippincott Williams & Wilkins; 2006: 305.
5. Thakur AJ. The elements of fracture fixation. 2nd edition. Intramedullary nailing. 2006: 143.
6. Hak DJ, Toker S, Yi C, Toreson J. The Influence of Fracture Fixation Biomechanics on Fracture Healing. *Orthopedics.* 2010;33(10):752-5.
7. Xu WZ, Guo XD, Zhao JC, Wang YJ. Effect of autocontrol micromotion intramedullary interlocking nail on fracture healing: an experimental study. *Chin J Traumatol.* 2006;9(3):152-60.
8. Pieske O, Geleng P, Zaspel J, Piltz S. Titanium Alloy Pins Versus Stainless Steel Pins in External Fixation at the Wrist: A Randomized Prospective Study. *J Trauma.* 2008;64(5):1275-80.
9. Soultanis KC, Pyrovolou N, Zahos KA, Karaliotas GI, Lenti A, Liveris I, et al. Late postoperative infection following spinal instrumentation: stainless steel versus titanium implants. *J Surg Orthop Adv.* 2008;17(3):193-9.
10. Blachut PA, O'Brien PJ, Meek RN, Broekhuysen HM. Interlocking intramedullary nailing with and without reaming for the treatment of closed fractures of the tibial shaft. *J Bone Joint Surg Am.* 1997;79(5):640-6.
11. Corrales LA, Morshed S, Bhandari M, Miclau T 3rd. Variability in the assessment of fracture healing in Orthopaedic Trauma Studies. *J Bone and Joint Surgery.* 2008;90(9):1862-8.
12. Sledge SL, Jhonson KD, Henley MB, Watson JT. Intramedullary nailing with reaming to treat nonunion of the tibia. *J Bone and Joint Surg.* 1987;71(7):1004-19.
13. Campanacci M, Zanoli S. Delayed union in tibial shaft fractures, a review of 171 cases. *J Bone and Joint Surg.* 1966;48(1):44-56.
14. Weissman S, Herold Z., Engelberg M. Fractures of the Middle two thirds of the tibial shaft: Results of treatment without internal fixation in 140 consecutive cases. *J Bone Joint Surg Am.* 1966;48:257-67.
15. Whittle AP, Russell TA, Taylor JC, Lavelle DG. Treatment of open fractures of the tibial shaft with the use of interlocking nailing without reaming. *J Bone Joint Surg Am.* 1992;74:1162-71.
16. Joshi D, Ahmed A, Krishna L, Lal Y. Unreamed interlocking nailing in open fractures of tibia, *J Orthop Surg (Hong Kong).* 2004;12(2); 216-21.
17. Jain V, Aggarwal A. Primary unreamed intramedullary locked nailing in open fractures of tibia. *IJO.* 2005;39(1):30-2.
18. Ketenjian AY, Shelton MJ. Primary internal fixation of open fractures: a retrospective study of the use of metallic fixation in fresh open fractures. *J Trauma.* 1972;12:756-63.

Cite this article as: Vinchhi PJ, Gajjar SH, Vyas T, Patel Y. Comparison study of compound fractures of tibial shaft treated by titanium and stainless steel interlocking nails. *Int J Res Orthop* 2017;3:390-5.