

Original Research Article

A prospective study on operative management of displaced fracture of midshaft of clavicle

Mohammed Ismail Hathiwale*, Prakash A. Sasnur, Md. Johorul Islam Tapadar

Department of Orthopaedics, Al-Ameen Medical College, Vijayapura, Karnataka, India

Received: 18 March 2017

Accepted: 12 April 2017

***Correspondence:**

Dr. Mohammed Ismail Hathiwale,

E-mail: ismailtusk@yahoo.com

Copyright: © the author(s), publisher and licensee Medip Academy. This is an open-access article distributed under the terms of the Creative Commons Attribution Non-Commercial License, which permits unrestricted non-commercial use, distribution, and reproduction in any medium, provided the original work is properly cited.

ABSTRACT

Background: Clavicle fractures had been traditionally treated non-operatively which resulted in high rates of non-union. The present study has been undertaken to study the role of precontoured locking compression plate in the fixation of mid-third clavicle fractures.

Methods: We reviewed the results of 25 cases of displaced middle third clavicle fractures (Robinson type 2B) which were treated with open reduction and internal fixation with pre-contoured locking compression plate at Al-Ameen Medical College and Hospital.

Results: Out of 25 patients operated with precontoured LCP, 21 were male and 4 were female patients. One patient had hypertrophic scar, one patient had plate prominence, two patients had delayed union and one patient had implant failure, none of them developed non-union. Constant Murley score was excellent in 19, good in 4 and fair in 1 patient and poor in 1 patient.

Conclusions: Precontoured locking compression plate fixation has better functional outcome, immediate pain relief, early return to function and avoids complications of conservative methods.

Keywords: Midshaft clavicle fracture, Precontoured LCP, Functional outcome

INTRODUCTION

Fractures of the clavicle are common, accounting for 2.6% of all fractures and up to 44% of all injuries to the shoulder girdle.¹ Mid shaft fractures account for 80% of all clavicle fractures, Approximately 2-5% of all fractures in adults and 10 to 15% in children involve the clavicle.

There is 15% nonunion rate in widely displaced fractures of middle-third of the clavicle treated without surgery and all fractures with initial shortening of more than 2cm resulted in nonunion.²

Plate fixation options include low contact dynamic compression plates, which are strong, but difficult to contour and cause soft tissue irritation. Reconstruction plates are easier to contour, but lack sufficient mechanical

strength. Pre-contoured locking plates provide immediate pain relief, rigid stabilization, and early mobilization. Anatomically pre-contoured implants have the potential advantages of not requiring further bending, having a lower profile causing fewer soft tissue problems whilst retaining the mechanical strength of the stronger plates. The aim of this study is to analyze the functional outcome and complications of fractures of middle third of clavicle with pre-contoured locking plate.

METHODS

25 cases of displaced middle third clavicle fractures (Robinson type 2B) were enrolled and treated with open reduction and internal fixation with pre-contoured locking compression plates from December 2014 to June 2016 at Al-Ameen Medical College and Hospital,

Vijayapur. All patients gave informed verbal consent to be included into the study and the study was authorized by the ethical committee.

Inclusion criteria

Age>18 years, closed fractures, Robinson classification 2B1 and 2B2 and no medical contraindications to anaesthesia.

Exclusion criteria

Age<18years, open fractures, pathological fractures, undisplaced fractures, associated head injury, associated neurovascular injury.

Surgical technique

Under general anesthesia, the patient was placed in supine position with a sponge pad placed under the affected shoulder. An incision along the superior border of clavicle was taken. The fracture site was exposed and soft tissue released carefully. After reducing the fracture, the precontoured locking compression plate was fixed over the superior surface with bicortical locking screws on either side of the fracture. Interfragmentary screw was used in oblique fractures and to fix large butterfly fragment. The wound was closed in layers and sterile dressing done and limb was supported in arm sling

Post-operative protocol

Immediately after surgery, operated limb was put in arm sling. Wound was inspected at 2nd, 5th and 10th days. Sutures/Staples were removed at 10th day once the wound is clean and dry. Till 3 weeks patients are advised to use sling and at 3 weeks they are advised the pendulum exercises till 6 weeks. At 6 weeks check x-rays were taken and then full range of motion exercises started. Next follow-ups were done at 3months, 6 months and 1 year. Functional outcome was assessed based on constant Murley score.

RESULTS

Out of 25 patients operated with precontoured locking compression plate, 21 were male and 4 were female patients. In this study the patients with middle third clavicle fracture the mechanism of injury was due to road traffic accident in 20 patients (80 %), simple fall on the shoulder in 2 patients (8%), fall on outstretched hand in 3 patients (12 %). Average age was 39 years.

In our study there were 21 males and 4 female patients. In this present study, patients with Robinson Type-2 B1 (displaced with simple or butterfly fragment) classification were 16 patients (64%) and type-2 B2 (displaced with comminution) classification were 9 patients (36%). Most of the patients in our study were operated within 7 days (21 patients - 84%). 4 patients

(16%) were operated after 7 days. In our study 6, 7, 8 hole plates were used to treat the fracture depending on the type and comminution. 6 hole plate in 8 patients (32%), 7 hole plate in 14 patients (56%), 8 hole plate in 3 patients (12%). One patient had plate prominence, two had delayed union, one had hypertrophic scar. None of them developed malunion or non-union. One patient had implant failure.

Table 1: Robinson classification.

Robinson classification	N	Percent
B1	16	64
B2	9	36

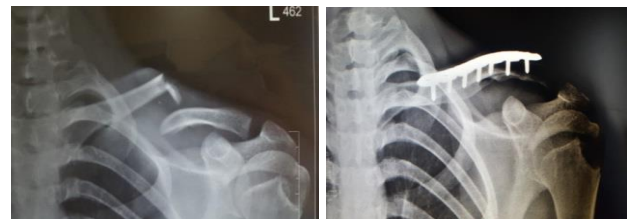

Figure 1: Pre-operative and post-operative x-rays.

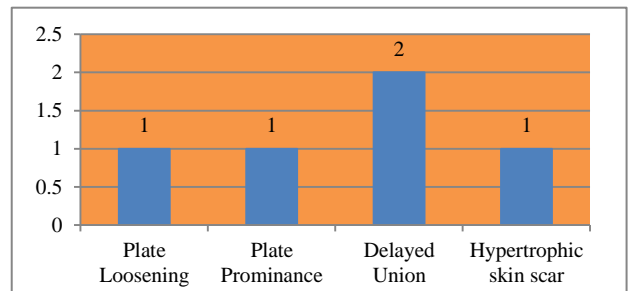


Figure 2: Complications.

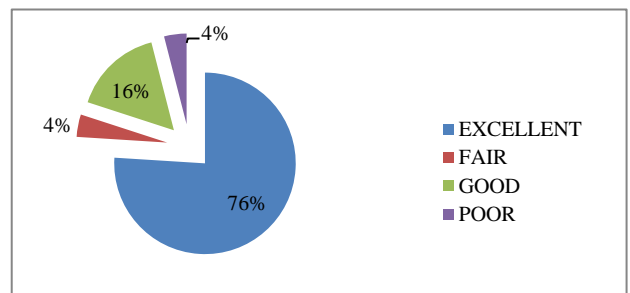


Figure 3: Functional outcome.

DISCUSSION

Fall onto the affected shoulder accounts for most of the clavicular fractures with direct impact accounting for only little.

There are different methods of management of clavicle midshaft fracture. Intra medullary and extra medullary (K wire, Steimman pin, recon plate, new generation pre-contoured anatomical plates).

Various studies on K wire fixation, Steinman pin fixation showed that there was a low resistance to the torque force, pin loosening, infection and prolonged period of fixation.

Plate osteosynthesis gives better torque resistance and obtaining anatomical reduction and compression of the fracture site, but the plates have to be bent to achieve the shape of clavicle and the fixation was difficult in comminuted fractures.

New generation plates like pre-contoured anatomical plates are light weight, thin and give good anatomical reduction, tolerates multidirectional stress, torque and because of its locking property it gives rigid fixation in the old age osteoporotic patients.

Care needs to be taken to avoid injury to subclavian nerves, vessel bundle as this may happen while drilling the opposite cortex.

In this study we had rigid fixation in all the patients; we experienced few complications like plate loosening, hardware prominence. No cases of pain, non-union or functional disabilities were observed.

Pre-contoured anatomical locking compression plate gives rigid fixation with good anatomical reduction and can be used as alternative to previously used plates.

Advantages of pre-contoured anatomical LCP

Rigid fixation by locking of screws with the plate which acts as internally fixed external fixator functions as a single unit, reducing chances of screw backout or plate loosening. As these are limited contact plates, there is preservation of blood supply due to minimal surface contact of plate with bone and because of the locking property excess tightening is not possible and in return that decreases the compression of plate on the bone which helps in preservation of blood supply.

Because of the locking property of the plate and screw it is not necessary that the tip of the screw should pass the opposite cortex but care should be taken during drilling. Decreased periosteal stripping results in rapid union.

The drawback of the plate system is scarring over the collar bone which is of big cosmetic concern in females and to some extent in males too.

We noted plate prominence in one lean patient, one plate loosening, two delayed union and one patient had hypertrophic scarring.

Use of pre-contoured anatomical plate significantly decreases the procedure timing as it is pre bent according to the shape of the clavicle, lighter, thinner, and durable to multidirectional stress on fracture site.

Better surgical skill and experience is necessary for the better outcome by using the pre-contoured anatomical locking compression plate, as clavicle is a subcutaneous bone and it lies above the major neurovascular bundle and as it is beauty bone it needs beautiful fixation for better cosmetic outcome.

Schiffer et al presented and evaluated the current treatment options on the basis of a selective review of the literature. The risk of non-union after conservative treatment was previously reported as 1% to 2% but has turned out to be much higher in selected subgroups such as in patients with severe displacement, female patients, and patients of advanced age. Furthermore, new implants and techniques have made surgery safer and more likely to result in bony union.³

Darren et al in a biomechanical study compared four different techniques of fixation of mid-third clavicle fractures viz. 3.5mm Recon plates, 3.5 mm LC-DCP, 3.5 mm LCP and 4.5 mm Rockwood pin and found that locking plate have stiffer constructs.⁴

Zlowodski et al conducted a meta-analysis of 2144 fractures. In that they showed a relative risk reduction of 57% for non-union using a plate compared to 86% of non-union for patients treated conservatively.⁵

Kulshrestha reviewed the results of twenty cases of displaced/ comminuted midclavicular fractures, which were treated with primary open reduction and internal fixation with a reconstruction plate placed over the superior surface of clavicle leads to predictable and early return to function thus preventing unacceptably high complication rates of non-operative management of these fractures.⁶

CONCLUSION

Precontoured locking compression plate fixation has better functional outcome, immediate pain relief, early return to function and avoids complications of conservative methods like shoulder stiffness.

Funding: No funding sources

Conflict of interest: None declared

Ethical approval: The study was approved by the institutional ethics committee

REFERENCES

1. Postacchini F, Gumina S, De Santis P, Albo F. Epidemiology of clavicle fractures. *J Shoulder Elbow Surg.* 2002;11:452-6.
2. Rickert AB, Hosalkar H, Pandya N, Namdari S. Displaced Clavicle Fractures in Adolescents: Facts, Controversies, and Current Trends. *J Am Acad Orthop Surg.* 2013;21:1-2.
3. Schiffer G, Faymonville C, Skouras E, Andermahr J, Jubel A. Midclavicular fracture: Not just a trivial

- injury – current treatment options. *Dtsch Arztebl Int*. 2010;107;711-7.
4. Drosdowech DS, Manwell SE, Ferreira LM, Goel DP, Faber KJ, Johnson JA. Biomechanical Analysis of Fixation of Middle Third Fractures of Clavicle. *J Orthop Trauma*. 2011;25(1):39-43.
 5. Zlowodzki M, Zelle BA, Cole PA, Jeray K, McKee MD. Treatment of acute midshaft clavicle fractures: systematic review of 2144 fractures: on behalf of the Evidence-Based Orthopaedic Trauma Working Group. *J Orthop Trauma*. 2005;19:504-7.
 6. Kulshrestha V. Primary Plating Of Displaced Mid-Shaft Clavicular Fractures. *Med J Armed Forces India*. 2008;64(3):208-11.

Cite this article as: Hathiwale MI, Sasnur PA, Tapadar MJI. A prospective study on operative management of displaced fracture of midshaft of clavicle. *Int J Res Orthop* 2017;3:619-22.