

## Original Research Article

# Use of henna as a durable pre-operative skin marker for accurate localisation of vertebral level in spine surgery

Ankit Thora<sup>1</sup>, Nishit Bhatnagar<sup>2\*</sup>, Anurag Tiwari<sup>3</sup>, Purushotham Lingaiah<sup>2</sup>, Nitesh Rustagi<sup>4</sup>

Department of Orthopaedics, <sup>1</sup>Shalby Hospital, Ahmedabad, Gujarat, <sup>2</sup>Lok Nayak Hospital, New Delhi, Delhi, <sup>3</sup>All India Institute of Medical Sciences, Bhopal, Madhya Pradesh, <sup>4</sup>Guru Gobind Singh Government Hospital, New Delhi, Delhi, India

**Received:** 12 March 2017

**Revised:** 29 March 2017

**Accepted:** 30 March 2017

### \*Correspondence:

Dr. Nishit Bhatnagar,

E-mail: [nishitbhatnagar@yahoo.co.in](mailto:nishitbhatnagar@yahoo.co.in)

**Copyright:** © the author(s), publisher and licensee Medip Academy. This is an open-access article distributed under the terms of the Creative Commons Attribution Non-Commercial License, which permits unrestricted non-commercial use, distribution, and reproduction in any medium, provided the original work is properly cited.

## ABSTRACT

**Background:** Indiscriminate use of intra-operative fluoroscopy can incur harm both to the patient as well as the surgeons. Orthopedic surgeons seldom do skin marking prior to cleaning and draping of the operative site. This study aims to study the feasibility and utility of pre-operative skin marking with henna in conjunction with marker radiograph.

**Methods:** Out of 54 patients undergoing spine surgery, vertebral level localization was done by fluoroscopy in 26 patients. In the rest of the 28 patients, preoperative marker radiograph with steel wires was taken in conjunction with henna line markings on the skin. These were correlated for vertebral level localization. Difference in time taken for vertebral localization by these two methods, and the difference in the number of fluoroscopic images required was observed and recorded.

**Results:** Approximately 4 minutes were needed for level localization via fluoroscopic technique, whereas the henna marking technique did this in approximately 30 seconds. No adverse effects of henna application were observed during the study.

**Conclusions:** The use of preoperative skin marking with henna along with the appropriate marker radiograph can reduce the surgical time and radiation exposure without increasing the chances of a wrong level surgery in the spine.

**Keywords:** Henna, Skin marking, Spine surgery, Vertebral localisation

## INTRODUCTION

All orthopedic procedures must be precisely targeted to be effective. Any deviation from the target point means that the procedure will damage healthy tissue. There is a growing tendency to become over dependent on the use of intraoperative fluoroscopy for identifying the precise site of incision or intervention. Indiscriminate use of intra-operative fluoroscopy can incur harm both to the patient as well as the surgeons.

One of the commonest causes of indiscriminate use of fluoroscopy is to mark the exact level of surgery or site of incision. Also, the option of intra-operative fluoroscopy is not available in many centers around the world, especially in the developing world. This presents us with a challenge to mark the skin exactly at the targeted area pre-operatively.

There have been multiple methods used to mark the skin for this purpose. Pen markers, henna and permanent tattooing, all have their advantages and disadvantages.<sup>1</sup>

Orthopaedic surgeons seldom do skin marking prior to cleaning and draping of the operative site. This study aims to study the feasibility and utility of pre-operative skin marking with henna in conjunction with marker radiograph.

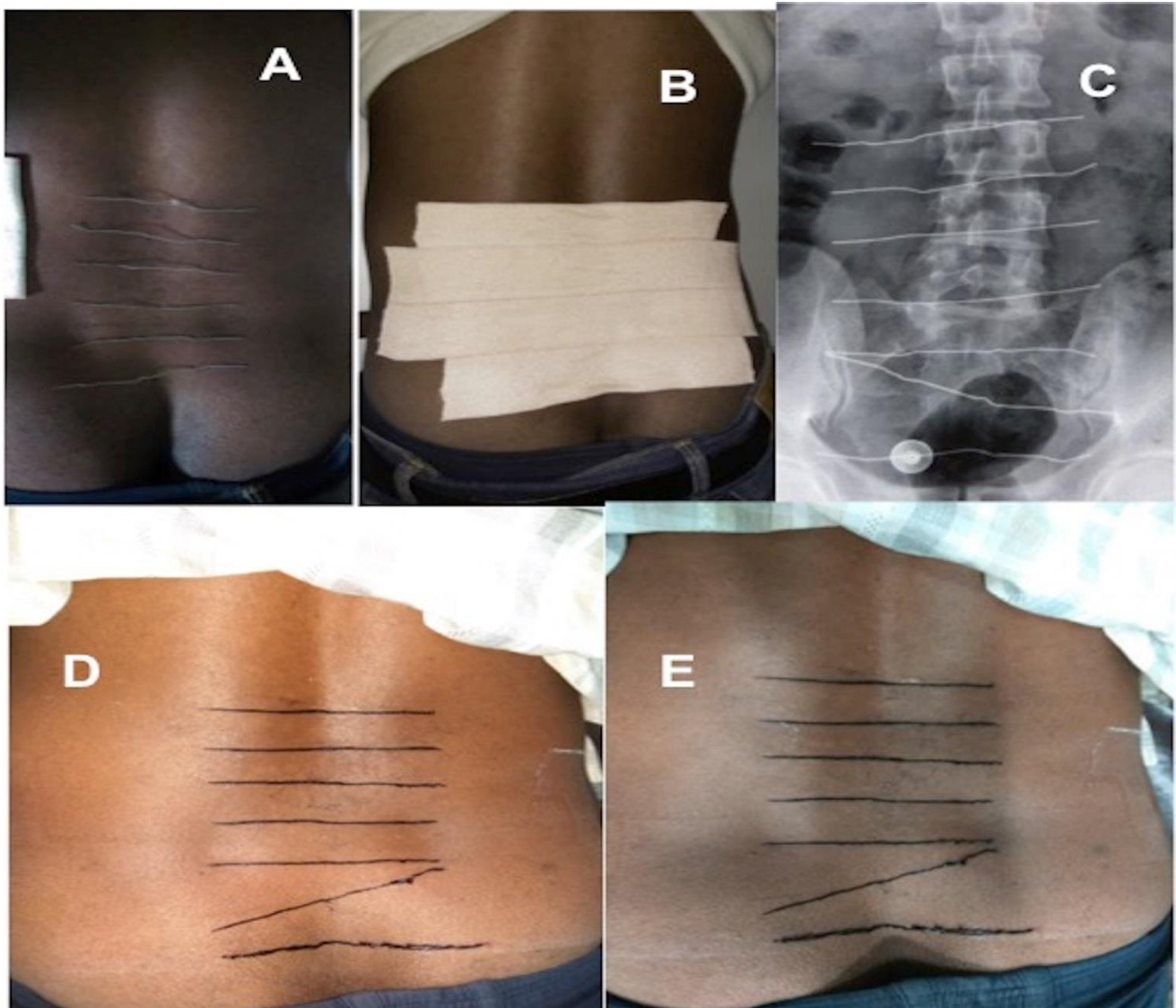
## METHODS

The study was conducted at a tertiary level referral hospital and teaching institute from January 2012 to January 2015. All patients that were to undergo surgery via posterior midline approach on the thoraco-lumbar spine were included in the study. Patients who were unwilling to participate and those with known allergy to henna were excluded from the study.

The patients were randomly divided into two groups, A and B. Patients in Group A underwent surgery without

prior marking of skin with henna. The skin incision was made after taking fluoroscopic images and identifying the level of pathology. This was done by inserting a needle in the posterior midline at the anticipated level of pathology. The vertebral level was confirmed either by counting the vertebrae from a known bony landmark, like the sacrum or by directly visualizing the pathological vertebrae on the fluoroscopic image. In Group B, patients underwent the process of pre-operative henna marking and a marker radiograph was obtained (technique described below). Incision was given without confirmation of site on fluoroscopy.

Written, informed consent was obtained from each of the patients authorizing treatment, henna application, photographic documentation and radiographic examination. Institutional review board and Ethical committee clearance was obtained.



**Figure 1: Steps of preoperative skin marking.**

(A) Placement of steel wires on proposed site. (B) Application of adhesive tape over steel wires. (C) Marker radiograph. (D) Adhesive tape removed and the indentations made by wires on skin marked with henna paste. (E) Remnant dark brown pigmentation left behind after drying of henna paste.

The area of interest was first marked using a flexible stainless steel wire (Figure 1). The wires were placed on the back, in a grid like fashion for lumbar spinal pathologies and along the ribs for thoracic pathologies. Adhesive bandage was applied across the wires to prevent their movement. Orthogonal radiographs of the site of interest were taken. When the adhesive bandage was removed, the indentations of the wires on the skin were marked with henna. The henna markings were then allowed to dry for two hours and shed off. After shedding off it leaves behind orange to dark brown pigmentation of the skin, which corroborates with the radiopaque wires seen on the radiograph. By correlating the site of the pathology with respect to the grid wire markers on the radiograph we can mark the site of skin incision as per the grid henna marking.

Data regarding the vertebral level of pathology, time spent in trying to localize the site of incision and number of fluoroscopic images taken to localize the site of incision was recorded.

The aim of the study was to compare the feasibility and utility of using preoperative henna skin markings. Statistical analysis was performed with Statistical Package for Social Sciences (SPSS, version 16, Chicago, US) for windows. Unpaired Students t-test was used for calculation of p value. P value of less than 0.05 was considered to be statistically significant.

## RESULTS

Out of a total of 54 patients included in the study, 26 belonged to Group A (no skin marking) and 28 to Group B (henna skin marking). Ten patients had tuberculosis of the spine and underwent decompression surgery via posterior midline approach, with or without instrumentation. Discectomy via fenestration was performed on 18 patients. Two patients underwent Transforaminal lumbar interbody fusion. The rest (24) underwent posterior spinal instrumentation for traumatic vertebral fractures. The two groups were comparable in terms of distribution of types of surgery between the two ( $p = 0.88$ ). The groups were also comparable in terms of distribution of level of lesion ( $p = 0.9$ ). The results are summarized in Table 1.

There was no incidence of surgery being done at the wrong vertebral level in either group. For patients in Group A, a mean of 4.4 (range, 1 to 12) fluoroscopic images were required to localize the pathological site and give the skin incision. After draping of the surgical site, the mean time spent to localize the pathological site prior to skin incision, was 4 minutes and 8 seconds (range, 52 seconds to 9 minutes and 16 seconds). For Group B, skin incision was made without obtaining fluoroscopy images for confirmation of vertebral level. After draping the mean time spent to localize the pathological site as per the henna markings was 24 seconds (range, 10 seconds to

55 seconds). These results are summarized in Table 2.

The results were also analyzed separately for lumbar and thoracic spine surgeries. It revealed that in Group A, a mean of 3.2 fluoroscopy images were needed in lumbar spine, whereas a mean of 8.6 images were required for localization in thoracic spine surgeries. Similarly the mean time required for localization in lumbar spine was 2 minute and 23 seconds, whereas in thoracic spine it was 6 minutes and 45 seconds. In Group B, mean time required for localization in lumbar and thoracic spine was 18 seconds and 33.2 seconds, respectively.

**Table 1: Comparison of both groups.**

Surgery	Group A	Group B
Discectomy	8	10
Traumatic fracture stabilization	13	11
Decompression for tuberculosis	4	6
Interbody fusion	1	1
<b>Level</b>		
Upper dorsal (D1-D6)	1	2
Mid dorsal (D7-D9)	3	4
Lower dorsal (D10-D12)	6	5
Lumbar	16	17

**Table 2: Comparison of the two techniques of localization in thoracic and lumbar spine.**

	Group A	Group B	P value
<b>Number of fluoroscopy images required</b>	4.4	-	-
Thoracic spine	8.6	-	-
Lumbar spine	3.2	-	-
<b>Average time for localization (seconds)</b>	248	24	0.0001
Thoracic spine	405	33.2	0.0001
Lumbar spine	143	18	0.0001

The difference in time required for localization in Group A (without henna) was significantly more for thoracic level pathologies, than lumbar pathologies ( $P < 0.0001$ ). The difference in time required for localization in Group B (with henna) was also statistically significant ( $P = 0.008$ ). Hence, time required for localization of level in thoracic spine was significantly more, when done by either method.

We observed no allergic reaction to henna in our patients. The henna skin marking was readily visible on the skin even after vigorous pre-operative skin preparation with chlorhexidine gluconate and cetrimide combination (Savlon) followed by alcohol based scrubs. Post-operatively the henna marking faded away in all patients within 3 weeks of application.

**Table 3: Recent literature on the use of henna for skin markings.**

Author, Year	Department	Use of henna
Wurstbauer <sup>11</sup> 2001	Radiotherapy	Marking skin to increase accuracy of radiation delivery
Puri <sup>10</sup> 2006	Plastic Surgery	For perforator based flaps, doppler ultrasound located the perforators, which are then marked by henna
Rafi <sup>19</sup> 2009	Radiotherapy	Comparison of different techniques of skin markings
Mehendale <sup>9</sup> 2010	General Surgery	For marking stoma sites, sites of liver aspiration, perforators while planning varicose surgery, inguinal hernia sites
Griffiths <sup>20</sup> 2012	Radiography	Marking of breast, prior to surgery for breast disease
Rathod <sup>1</sup> 2012	Radiation Oncology	Comparison of different techniques of skin markings for focused radiotherapy

## DISCUSSION

Radiation exposure is a well known health hazard for the orthopedic surgeon. The exposure to radiation during fluoroscopically-assisted musculoskeletal procedures has been evaluated previously.<sup>2</sup> Fluoroscopy may produce a high dose of radiation (as much as 0.004 Gy/min or 5 rads/min).<sup>3,4</sup> The average environmental radiation dose from cosmic rays, external sources, and ingested radioactive materials is approximately 3 mSv per year.<sup>5</sup> Singh et al showed an exposure to 80% additional dose of radiation for orthopaedic surgeons.<sup>5</sup>

The major concern with long-term exposure to low-level radiation is induction of malignancy.<sup>6</sup> Five cases of malignancy were reported over 7 years in an orthopaedic hospital in Italy, where radiation protection practice was poor.<sup>7</sup> Despite all the biosafety equipment such as lead aprons, protective collars and goggles, the cumulative deleterious effects of radioactivity cannot be neglected. Hence alternative methods to decrease exposure to radiation must be undertaken. One of these is to decrease the use and need for fluoroscopy by thorough pre-operative planning. A commonly followed example is the pre-operative measurement of intra-medullary nail length and diameter. Our study focussed on another aspect of spinal surgery, determination of vertebral level.

In an environment of rising litigation, operating on the wrong vertebral level can be disastrous for the patient and the surgeon. Judgement of vertebral level by palpation of spinous processes can be imprecise, especially in the elderly and obese patients where landmarks such as Tufflers line are not reliable.<sup>8</sup> Use of ultrasound for localizing vertebral level has been explored, but is not feasible and reliable.<sup>8</sup> Hence, surgeons take the safe and often necessary route of vertebral level localization under fluoroscopic image guidance.

Our study was conducted with the aim of finding an accurate method of vertebral level localization without use of a fluoroscope.

Pre-operative skin marking is a widely accepted and practiced component of pre-operative planning done by plastic surgeons and vascular surgeons.<sup>9</sup> It has been used to mark the site of vessels, nerves, proposed flaps.<sup>9,10</sup> It is

also commonly done by oncologists for marking the site prior to radiotherapy.<sup>11</sup> An ideal skin marker should be easily available, inexpensive, visible even after skin preparation and should not have any untoward side effects. The three commonly used methods are marker pens, tattoos and henna.<sup>11</sup>

Traditionally commercially available marking pens were used for pre-operative skin marking due to ease of application. However, skin preparation and scrubbing leads to fading or smudging of the markings. There is also no reliable way of sterilizing the pens. This increases the chances of infection, in fact there are reported cases of cross infection between patients in whom the same marking pen was used.<sup>12,13</sup> Tattoos are painful, invasive and serve as a permanent reminder of surgery. Tattoos do not have widespread social acceptance.

Henna paste (also known as mehendi) is made from the leaves of the plant *Lawsonia inermis*. It has been used in the Indian subcontinent from ancient times for dyeing hair, nails and making temporary decorations on hands and feet. It is an ideal substance for use as a pre-operative skin marker. It is safe, inexpensive, readily available, durable and allows routine pre-operative bathing for appropriate surgical hygiene. It is available in squeezable plastic cones for application that cost around 0.2 – 0.3 USD (United States Dollar). The part has to be left undisturbed for around 1 hour after application of paste. The paste dries and falls off, leaving behind a deep orange/brown stain in the skin, which fades away in 2 to 3 weeks' time. Even vigorous preoperative skin scrubbing with ethanol-based agents do not alter or fade the henna markings.<sup>9,10</sup> Additionally, extract from *L. inermis* has been shown to have anti-bacterial properties and promotes wound healing.<sup>14,15</sup>

Henna does have a drawback, that it can cause hemolysis in patients with Glucose-6-phosphate dehydrogenase enzyme deficiency.<sup>16,17</sup> Additives like P-phenylenediamine (PPD) is often added to henna to produce a black color. This has been reported to cause allergic reactions in some individuals.<sup>18</sup> Fortunately we found no incidence of infection or any dermatological complication or any hypersensitivity reaction in any of our case. The only problem we faced was localizing appropriate sites in patients having lax and mobile skin.

Another drawback of the henna method of skin marking is that, the process is time consuming and might not be socially or culturally acceptable in some communities or amongst males.

Henna skin marking is a tried and tested method in other medical fields (Table 3). However, the use of preoperative henna skin markings has not been explored in the field of orthopedics yet. At our center, we have also ventured into using henna skin markings in conjunction with marker radiographs for localizing and excising sequestrum, osteoid osteoma, metallic foreign bodies and broken screw without the use of fluoroscopy.

## CONCLUSION

The use of preoperative skin marking with henna along with the appropriate marker radiograph can reduce the surgical time and radiation exposure without increasing the chances of a wrong level surgery in the spine.

*Funding: No funding sources*

*Conflict of interest: None declared*

*Ethical approval: The study was approved by the institutional ethics committee*

## REFERENCES

- Rathod S, Munshi A, Agarwal J. Skin markings methods and guidelines: A reality in image guidance radiotherapy era. *South Asian J Cancer*. 2012;1:27-9.
- Theocharopoulos N, Perisinakis K, Damilakis J, Papadokostakis G, Hadjipavlou A, Gourtsoyiannis N. Occupational exposure from common fluoroscopic projections used in orthopaedic surgery. *J Bone Joint Surg Am*. 2003;85(9):1698-703.
- Hanel DP, Robson DB. The image intensifier as an operating table. *J Hand Surg Am*. 1987;12(2):322-3.
- Antoku S, Russell WJ. Doses to the active bone marrow, gonads and skin from roentgenography and fluoroscopy. *Radiology*. 1971;101:669-78.
- Singh PJ, Perera NS, Dega R. Measurement of the dose of radiation to the surgeon during surgery to the foot and ankle. *J Bone Joint Surg Br*. 2007;89(8):1060-3.
- Jablon S, Bailar J. The contribution of ionizing radiation to cancer mortality in the United States. *Prev Med*. 1980;9:219-26.
- Mastrangelo G, Fedeli U, Fadda E, Giovanazzi A, Scoizzato L, Saia B. Increased cancer risk among surgeons in an orthopaedic hospital. *Occup Med (Lond)* 2005;55(6):498-500.
- Chun EH, Kim JE, Kim DY, Kim YJ, Kim JH, Chung RK, et al. Ultrasound measurement of the vertebral level of Tuffier's line in elderly women. *Korean J Anesthesiol*. 2016;69(5):474-9.
- Mehendale VG, Chaudhari NC, Shenoy SN, Mehendale AV. Henna as a durable preoperative skin marker. *World J Surg*. 2011;35(2):311-5.
- Puri VA, Mahendru S, Rana RE. Use of henna as a skin marker. *J Plast Reconstr Aesthet Surg*. 2006;59(10):1123-4.
- Wurstbauer K, Sedlmayer F, Kogelnik HD. Skin markings in external radiotherapy by temporary tattooing with henna: improvement of accuracy and increased patient comfort. *Int J Radiat Oncol Biol Phys*. 2001;50(1):179-81.
- Tadiparthi S, Shokrollahi K, Juma A, Croall J. Using marker pens on patients: a potential source of cross infection with MRSA. *Ann R Coll Surg Engl*. 2007;89:661-4.
- Ballal MS, Shah N, Ballal M, O'Donoghue M, Pegg DJ. The risk of cross- infection when marking surgical patients prior to surgery — review of two types of marking pens. *Ann R Coll Surg Engl*. 2007;89:226-8.
- Nayak BS, Godwin I, Davis EM, Pillai GK. The evidence based wound healing activity of *Lawsonia inermis* linn. *Phytotherapy Res*. 2007;21:827-31.
- Al-Rubiay KK, Jaber NN, Al-Mhaawe BH, Alrubaiy LK. Antimicrobial Efficacy of Henna Extracts. *Oman Medical Journal*. 2008;23(4):253-6.
- Ko'k AN, Ertekin MV, Ertekin V. Henna (*Lawsonia inermis* Linn.) induced haemolytic anaemia in siblings. *Int J Clin Pract*. 2004;58:530-2.
- Zinkham WH, Oski FA. Henna: a potential cause of oxidative hemolysis and neonatal hyperbilirubinemia. *Pediatrics*. 1996;97:707-9.
- Lauchli S, Lautenschlager S, Lauchl S. Contact dermatitis after temporary henna tattoos – an increasing phenomenon. *Swiss Med Wkly*. 2001;131:199-202.
- Rafi M, Tunio MA, Hashmi AH, Ahmed Z. Comparison of three methods for skin markings in conformal radiotherapy, temporary markers, and permanent Steritatt CIVCO® tattooing: patients' comfort and radiographers' satisfaction: peer reviewed opinion article. *South African Radiographer*. 2009;47(2):20-2.
- Griffiths A, Murphy F. The use of henna as an alternative skin marker in breast disease. *Radiography*. 2012;18(4):279-86.

**Cite this article as:** Thora A, Bhatnagar N, Tiwari A, Lingaiah P, Rustagi N. Use of henna as a durable pre-operative skin marker for accurate localisation of vertebral level in spine surgery. *Int J Res Orthop* 2017;3:461-5.