

## Original Research Article

# Intra articular distal radius fractures and volar plate fixation: a prospective study

Atin Kumar Kundu, Nitin Wale, Satyendra Phuljhele, Deepak Ghrtilahre,  
Harjot Singh Gurudatta\*

Department of Orthopaedics, Pt JNM Medical College, Raipur, Chhattisgarh, India

**Received:** 21 February 2017

**Accepted:** 31 March 2017

### \*Correspondence:

Dr. Harjot Singh Gurudatta,

E-mail: [harjotgurudatta@gmail.com](mailto:harjotgurudatta@gmail.com)

**Copyright:** © the author(s), publisher and licensee Medip Academy. This is an open-access article distributed under the terms of the Creative Commons Attribution Non-Commercial License, which permits unrestricted non-commercial use, distribution, and reproduction in any medium, provided the original work is properly cited.

## ABSTRACT

**Background:** Despite being one of the most common fractures encountered in patients, intra-articular distal radius fractures still pose therapeutic challenge to Orthopaedic surgeons. With the advent of locking plates, the fixation of these fractures has been made better, specifically by fixed angle volar locking plate. This study investigates the efficacy of these plates using volar approach, functional and clinical outcome, in addition to the radiological alignment.

**Methods:** Thirty patients with closed distal radius fractures, with AO TYPE B3, B4, AND C fracture pattern, operated with distal radius plate fixation using volar approach, were included in the study during the period of August 2014 to August 2016. With a minimum follow up of six months, radiological outcome was analysed and functional outcome recorded (Gartland and Werley's demerit scoring system).

**Results:** With a mean age of 42 years and follow up of six months, the range of movement of the wrist was very satisfactory, and the mean grip strength was 80% of the opposite wrist. Radiological parameters were well-maintained, and functional parameters by Gartland and Werley showed a significant improvement in most of the patients during the follow-up period. The complication rate was less and insignificant.

**Conclusions:** Primary volar plate fixation of intraarticular distal radius fracture provides a stable construct that helps in early mobilization, thereby better functional outcomes and minimizes chances of delayed/malunion.

**Keywords:** Volar plate, Distal radius, Gartland and Werley, Wrist

## INTRODUCTION

Constituting around 10 % of the total skeletal trauma, involving both the elderly and young patients, distal end radius fractures, which can be extra or intra articular, has been treated with various modalities. Conservative treatment has been in practice since time immemorial.<sup>1</sup> However, with enhanced anatomical learning and advent of increased operative approaches and implants, distal end radius, particularly involving articular surface, have increasingly being operated.

Restoration of volar angulation, radial length, and radial inclination are essential for good functional outcomes at

the wrist joint. Maintenance of articular congruity and stable fixation reduce the incidence of osteoarthritis and also help with earlier rehabilitation. Various treatment modalities, including plaster cast application, kirschner wire fixation, dorsal and volar plates, and external fixation, have been described for the management of these fractures.

Intra-articular fractures of the distal radius represent a therapeutic challenge as compared with unstable extra-articular fractures.<sup>2</sup> Apart from being more difficult to reduce and stabilize with internal fixation, these injuries frequently result in malunion, which may result in a less satisfactory long-term functional outcome, if not anatomically reduced.<sup>3,4</sup> In the past, these fractures were

managed with external fixation or a combination of limited open reduction, kirschner wire (K-wire) augmentation, and bone grafting.<sup>5</sup> However, with the development of specifically designed locking implants for the distal radius, Open reduction and internal fixation (ORIF) using volar fixed-angle plates has also shown to be a valid treatment option for unstable, intra-articular displaced distal radial fractures, more so in osteoporotic bones.<sup>6</sup>

Open reduction and volar plating ensures more consistent correction of displacement and maintenance of reduction. This study evaluates the anatomical, clinic-radiological and functional outcome of open reduction and plate fixation in the management of fracture distal end radius.

## METHODS

Thirty patients with unstable distal radial fractures treated with locked volar plating at the institute from August 2014 until August 2016 was included for the study. Patients treated with closed reduction and cast application, more than three weeks old trauma, compound fractures or those with ipsilateral upper limb fractures were excluded from the study. Skeletally mature patients with modified AO type b3, b4, and c with volar fragment with less than three weeks old trauma were included in the study. Due ethical committee was obtained.

**Table 1: Reduction assessment criteria.**

Guidelines for acceptable reduction of distal radius fractures <sup>18</sup>	
1. Radial shortening <5 mm at the DRUJ compared with the contralateral side	
2. Radial inclination on posteroanterior radiographs >15°	
3. Sagittal tilt on the lateral projection between 15° dorsal tilt and 20° volar tilt	
4. Intra-articular step-off or gap <2 mm of the radiocarpal joint <sup>10</sup>	
5. Articular incongruity <2 mm of the sigmoid notch of the distal radius	

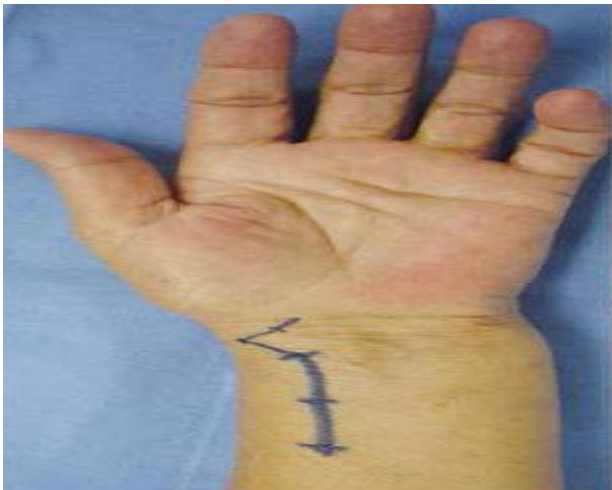**Table 2a: Demerit point system of Gartland and Werley.**

Element	Result	Points
<b>Residual deformity</b>	None	0
	Prominent ulnar styloid	1
	Residual dorsal tilt	2
	Radial deviation of hand, mild to moderate	2
	Radial deviation of hand, severe	3
<b>Subjective evaluation</b>	No pain, disability, or limitation of motion (excellent)	0
	Occasional pain, slight limitation of motion, no disability (good)	2
	Occasional pain, some limitation of motion, feeling of weakness in wrist, no particular disability if careful, activities slightly restricted (fair)	4
	Pain, limitations of motion, disability, activities more or less markedly restricted	6
<b>Objective evaluation</b>	No loss or pain	0
	Loss of dorsiflexion	5
	Loss of ulnar deviation	3
	Loss of supination	2
	Loss of palmar flexion	1
	Loss of radial deviation	1
	Loss of circumduction	1
	Pain in distal radio-ulnar joint	1
<b>Arthritic complications</b>	None	0
	Minimal	1
	Minimal with pain	3
	Moderate	2
	Moderate with pain	4
	Severe	3
	Severe with pain	5
<b>Nerve complications</b>	None	0
	Mild	1
	Moderate	2
	Severe	3
<b>Poor finger function due to cast</b>	None	0
	Minimal to mild	1
	Moderate to severe	2

**Table 2b: Demerit point system of Gartland and Werley with scores and outcome.**

Score (max 24)	Outcome
0 to 2	Excellent
3 to 8	Good
9 to 20	Fair
21 to 24	Poor

After the patients presented to the hospital, they were vitally stabilized and assessed for associated injuries or systemic comorbidities. Anteroposterior and lateral views radiographs were taken and classified as per AO classification. Due medical fitness was obtained and skin condition assessed before posting the patient for surgery. Patient was operated under block or general anaesthesia with fluoroscopy assistance.



**Figure 1: Standard Henry approach incision.**

For surgery, standard Henry volar approach was used utilizing the plane between brachioradialis and flexor carpi radialis longus (Figure 1). Intraoperatively reduction was assessed under fluoroscopy (Table 1).

A volar splint was applied for two weeks till suture removal, followed by which regular wrist physiotherapy was initiated. Patients were followed up at 6 weeks, 3 months, 6 months and assessed clinically with recording of functional status by Gartland and Werley scale (Table 2). Radiographs were obtained on every visit and reduction parameters as well as status of bony union were assessed, along with comparison with radiograph from previous visit.

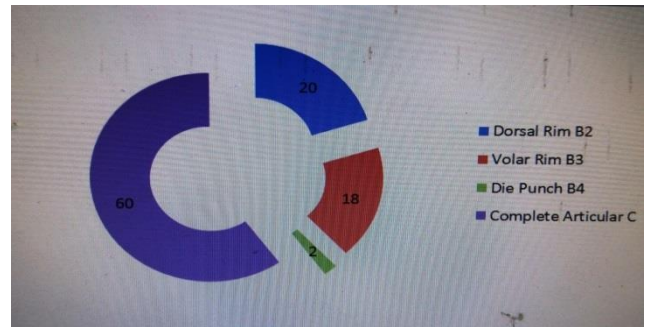
**RESULTS**

There were 30 patients treated with volar locking plate system in this study. 14 male and 16 female patients with the average age of 42 (range 18-64) and right side predilection. The patients were followed up for a period of six to twelve months (minimum six months). All

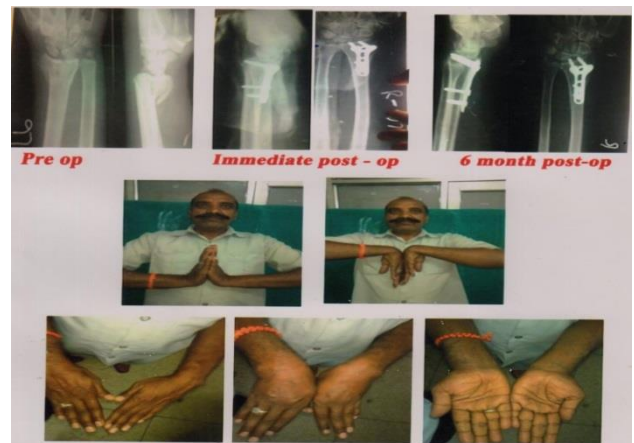fractures were closed and classified according to the AO/OTA classification (Figure 2).

In our study 60% of cases were of type C of AO classification and 20% cases were of B2 and 18% cases were of B3 type.

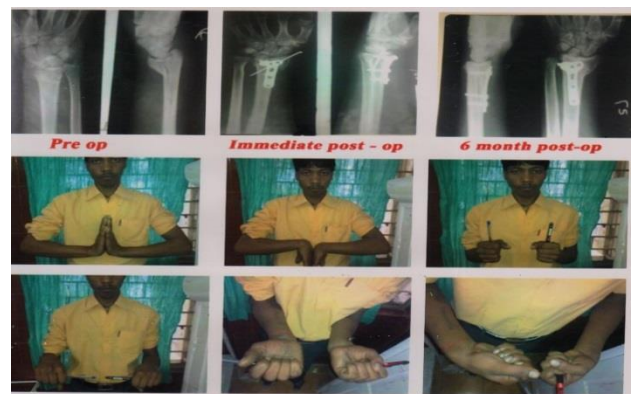The mean time to union was eight weeks (range 6-12 weeks). At the time of final follow-up (minimum six months) the clinical scoring chart was done according to Gartland and Werley scale (Table 4).



**Figure 2: Chart showing AO classification.**



**Figure 3: Preoperative and postoperative clinical and radiological pictures of patient.**



**Figure 4: Preoperative and postoperative clinical and radiological pictures of patient.**

Gartland and Werley scores in the study, with 86% of patients having good to excellent results.

Radiographs and clinical anatomy was analysed as per Sarmientos modification of Lindstorm Criteria (Table 5). At final follow-up, the average volar tilt was 6.7° (range, 2° of dorsal tilt to 15° of volar tilt), radial inclination averaged 20.2° (range, 12–28°) and radial shortening averaged 0.7 mm (range, 0–2 mm). The loss of volar tilt

and trauma surgery interval correlated inversely to the functional outcome significantly (p value<0.05).

There were two cases of superficial wound infection that settled well with oral antibiotics. No patients had complex regional pain syndrome or non-union and none had extensor tendon irritation or ruptures. Residual pain, stiffness and deformity were there are about ten percent of the patients.

**Table 4: Outcome based on Gartland and Werley scale.**

S.no	Outcome	Number of patients	%
1	Excellent (0 to 2)	21 (mean- 1.21 SD 0.63)	70
2	Good (3 to 8)	5 (mean- 4.2 SD 1.64)	16
3	Fair (9 to 20)	4 (mean- 16 SD 1.63)	14
4	Poor (21 to 24)	0 (mean 0 SD 0)	0

**Table 5: Anatomical and radiological evaluation using Sarmientos modification of Lindstorm criteria.**

	Residual deformity	Loss of palmar inclination	Radial shortening (mm)	Loss of radial deviation	Mean
<b>Excellent</b>	24 (80%)	20 (66%)	16 (53%)	12 (40%)	18 (60%)
<b>Good</b>	12 (40%)	8 (26%)	13 (43%)	7 (23%)	10 (33%)
<b>Fair</b>	0	0	0	0	0
<b>Poor</b>	2 (7%)	2 (7%)	2 (7%)	2 (7%)	2 (7%)

## DISCUSSION

In treating intra articular distal radial fractures, the main aim is to achieve and maintain anatomic reduction and get satisfactory function and rehabilitation. The biomechanical results show that locking volar plates provides significantly greater resistance to fracture gap motion compared with standard volar plates in a dorsally comminuted distal radius fractures.<sup>7</sup> Fixed-angle volar plates prove stronger under cyclical loading tests and locking screws help in attaining implant stability and in addition, spares the vascularity and periosteum.<sup>8</sup>

Although there are few complications associated with volar locking plate system but are less as compared to dorsal plating even for dorsal comminuted fractures. In the study by Ruch and Papadonikolakis, the volar collapse occurred regardless of the type of dorsal plate used and that volar plating was associated with fewer complications than dorsal plating.<sup>9</sup> In the dorsal plating group there was a statistically significant association of volar collapse of the distal fragment when the distal screws were pointing proximally.

Volar plating for dorsally displaced, unstable fractures of the distal radius has several advantages compared with dorsal plating. The volar approach, fracture reduction, and volar plating techniques are easier than dorsal plating. Volar plating preserves vascular supply to dorsal metaphyseal fragments and does not cause extensor tendon problems.<sup>10</sup> When the quality of the pronator quadratus muscle is good, volarly placed plates are

almost covered with the pronator quadratus except the distal edge of the plate.<sup>11</sup>

Rozental et al reported patients treated with volar fixed-angle plating for unstable distal radius fractures, with average follow-up period of 17 months.<sup>12</sup> The radiological parameters in this study with volar tilt of 6.7 degrees and radial inclination 20 degrees was about in the same range as Rozental et al and also by Lueng et al.<sup>13</sup> In most cases effective restoration of anatomic alignment was acquired and maintained, along with functional restoration and rehabilitation.

Grip strength and adequate wrist movements were attained at end of six months.

Anakwe et al in their study also reported similar outcomes being described by the patients.<sup>14</sup> MacDermid et al reported that patients with distal end radius fractures achieve the majority of their grip strength and movement in six months.<sup>15</sup> In their large series of 170 patients with distal end radius fractures, Kanabar et al. noticed that parameters such as range of motion and grip strength were regained by up to 94% in the three months after volar plating.<sup>16</sup> Also, the shorter the trauma surgery interval and better achievement of volar tilt resulted in better functional outcome as also found in study by Phadnis et al.<sup>17</sup>

The overall complication rate in our study was 18%, which is comparable to that reported by Jagodzinski et al in a bicentric study on distal radius variable angle locking



plates.<sup>18</sup> They reported a complication rate of 19.6%, although the majority had screw misplacement, while Kawasaki et al had no reported cases of screw misplacement.<sup>19</sup> In our study, there was only no case of screw misplacement because extra care was taken to prevent this complication since it could have resulted in longer fluoroscopy time. Similar studies were conducted to compare complications in locked volar plating versus pinning and external fixation in the treatment of unstable intra-articular distal radius fractures and gave similar findings as ours. They also concluded that volar locked plating is a boon for unstable fractures because of its stiffer construct and lower rates of complications.<sup>20,21</sup> No complications pertaining to extensor tendons was observed in this study. Similar conclusion was reached in separate studies by Hakim et al and Othman.<sup>22,23</sup>

This study is not immune to limitations. This study was a single centric study with limited number of cases and no control group or other modes of fixation for comparison. Further analysis and work will help to delineate the strategy in distal radius plating to avoid complications and adverse outcomes.

## CONCLUSION

Volar locking plate fixation for intra-articular distal end radius fracture is a vital mainstay in management of these fractures with good outcome and limited complications.

*Funding: No funding sources*

*Conflict of interest: None declared*

*Ethical approval: The study was approved by the college ethical committee*

## REFERENCES

- Xavier CR, Dal Molin DC, Dos Santos RM, Dos Santos RD, Neto JC. Surgical Treatment of Distal Radius Fractures with a Volar Locked Plate: Correlation of Clinical and Radiographic Results. *Rev Bras Ortop.* 2011;46(5):505–13.
- Cooney WP III, Linscheid RL, Dobyns JH. External pin fixation for unstable Colles' fractures. *J Bone Joint Surg Am.* 1979;61(6):840–5.
- Arora R, Lutz M, Deml C, Krappinger D, Haug L, Gabl M. A prospective randomized trial comparing nonoperative treatment with volar locking plate fixation for displaced and unstable distal radial fractures in patients sixty-five years of age and older. *J Bone Joint Surg Am.* 2011;93(23):2146–53.
- Trumble TE, Schmitt SR, Vedder NB. Factors affecting functional outcome of displaced intra-articular distal radius fractures. *J Hand Surg Am.* 1994;19(2):325–40.
- Wolfe SW, Pike L, Slade JF III, Katz LD. Augmentation of distal radius fracture fixation with coralline hydroxyapatite bone graft substitute. *J Hand Surg Am.* 1999;24(4):816–27.
- Medoff RJ. Fragment-specific fixation of distal radius fractures. *Atlas of the Hand Clinics.* 2006;11(2):163–74.
- Willis AA, Kutsumi K, Zobitz ME, Cooney WP. Internal fixation of dorsally displaced fractures of the distal part of the radius: A biomechanical analysis of volar plate fracture stability. *JBJS Am.* 2006;88(11):2411-7.
- Nana AD, Joshi A, Lichtman DM. Plating of the Distal Radius. *J Am Acad Orthop Surg.* 2005;13(3):159-71.
- Ruch DS, Papadonikolakis A. Volar versus dorsal plating in the management of intra-articular distal radius fractures. *J Hand Surg Am.* 2006;31:9–16.
- Osada D, Kame Si, Masuzaki K, Takai M, Kameda M, Tamai K. Prospective Study of Distal Radius Fractures Treated With a Volar Locking Plate System. *J Hand Surg.* 2008;33:691-700.
- Chung KC, Petruska EA. Treatment of unstable distal radius fractures with locking plating system. Surgical technique. *J Bone Joint Surg.* 2007;89 Suppl 2:256-66.
- Rozental TD, Blazar PE. Functional outcome and complications after volar plating for dorsally displaced, unstable fractures of the distal radius. *J Hand Surg Am.* 2006;31:359-65.
- Leung F, Zhu L, Ho H, LuWW, Chow SP. Palmar plate fixation of AO type C2 fracture of distal radius using a locking compression plate--a biomechanical study in a cadaveric model. *J Hand Surg Br.* 2003;28:263-6.
- Anakwe R, Khan L, Cook R, McEachan J. Locked volar plating for complex distal radius fractures: Patient reported outcomes and satisfaction. *J Orthop Surg Res.* 2010;5:51.
- MacDermid JC, Roth JH, Richards RS. Pain and disability reported in the year following a distal radius fracture: a cohort study. *BMC Musculoskelet Disord.* 2003;4:24.
- Kanabar P, Mirza S, Hallam P, Cooper A. Volar locking plate for distal radius fractures: does it do what it says on the box? A radiological review of 170 consecutive distal radius fractures treated with a volar locking plate. *J Bone Joint Surg Br.* 2011;93.
- Phadnis J, Trompeter A, Gallagher K, Bradshaw L, Elliott DS, Newman KJ. Mid-term functional outcome after the internal fixation of distal radius fractures. *J Orthop Surg Res.* 2012;7:4.
- Jagodzinski NA, Singh T, Norris R, Jones J, Power D. Early results of a variable-angle volar locking plate for distal radius fractures: A bi-centre study. *Orthopaedic Proceedings;* 2012.
- Kawasaki K, Nemoto T, Inagaki K, Tomita K, Ueno Y. Variable-angle locking plate with or without double-tiered subchondral support procedure in the treatment of intra-articular distal radius fracture. *J Orthop Traumatol.* 2014;15(4):271–4.
- Khan SM, Saxena NK, Singhania SK, Gudhe M, Nikose S, Arora M, et al. Volar plating in distal end radius fractures and its clinical and radiological

- outcome as compared to other methods of treatment. *J Orthop Allied Sci.* 2016;4:40-4.
21. Rizzo M, Katt BA, Carothers JT. Comparison of locked volar plating versus pinning and external fixation in the treatment of unstable intraarticular distal radius fractures. *Hand.* 2008;3:111-7.
  22. Hakimi M, Jungbluth P, Windolf J, Wild M. Functional results and complications following locking palmar plating on the distal radius: a retrospective study. *Journal Hand Surg.* 2010;35(4):283-8.
  23. Othman AY. Fixation of dorsally displaced distal radius fractures with volar plate. *J Trauma* 2009;66:1416-20.

**Cite this article as:** Kundu AK, Wale N, Phuljhele S, Ghritlahre D, Gurudatta HS. Intra articular distal radius fractures and volar plate fixation: a prospective study. *Int J Res Orthop* 2017;3:589-94.