

Original Research Article

Ultrasound guided platelet rich plasma or corticosteroid for supraspinatus tendonosis or partial tear: an observational study of clinical outcome

Tirthankar Dasgupta¹, Mainak Das², Tushar Gogia¹, Narender Singh^{1*},
Aashish Tiwary³, Vaibhav Verma¹

¹Department of Orthopaedic Surgery, Army College of Medical Sciences and Base Hospital, Delhi, India

²Department of Orthopaedics, 5 Airforce Hospital, Jorhat, Assam, India

³Department of Orthopaedic Surgery, AFMC, Pune, Maharashtra, India

Received: 10 November 2023

Revised: 13 November 2023

Accepted: 16 November 2023

*Correspondence:

Dr. Narender Singh,

E-mail: orthodocresearch@gmail.com

Copyright: © the author(s), publisher and licensee Medip Academy. This is an open-access article distributed under the terms of the Creative Commons Attribution Non-Commercial License, which permits unrestricted non-commercial use, distribution, and reproduction in any medium, provided the original work is properly cited.

ABSTRACT

Background: The clinical application of platelet rich plasma (PRP) in rotator cuff tears has increased recently. Many studies have found no difference between placebo controls and PRP and corticosteroids (CS) and some have found more rapid benefits with PRP injections. The present study was undertaken with the objectives to observe and assess efficacies of the two different treatment modalities in terms of symptomatic relief and recovery of ROM and to ascertain the duration of symptom free period and functional improvement on follow up.

Methods: Observational clinical outcome study, conducted at a tertiary care hospital between September 2020 and March 2022 after institute ethical committee clearance. A total of 100 patients, with a positive clinical test for supraspinatus and magnetic resonance imaging (MRI) suggestive of supraspinatus tendinitis were divided to 2 groups and based on whether they received either intra-articular CS or PRP injection under ultrasonography (USG) guidance. All patients were followed up at for assessing the outcomes at 6 weeks, 3 months and 6 months from intervention.

Results: The clinical outcome of the group receiving the PRP was better than group receiving CS intervention.

Conclusions: PRP should therefore be considered as a viable option to treat supraspinatus tendinopathy/partial tear as it is cheap, readily available modality using patients own blood which is more acceptable to patient and also safe to individual where complications related to corticosteroids anticipated. Ultrasound guided procedure were found to enhance the accuracy of injection.

Keywords: PRP, Supraspinatus tendonosis, Partial tear supraspinatus, Corticosteroid injection

INTRODUCTION

The shoulder joint is a complex joint due to its vast range of movement. Upto 2.5% of the population presents with pain in shoulder, showing trend of rapid increase in prevalence with increasing age.¹ Rotator cuff pathologies are very common and are usually the main cause of pain.² More than half of all shoulder pains arise from rotator cuff tendinopathy (RC), most common being supraspinatus partial thickness tears and tendinosis.³

General guidelines suggest that the initial treatment of rotator cuff tendinopathy should be non-operative.^{4,5} Conventionally, initial treatment includes physical rehabilitation, rest, and non-steroidal anti-inflammatory drugs.^{6,7} Other methods used are extracorporeal shockwave therapy and barbotage.^{4,8} CS, platelet-rich therapies (PRTs), hyaluronic acid, and botox injections have also been tried in such cases.⁹

Corticosteroids injections are more beneficial during the acute phase; however, they may cause tear of the tendon. Corticosteroids may also inhibit collagen synthesis.^{10,11} A meta-analysis suggested that there may be improvement in symptoms with steroid injections in short term.⁹ CS injections decrease the proliferation of cells. They also affect the composition of collagen and extracellular matrix, inhibit inflammatory pathways, and cause an increase adipocyte differentiation and apoptotic cell death.¹²⁻¹⁵ To add, these changes usually begin only after 24 hours and last up to 2 to 3 weeks, thereby causing a reduction in maximal load to failure. Concomitant local anesthetic use with corticosteroids may cause adverse effects in the soft tissues.¹⁶

The use of orthobiologics, like PRP and PRF, has become more popular recently.¹⁷ Platelet-rich therapies (PRTs) can be either platelet-rich plasma (RPP) or platelet-rich fibrin (PRF). Both of these can be either leucocyte poor or rich.¹⁸ Platelet rich plasma delivers high concentrations above physiological levels of growth factors in targeted area.¹⁹ Autologous platelets have been shown to be helpful in revascularization of the injured area. They also promote tendon healing by increasing growth of tendon cells, PDGF, and TGF and improve pain and function.²⁰ PRP injection therapies in different studies have been found to have a huge potential in rotator cuff tendinopathies as well as in other musculoskeletal disorders. In contrast to corticosteroids, no significant adverse effects have been found to be associated with PRP injections. Hence PRP may provide many benefits in soft tissue healing.²¹

The objective of the present study is to compare the clinical outcomes of ultrasound guided PRP and CS injections in supraspinatus tendinosis or partial supraspinatus tear (as confirmed by MRI).

METHODS

A prospective observational clinical outcome study was conducted in the department of orthopaedics of Base Hospital, Delhi Cantt. from September 2020 to March 2022. Ethical committee approval was taken from Institutional Ethical Committee, Base Hospital Delhi Cantt. Both treatment methods i.e USG guided PRP and CS were both being routinely used, a total of 100 patients (50 in PRP and 50 in CS group). The choice of type of intervention was jointly decided by the patient and the treating team who administered the intervention. Informed written consent was taken before including the patients in the study on a first come basis. Patients of both sexes between the ages of 20 and 50 years with positive clinical test for supraspinatus tendinopathy and MRI suggestive of supraspinatus tendinitis were included in the study. The exclusion criteria were prior fracture or surgery around the shoulder, full-thickness RC tear, anticoagulant therapy, prior history of local steroid and PRP injection in the past six months, bleeding disorders or pre-procedure platelet count less than 50,000, diabetes mellitus, cervical spondylosis, stiffness >6 months, concomitant

involvement of other rotator cuff muscles, shoulder instability, frozen shoulder, osteoarthritis of acromioclavicular joint or glenohumeral joint and os acromiale.

A two-member team consisting of one orthopedic surgeon and one interventional radiologist diagnosed and administered intervention in all cases to avoid confounding bias. After establishing the diagnosis clinico-radiologically, they explained the patients in detail about both the treatment modalities (PRP and corticosteroid) and possible side effects. Patients either received CS or received 2.5 ml PRP with local anaesthetic (2.5 ml of 2% lidocaine) was administered under USG guidance (Figure 1).

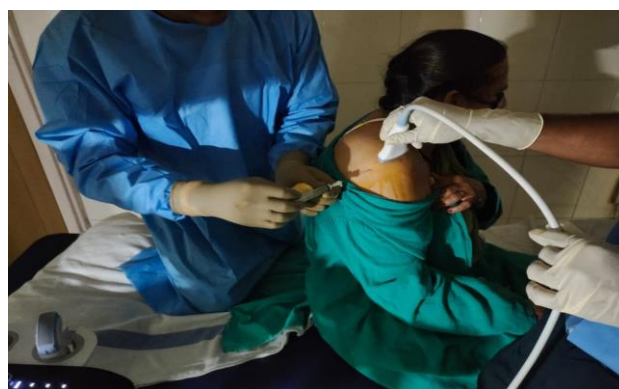

Figure 1: Dorsolateral approach (USG guided).

The total volume of both injections was also kept the same. The procedure followed for injections are as follows.

CS preparation and application

Under sterile aseptic precautions single dose injection of 1 ml (40 mg) methyl prednisolone acetate with local anaesthetic (4 ml of 2% lidocaine) were prepared in a single use syringe. The area was cleaned and draped with sterile glove covered USG probe to guide injection site. USG guidance was provided by using a 1.7- to 10-MHz linear array transducer. A dorsolateral approach was used for injection in both groups under USG guidance and infiltration done.

PRP preparation

Approximately 30 ml blood was drawn from the patient into a syringe containing 5 ml sodium citrate. First centrifugation was done for 15 min (3,000 rounds per minute) which separated it into platelets poor and leucocyte rich plasma and platelets rich and leucocyte poor plasma. The platelets poor plasma was discarded. After another centrifugation procedure, the PRP was withdrawn. The PRP was then transferred from blood bank to procedure room (USG room) in test tube stand under aseptic and thermal controlled conditions immediately.

Post injection protocol for both groups

After the injection, all the patients were kept under observation for 30 minutes. During this period, they were approached about participation in the trial by one of the first three authors. The details of were explained to the patients and consenting patients matching the inclusion and exclusion criteria were divided into either of the two groups (group I for PRP or group II for CS) accordingly in the type of intervention administered.

Shoulders were immobilized using arm slings for next three days following which, patients were asked to follow a gentle rehabilitation exercise program which included passive as well as active range of motion exercises. Sport activities were avoided for 6 weeks. Pain was managed by acetaminophen or acetaminophen/tramadol (325/37.5 mg).

Sample size calculation

A power of 80% ($Z_{1-\beta}$), a 5% (Z_{α}) level of significance and a pooled standard deviation (SD) was used for calculating the sample size for the study. Using the data available from the study by Ibrahim et al in Egyptian population, the mean visual analogue score at months in PRP group and steroid group was 2.3 and 2.3 respectively.¹⁷ Assuming a true difference in means between the test and the reference group of 0 (i.e. 2.3-2.3) units, a pooled standard deviation of 1.7 units, the study would require a sample size of 50 for each group (i.e. a total sample size of 100, assuming equal group sizes), to achieve a power of 80% and a level of significance of 5%, for declaring that the first group is equivalent to the second group at ± 1 units margin of equivalence.

Follow up and data collection

A total of 100 were recruited. Patients were followed up and compared at 6 weeks, 3 months and 6 months based on the VAS for shoulder pain, activity, satisfaction, the Oxford shoulder (OS) score, and the constant Murley (CM) score.

Statistical analysis

All data was analyzed by IBM-statistical package for social sciences (SPSS) version 21.0. Kolmogorov-Smirnov test was used to test normality.

Quantitative variables include unpaired t-test/Mann-Whitney test. Qualitative variables include Chi-square test/Fisher’s exact test.

P value was <0.05, which was statistically significant.

RESULTS

There was no significant difference in terms of the age group, gender distribution, residence, marital status,

physical activity status, educational qualification, mean duration of symptoms, side affected and history of hypertension. Demographic data is given in Table 1 and 2. Shoulder contour of patients in both the arms were also similar. Pre intervention both the groups had similar distribution in terms of mild Joint line tenderness, and clinical examination.

VAS scores (pain, activity and satisfaction), OSS scores and CM scores before injection were similar. The only difference between the groups was a significantly higher proportion of patients in the PRP intervention arm (63.3%) had a history of overhead activity compared to the CS intervention group (36.7%).

Following intervention, the VAS pain scores between the CS and PRP groups at 6 weeks and 3 months shows no significant difference. The pain scores in the PRP group at the end of 6 months is significantly lower ($p=0.04$) than that of the CS group (Figure 2).

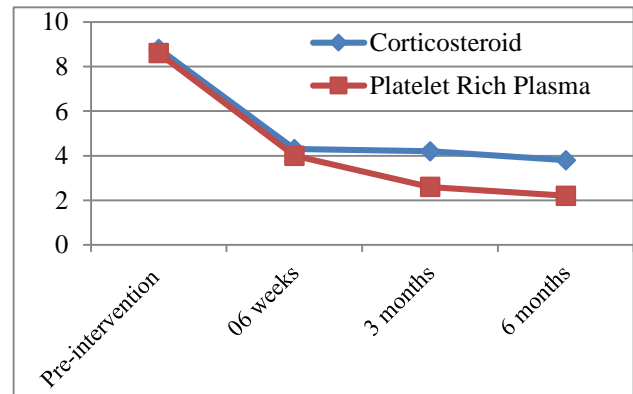


Figure 2: VAS for pain on follow up.

Both OSS (Figure 3) and CM score (Table 3) were significantly better ($p=0.0$) in the PRP group despite having minimal differences in the 6 weeks and 3-months score.

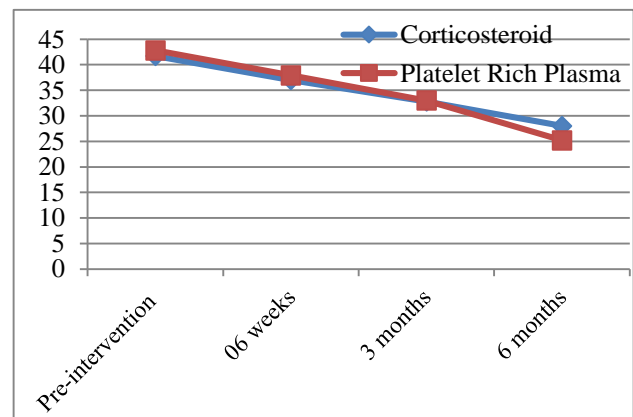


Figure 3: OSS score on follow up.

No significant difference was found in improvement of range of motion among the two intervention groups at

baseline (pre- injection), 6 weeks and 3 months. Higher range of movements in flexion, abduction and external rotation, are seen at 6 months, in the PRP group following

intervention. But only the differences in improvement in abduction were found to be statistically significant (Table 4).

Table 1: Age distribution among groups.

Age group	Group, N (%)		Statistical tests of significance	
	Corticosteroid	Platelet rich plasma	χ^2	Sig. (2-tailed)
Less than 30 years	2 (4)	2 (4)	0.343	0.842
30-44 years	22 (44)	18(36)		
45 years and above	26 (52)	30 (60)		
Total	50 (100)	50 (100)		

Table 2: Comparison of gender between the intervention groups.

Gender	Group, N (%)		Statistical tests of significance	
	Corticosteroid, N (%)	Platelet rich plasma, N (%)	χ^2	Sig. (2-tailed)
Male	22 (44)	20 (40)	0.082	0.774
Female	28 (56)	30 (60)		
Total	50 (100)	50 (100)		

Table 3: Comparison of mean CM score between the intervention groups.

CM (mean±SD)	Group (n=50)		Statistical tests of significance	
	Corticosteroid	Platelet rich plasma	t	Sig. (2-tailed)
Pre injection	22.5±0.8	22.9±1.2	-1.24	0.22
6weeks	27.2±2.6	27.4±2.4	-0.170	0.87
3 months	35.1±1.9	36.1±2.3	-1.63	0.11
6 months	36.6±2.2	37.9±2.0	-2.28	0.03*

*Statistically significant

Table 4: Comparison of physical activity status between the intervention groups.

Range of movement in degrees (mean±SD)	Group, , N (%)		Statistical tests of significance	
	Corticosteroid	Platelet rich plasma	t	Sig. (2-tailed)
Flexion				
Pre injection	82.0±7.6	81.6±8.0	0.18	0.86
6 weeks	88.0±9.6	87.2±6.8	0.34	0.74
3 months	91.2±10.1	91.6±8.5	-0.15	0.88
6 months	94.4±10.8	98.4±9.4	-1.32	0.17
Abduction				
Pre injection	69.6±10.2	70.0±8.2	0.33	0.75
6 weeks	74.8±9.3	74.4±8.7	0.46	0.65
3 months	80.8±10.8	79.2±9.1	1.03	0.31
6 months	83.2±11.2	89.6±7.9	-2.33	0.03*
External rotation				
Pre injection	24.8±5.1	25.6±5.1	-0.56	0.58
6 weeks	29.6±7.3	30.0±7.1	-0.20	0.85
3 months	36.4±9.1	34.0±9.6	0.91	0.37
6 months	36.8±9.0	41.2±9.7	-1.67	0.10

*Statistically significant.

DISCUSSION

On reviewing available literature, it was found that PRP may have a positive role in the treatment for RC tendinopathy, although the interpretation of results was far

from decisive, as different studies used different approaches to assess efficacy or used different products of PRP.^{3,8,9} In their study on 58 patients with rotator cuff tendinopathy, after three months, Dadgostar et al, reported significant pain improvement in cases who received PRP injections compared with the corticosteroid group.²²

Shams et al on the contrary, showed better results with PRP only upto 3 months.³ However, they found no significant differences in the 6-months results. Similarly, von Wehren et al found early improvement with PRP, however no significant difference was found at 6 months of follow-up.²³

Despite difference in opinion as to the timing of the improvement, the present study tried to observe the clinical outcome of both PRP and CS group in a larger sample size in a tertiary care orthopedic centre and found similar results to studies by both Shams et al and von Wehren et al in concluding that PRP might be a better option as compared to CS injections.^{3,23} Scapone et al reported significant pain improvement along with functional improvement and superior MRI outcomes.²⁴ In contrast, Kesikburun et al found no difference in PRP or saline injections over a follow up of one year.²⁵

In the present study, the results of PRP injection are similar to those of CS injections in the short term and better in the long term (6 months), hence, PRP can be used as an alternative to corticosteroid injections in patients with supraspinatus tendinosis or partial supraspinatus tear. Patients given corticosteroids injections are more prone to develop local and systemic complications especially on repeated use.²⁶ Local corticosteroid application causes weakness of the injected region of the tendon thereby increasing the chances of failure or rupture.²⁷ This weakening is present in the individual collagen fascicles. PRP is therefore, a relatively safe alternative that can be used multiple times with no significant side effects.^{3,13,16,24,26}

Various growth factors present in PRP have shown potential to increased synthesis of type I collagen and tenocyte proliferation.²⁸ PRP Injection into areas of musculotendinous injury in animals has been found to enhance the recruitment of cells for tendon healing during the early phases.²⁹ These factors together may explain the better longterm results in the PRP group due to increased healing potential compared to CS group.

The strengths of present study had a larger number of patients compared to the earlier studies by Shams et al and von Wehren et al.^{3,23} The use of USG allows real-time examination, and the needle may be dynamically viewed as it approaches the target. The needle can be observed as an echogenic structure along its whole length.³⁰ However, some studies show no significant difference between USG-guided and landmark-guided injections.

In addition to the intervention, other factors also affect the recovery of patients. The most important of these are physical activity and oral analgesics. Since both the treatment groups received similar post procedure instructions regarding physical therapy and medications, effects of these variables on recovery were drastically reduced.

The limitations of the study are that it was conducted in a single centre thereby limiting the generalization of the findings. Secondly, despite the best efforts, a significant difference in the history of overhead activity was seen between the treatment groups. Whether that could have in any way affected the study results could not be evaluated within the study parameters. Finally, the study compares a single injection of PRP with CS. Previous data suggests better improvement with multiple PRP injections as compared to a single PRP injection, and thus the actual benefits of PRP, in the long term, may have been underestimated in the study.

CONCLUSION

Both corticosteroids and PRP group showed improvement in all the parameters in our study however the PRP group on 6 month follow up had significant reduction of pain as evident by improved VAS score and functional improvement and quality of life improvement as evident by Oxford shoulder score and constant Murley score. There is significant improvement in abduction with PRP group on long term follow-up.

PRP should therefore be considered as a viable option to treat supraspinatus tendinopathy/partial tear as it is cheap, readily available modality using patients own blood which is more acceptable to patient and also safe to individual especially where complications related to corticosteroids are anticipated. Ultrasound guided procedure can be used to enhance the accuracy of injection.

Funding: No funding sources

Conflict of interest: None declared

Ethical approval: The study was approved by the Institutional Ethics Committee

REFERENCES

1. Luime JJ, Koes BW, Hendriksen IJ, Burdorf A, Verhagen AP, Miedema HS, et al. Prevalence and incidence of shoulder pain in the general population; a systematic review. *Scand J Rheumatol.* 2004;33(2):73-81.
2. Lewis JS. Rotator cuff tendinopathy: a model for the continuum of pathology and related management. *Br J Sports Med.* 2010;44(13):918-23.
3. Shams A, El-Sayed M, Gamal O, Ewes W. Subacromial injection of autologous platelet-rich plasma versus corticosteroid for the treatment of symptomatic partial rotator cuff tears. *Eur J Orthop Surg Traumatol.* 2016;26(8):837-42.
4. Diercks R, Bron C, Dorrestijn O, Meskers C, Naber R, de Ruitter T, et al. Guideline for diagnosis and treatment of subacromial pain syndrome: a multidisciplinary review by the Dutch Orthopaedic Association. *Acta Orthop.* 2014;85(3):314-22.
5. Ketola S, Lehtinen JT, Arnala I. Arthroscopic decompression not recommended in the treatment of rotator cuff tendinopathy: a final review of a

- randomised controlled trial at a minimum follow-up of ten years. *Bone Joint J.* 2017;99:799-805.
6. Dickinson RN, Ayers GD, Archer KR, Fan R, Page C, Higgins LD, et al. Physical therapy versus natural history in outcomes of rotator cuff tears: the Rotator Cuff Outcomes Workgroup (ROW) cohort study. *J Shoulder Elbow Surg.* 2019;28(5):833-8.
 7. Lo IK, Denkers MR, More KD, Nelson AA, Thornton GM, Boorman RS. Partial thickness rotator cuff tears: clinical and imaging outcomes and prognostic factors of successful nonoperative treatment. *Open Access J Sports Med.* 2018;9:191-7.
 8. Lewis J. Rotator cuff related shoulder pain: assessment, management and uncertainties. *Man Ther.* 2016;23:57-68.
 9. Lin MT, Chiang CF, Wu CH, Huang YT, Tu YK, Wang TG. Comparative effectiveness of injection therapies in rotator cuff tendinopathy: a systematic review, pairwise and network meta-analysis of randomized controlled trials. *Arch Phys Med Rehabil.* 2019;336-49.
 10. Gaujoux-Viala C, Dougados M, Gossec L. Efficacy and safety of steroid injections for shoulder and elbow tendonitis: a meta-analysis of randomised controlled trials. *Ann Rheum Dis.* 2009;68(12):1843-9.
 11. Dean, BJ, Lostis, E, Oakley, T, Rombach, I, Morrey, ME, Carr, AJ. The risks and benefits of glucocorticoid treatment for tendinopathy: a systematic review of the effects of local glucocorticoid on tendon. *Semin Arthritis Rheum.* 2014;43(4):570-6.
 12. Desai VS, Camp CL, Boddapati V, Dines JS, Brockmeier SF, Werner BC. Increasing numbers of shoulder corticosteroid injections within a year preoperatively may be associated with a higher rate of subsequent revision rotator cuff surgery. *Arthroscopy.* 2019;35:45-50.
 13. Mohamadi A, Chan JJ, Claessen FM, Ring D, Chen NC. Corticosteroid injections give small and transient pain relief in rotator cuff tendinosis: a meta-analysis. *Clin Orthop Relat Res.* 2017;475:232-43.
 14. Maman E, Yehuda C, Pritsch T, Morag G, Brosh T, Sharfman Z, et al. Detrimental effect of repeated and single subacromial corticosteroid injections on the intact and injured rotator cuff: a biomechanical and imaging study in rats. *Am J Sports Med.* 2016;44:177-82.
 15. Freire V, Bureau NJ. Injectable corticosteroids: take precautions and use caution. *Semin Musculoskelet Radiol.* 2016;20:401-8.
 16. Zhang AZ, Fickscherer A, Gülecyüz MF, Paulus AC, Niethammer TR, Jansson V, et al. Cell toxicity in fibroblasts, tenocytes, and human mesenchymal stem cells: a comparison of necrosis and apoptosis-inducing ability in ropivacaine, bupivacaine, and triamcinolone. *Arthroscopy.* 2017;33:840-8.
 17. Ibrahim DH, El-Gazzar NM, El-Saadany HM, El-Khouly RM. Ultrasound-guided injection of platelet rich plasma versus corticosteroid for treatment of rotator cuff tendinopathy: effect on shoulder pain, disability, range of motion and ultrasonographic findings. *Egyptian Rheumatol.* 2019;41(2):157-61.
 18. Dohan Ehrenfest DM, Rasmusson L, Albrektsson T. Classification of platelet concentrates: from pure platelet-rich plasma (P-PRP) to leucocyte- and platelet-rich fibrin (L-PRF). *Trends Biotechnol.* 2009;27(3):158-67.
 19. Rutgers M, Saris DB, Dhert WJ, Creemers LB. Cytokine profile of autologous conditioned serum for treatment of osteoarthritis, in vitro effects on cartilage metabolism and intra-articular levels after injection. *Arthritis Res Therapy.* 2010;12(3):1.
 20. De Vos RJ, Weir A, van Schie HT, Bierma-Zeinstra SM, Verhaar JA, Weinans H, Tol JL. Platelet-rich plasma injection for chronic Achilles tendinopathy: a randomized controlled trial. *JAMA.* 2010;303(2):144-9.
 21. Jo CH, Lee SY, Yoon KS, Oh S, Shin S. Allogenic pure platelet-rich plasma therapy for rotator cuff disease: a bench and bed study. *Am J Sports Med.* 2018;46:3142-54.
 22. Dadgostar H, Fahimipour F, Pahlevan Sabagh A, Arasteh P, Razi M. Corticosteroids or platelet-rich plasma injections for rotator cuff tendinopathy: a randomized clinical trial study. *J Orthop Surg Res.* 2021;16(1):1-8.
 23. von Wehren L, Blanke F, Todorov A, Heisterbach P, Sailer J, Majewski M. The effect of subacromial injections of autologous conditioned plasma versus cortisone for the treatment of symptomatic partial rotator cuff tears. *Knee Surg Sports Traumatol Arthrosc.* 2016;24:3787-92.
 24. Scarpone M, Rabago D, Snell E, Demeo P, Ruppert K, Pritchard P, et al. Effectiveness of platelet-rich plasma injection for rotator cuff tendinopathy: a prospective open-label study. *Glob Adv Health Med.* 2013;2(2):26-31.
 25. Kesikburun S, Tan AK, Yılmaz B, Yaşar E, Yazıcıoğlu K. Platelet-rich plasma injections in the treatment of chronic rotator cuff tendinopathy: a randomized controlled trial with 1-year follow-up. *Am J Sports Med.* 2013;41(11):2609-16.
 26. Puzziello RN, Patel BH, Nwachukwu BU, Allen AA, Forsythe B, Salzler MJ. Adverse impact of corticosteroid injection on rotator cuff tendon health and repair: a systematic review. *Arthroscopy.* 2020;36:1468-75.
 27. Haraldsson BT, Langberg H, Aagaard P, Zuurmond AM, van El B, DeGroot J, et al. Corticosteroids reduce the tensile strength of isolated collagen fascicles. *Am J Sports Med.* 2006;34(12):1992-7.
 28. de Mos M, van der Windt AE, Jahr H, van Schie HT, Weinans H, Verhaar JA, et al. Can platelet-rich plasma enhance tendon repair? A cell culture study. *Am J Sports Med.* 2008;36(6):1171-8.
 29. Kajikawa Y, Morihara T, Sakamoto H, Matsuda K, Oshima Y, Yoshida A, et al. Platelet-rich plasma enhances the initial mobilization of circulation-

derived cells for tendon healing. *J Cell Physiol.* 2008;215(3):837-45.

30. Louis LJ. Musculoskeletal ultrasound intervention: principles and advances. *Radiol Clin.* 2008;46:515-33.

Cite this article as: Dasgupta T, Das M, Gogia T, Singh N, Tiwary A, Verma V. Ultrasound guided platelet rich plasma or corticosteroid for supraspinatus tendonosis or partial tear: an observational study of clinical outcome. *Int J Res Orthop* 2024;10:43-9.