

Original Research Article

Suprascapular nerve block in shoulder dislocation

Sofia A. S. Madeira^{1*}, Marcelo P. T. Alves², Catia F. C. Nunes¹,
Maria Ines S. Rocha¹, João D. P. Cabaço¹

¹Hospital Garcia de Orta, Almada, Portugal

²Hospital Dr. José Maria Grande, Portalegre, Portugal

Received: 23 October 2023

Revised: 01 December 2023

Accepted: 11 December 2023

*Correspondence:

Dr. Sofia A. S. Madeira,

E-mail: sofiasantosmadeira@gmail.com

Copyright: © the author(s), publisher and licensee Medip Academy. This is an open-access article distributed under the terms of the Creative Commons Attribution Non-Commercial License, which permits unrestricted non-commercial use, distribution, and reproduction in any medium, provided the original work is properly cited.

ABSTRACT

Background: The suprascapular nerve is the main sensitive nerve of the shoulder. In 1973, the suprascapular nerve block was applied in the reduction of a series of cases of acute shoulder dislocations using mepivacaine. Barber described a method using anatomic landmarks to locate and block the suprascapular nerve.

Methods: This study was approved by our Institutional Review Board and all patients signed an informed consent. We performed a prospective longitudinal study, characterized by a consecutive series of first episode of traumatic shoulder dislocation in patients over 18 years old. From July 2020 to April 2022, 50 cases were included in our study. All patients had their pain evaluated before the blockage, during the reduction and after the reduction. We used the Barber method for the blockage and the Spaso maneuver for reduction.

Results: From the 50 cases, 29 were males (58%). The mean age was 58,7 years. 47 cases were anterior dislocations, 2 cases posterior dislocations and one case of *luxatio erecta*. The mean initial VAS was 7.5 points (minimal 4, maximum 10). The main score during the reduction maneuver was 2 points (0-5) and the main score after reduction was 0,4 (0-3). In only one case, reduction was not successful after 3 attempts, and reduction was performed under sedation.

Conclusions: The suprascapular nerve block by Barber's method proves to be a secure, effective and simple procedure to aid the shoulder dislocation reduction in the emergency room, without the need of any imaging resources.

Keywords: Shoulder dislocation, Peripheral nerve block, Suprascapular nerve, Shoulder trauma

INTRODUCTION

The suprascapular nerve is the main sensitive nerve of the shoulder, mainly to the superior and posterior regions.¹ The suprascapular block was initially described in 1941, by the authors Wertheim and Rovenstein and since then has been applied in several medical practices ranging from acute pain treatment to chronic shoulder pain management.^{2,3} It has been also used in clinical trials in suprascapular nerve neuropathy.⁴⁻⁶ The most frequently treated lesions include adhesive capsulitis, rotator cuff tears, shoulder arthritis, and rheumatoid arthritis.¹ One of the first articles describing its application in traumatic

shoulder dislocation was published in 1973, by Edeland and Stefansson, who used 1% mepivacaine as a local anesthetic.⁷ They managed to reduce the dislocation without general anesthesia in 10 out of 12 patients. Since then, very few papers have been published about the use of this technique to reduce traumatic shoulder dislocations, even though there has been an evolution in local anesthetics and local blockages, with an increased use of ultrasound in the emergency room to aid. In 2005, Barber described a technique for suprascapular nerve block, in order to promote post-operative pain relief after shoulder arthroscopy.⁸ In this technique, Barber used anatomic landmark points, such as the acromioclavicular joint, the

scapula spine, and the posterior edge of the clavicle, and used 0.5% bupivacaine. Since all his patients had already been given general anesthesia, his goal was to promote a reduction of post-operative pain. Concina et al performed an anatomical research in which they evaluated the needle positioning for the suprascapular block using the Barber technique.⁹ They studied 8 fresh cadavers that have been dead for less than a day and evaluated the positioning of a Kirschner wire with the anatomical references used by Barber, concluding that the Kirschner wire was in a consistent position and close to the suprascapular nerve, proving that the Barber technique is a simple and reliable technique to perform this blockade. In this work, the authors applied the Barber technique to block the suprascapular nerve, and 2% lidocaine as a local anesthetic, due to its large availability in emergency rooms. The goal of this study is to prove the efficacy of the suprascapular nerve block in the reduction of traumatic shoulder dislocations.

METHODS

The study was performed in Hospital Dr. José Maria Grande, Portalegre District, Portugal. It was approved by our Institutional Review Board and all patients signed an informed consent. Between July 2020 and April 2022, we conducted a longitudinal prospective study, characterized by a consecutive series of cases with a first episode of an acute traumatic shoulder dislocation, until we reached 50 patients in our study group.

Inclusion and exclusion criteria

Inclusion criteria were patients above 18 years, with a first episode of a shoulder dislocation that agreed to the blockage. We excluded all pediatric patients and those with more than one episode of shoulder dislocation.

Previously to medical evaluation, all patients were assigned a clinical priority according to the Manchester Triage System and pain was evaluated with the Visual Analogue Scale (VAS) as part of the triage (scale from 0 to 10, with 10 being the maximum pain level). After initial medical evaluation, all patients performed radiographs of the affected shoulder, in two views, anteroposterior and lateral.

The anesthetic procedure was thoroughly explained to each patient who have signed an Informed Consent to the procedure. According to the technique described by Barber (8), we used 10 mL of 2% lidocaine to perform the suprascapular nerve block, using anatomical landmarks (Figure 1-2). Barber applied the injection using the Neviaser portal, commonly used in shoulder arthroscopy.

The approximate time for the blockage to take place is 10 min. After this time, we attempted the reduction maneuver. In the first reduction attempt, we used the Spaso maneuver (Figure 3) which consists in positioning the patient in a dorsal decubitus, with the shoulder in 90° of flexion and

applying traction at the same time as a shoulder external rotation. In case of an unsuccessful attempt with this maneuver, others were to be attempted.

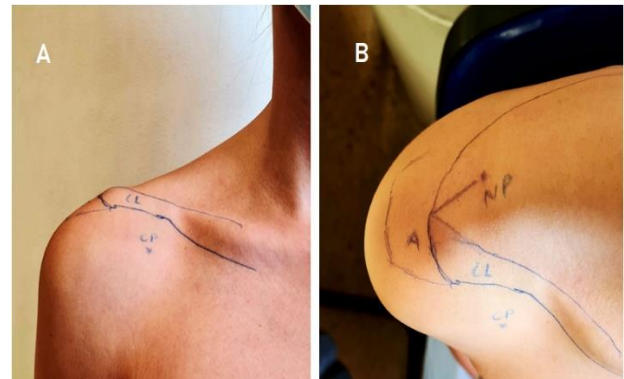


Figure 1: Anatomical landmarks; A) Front view, B) Upwards view; CL-clavicular; A-acromio-cavicular joint, CP-coracoid process, NP-Neviaser portal

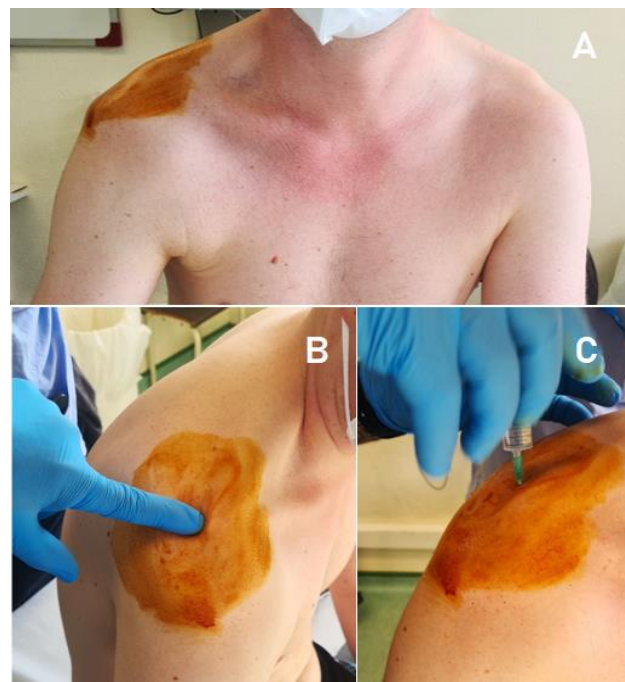


Figure 2: Anesthetic blockade; A) Patient with an anterior right shoulder dislocation. Skin disinfection, B) Palpation of anatomical references and finding the portal, C) Injection of 10mL of lidocaine at 2%.

The VAS was evaluated during the maneuver and right after the reduction, through a direct question to the patient. After reduction, all patients had another shoulder radiograph in order to confirm reduction, and were followed the Orthopedic Department follow-up protocols and were re-evaluated in Orthopedic appointments. All complications from the nerve blockage were registered and treated. The results were treated using the Excel@ software.

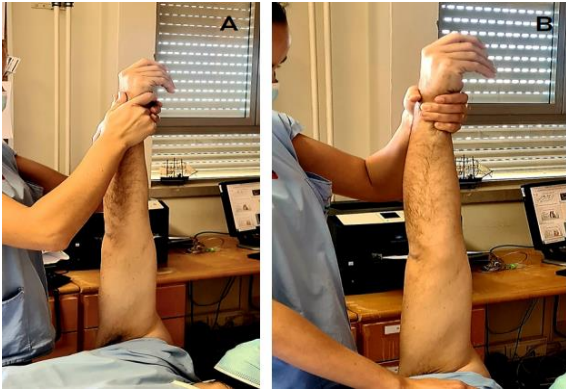


Figure 3: Spaso maneuver; A) The patient is in dorsal decubitus with the shoulder in 90° of flexion. The maneuver consists in applying traction at the same time as a shoulder external rotation. B) If needed, counter pressure may be applied.

RESULTS

The study group was a series of consecutive cases until 50 patients were reached, with 29 males (58%) (Figure 4).

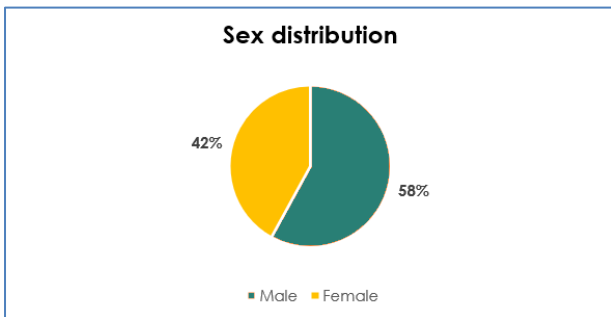


Figure 4: Sex distribution in the study group.

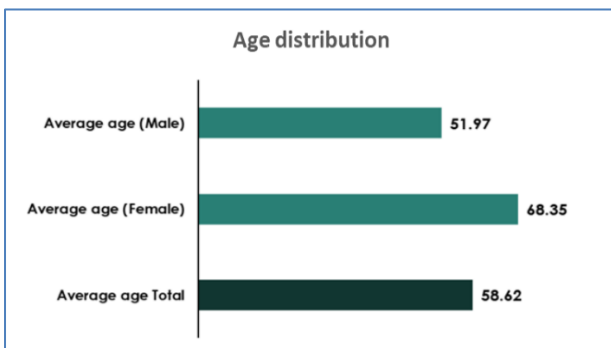


Figure 5: Age distribution in the study group.

The mean age was 58.7 years (ranging from 21 to 88 years) (Figure 5). In initial radiographs, 47 dislocations were anterior (94% of the cases), 2 were posterior (4%) and one was a *luxatio erecta* (2%) (Figure 6).

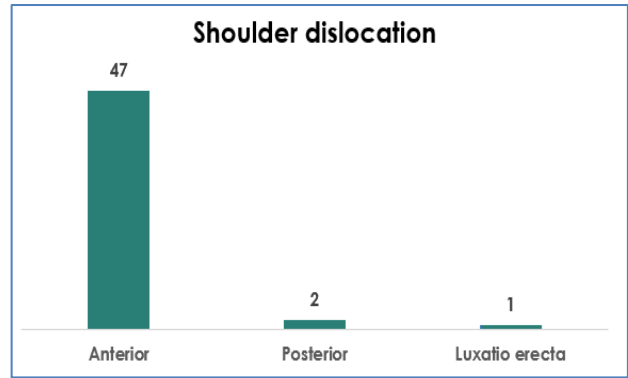


Figure 6: Distribution of types of dislocation.

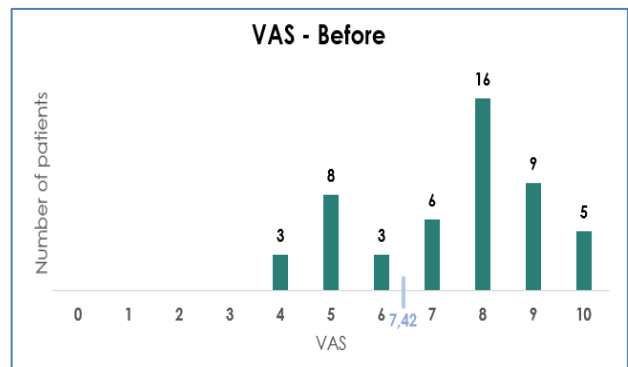


Figure 7: Reported VAS before anesthetic procedure, with a mean VAS of 7,42.

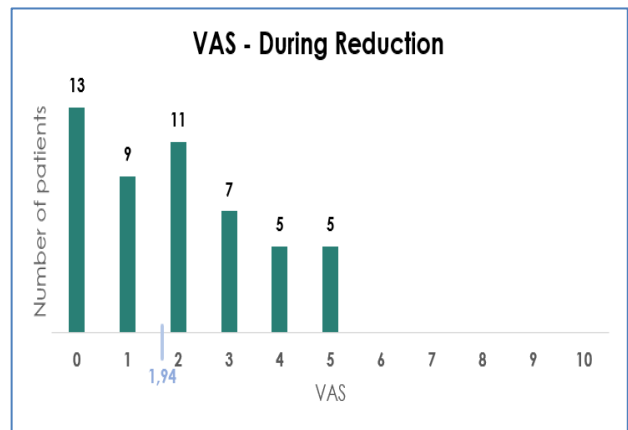


Figure 8: Reported VAS during reduction.

The mean initial VAS was 7, 5 points (ranging from 4 to 10) (Figure 7). The mean score during the reduction maneuver was 2 (0-5 points) (Figure 8). The mean score after reduction was 0.4 points (0-3 points) (Figure 9). In Figure 10, one can see the evolution of the average VAS along the described procedure. A mean of 1,6 attempts was used (minimum 1 and maximum 3) (Figure 11). In one case, we did not achieve reduction after 3 attempts and therefore the Anesthesiology Team was contacted, and reduction was successfully achieved after sedation. Concerning complications, we registered only two cases of

a vasovagal reaction after the anesthetic procedure, with spontaneous and complete recovery in few minutes.

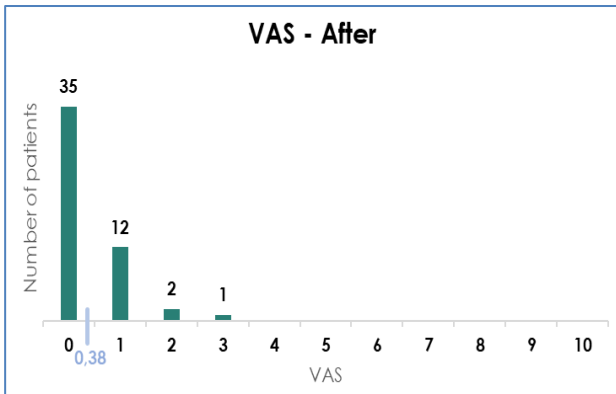


Figure 9: Reported VAS after reduction.

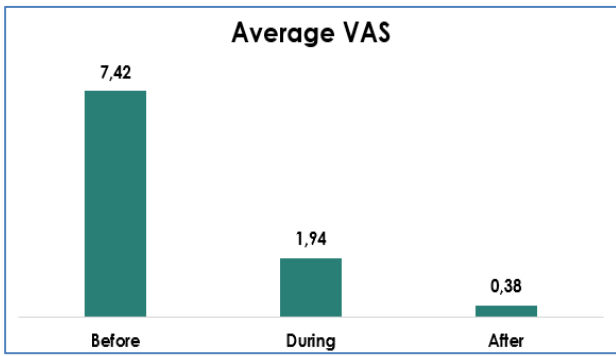


Figure 10: Changes in mean VAS during patient treatment: before anesthetic procedure, during reduction and after reduction.

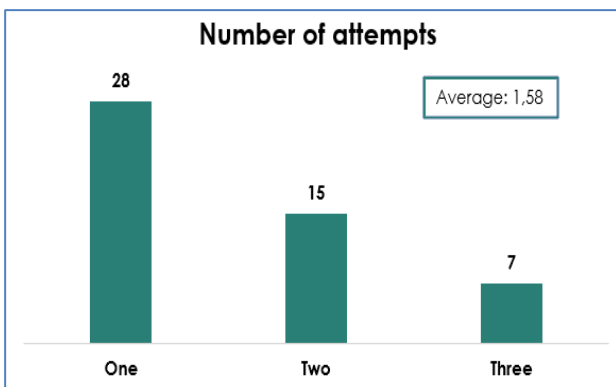


Figure 11: Number of reduction attempts.

DISCUSSION

That has come to our knowledge, this is the first prospective study with the described anesthetic technique for traumatic shoulder dislocations. In the results, we observed that there was an effective pain relief during the reduction, which brings more comfort to the patients, thus reducing defensive muscular contraction from the patient, easing the reduction maneuver. This fact was already

demonstrated in other shoulder pathologies, such as suprascapular nerve neuropathy, adhesive capsulitis, rotator cuff tears, shoulder arthritis, and rheumatoid arthritis.^{1,4-6} Hassen et al noted that the blockade of the suprascapular nerve could be applied also to more complicated patients such as obese, older and patients with other comorbidities, thus reducing the length of stay in an emergency department for these patients. In our work, we didn't exclude any patient older than 18 years of age with an initial presentation of acute shoulder dislocation, even if they had any comorbidity. And the procedure was successful in all but one patient without clinical relevant complications.¹⁰ Tezel et al compared two types of anesthesia in acute shoulder dislocations.¹¹ They applied procedural sedation analgesia, with ketamine and the suprascapular nerve block. They observed that the suprascapular nerve block was easily applied in the Emergency Department (ED) and was a good alternative to sedation analgesia in the reduction of shoulder dislocations. They've also observed the time spent in the ED by patients in the sedation analgesia group was significantly longer compared with the suprascapular nerve block group and noted no side effects in this group. Although we didn't note the time spent in the ED in this study, we observed that 49 patients left the ED after the control X-Ray was observed by the team and the only patient that stayed more time in the ED was the one in which we needed the support of the anesthesiologist.

One of the advantages of this method is the availability of the chosen anesthetic, which is commonly present in most emergency facilities. It has also a security profile that has been widely studied and documented. In 2008, Jerosch et al evaluated the amount of anesthetic needed to infiltrate the suprascapular fossa and documented it with fluoroscopy.¹² They concluded that 10mL of 2% lidocaine were sufficient to perform a suprascapular nerve block. We agree with Piper et al that intra-articular local anesthetics should be used with caution, especially continuous infusions of bupivacaine and lidocaine at high concentrations in joints with compromised cartilage; those may have lasting detrimental effects on human articular cartilage and chondrocytes.¹³ By performing an extra-articular procedure to block the suprascapular nerve, we avoided those risks to the articular cartilage of the shoulder. Another advantage is the use of anatomical landmarks readily identifiable, without the need to use ultrasound, which may not be available, and it is operator-dependent, with a learning curve.

In our study we were able to perform the blockade without difficulties. Gleeson et al noted that suprascapular nerve block should ideally be performed using a nerve stimulator to locate the nerve and ensure success.¹⁴ Our study proved that this is not necessary, since we used only anatomical landmarks. The Spaso maneuver is also a simple maneuver that does not require too much physical strength in its performance. Ugras et al noted no complications of the Spaso maneuver and noted 87,5% of success rate of the reduction.¹⁵ Our rate of success in the reduction was 98%.

They also noted that this method decreased reduction time and length of stay in the Emergency Department as Tezel et al had already described.¹¹

Guler et al states the Spaso method is very simple and with high success rates (67.6-87.5%), which was also observed in our study. In their study, they've observed a medium VAS of 6.5 during the reduction maneuver. In our study, the medium VAS during the reduction maneuver was 1,94.¹⁶ The reason for this was the application of the suprascapular nerve block and this helps to proof that the use of this blockade can help the attending doctor to perform the reduction, lower the patient's pain during the maneuver and avoid the use of more complicated procedures, such as procedural sedation analgesia. As a main weakness of our study, we point out the lack of a control group and proper randomization in order to compare groups.

CONCLUSION

It was concluded that 98% of the cases were reduced without the need for any other anesthetic procedures other than the suprascapular nerve block. We did not have any harmful complications, attesting to the security of this method. The suprascapular block by Barber's method proves to be a secure, effective, and simple procedure to aid the reduction maneuver of a dislocated shoulder in the emergency room, without the need of any imaging resources.

ACKNOWLEDGEMENTS

Authors would like to express deepest appreciation towards Dr. Mário Tapadinhas, head of the Orthopaedics Department of Hospital Garcia de Orta, for all the support.

Funding: No funding sources

Conflict of interest: None declared

Ethical approval: The study was approved by the Institutional Ethics Committee

REFERENCES

1. Chan CW, Peng PW. Suprascapular nerve block: a narrative review. *Reg Anesth Pain Med.* 2011;36(4): 358-73.
2. Rovenstine EA, Wertheim HM. Therapeutic nerve block. *J Am Med Assoc.* 1954;117(19):1599-603.
3. Silva MR, Dias J, Neves AF, Martins D, Pegado A. Bloqueio do nervo supraescapular na dor crónica do Ombro: uma revisão. *Revista SPMFR.* 2018;30(3):99-103.
4. Boykin RE, Friedman DJ, Higgins LD, Warner JJ. Suprascapular neuropathy. *J Bone Joint Surg Am.* 2010;92(13):2348-64.
5. Shi LL, Freehill MT, Yannopoulos P, Warner JJ. Suprascapular nerve: is it important in cuff pathology?. *Adv Orthoped.* 2012;12:23-9.
6. Ferreira NV, Seivivas N, Silva MV. Neuropatia compressiva do nervo supraescapular. *Rev Port Ortop Traum.* 2014;22(3):249-64.
7. Edeland HG, Stefánsson T. Block of the suprascapular nerve in reduction of acute anterior shoulder dislocation. *Acta Anaesthesiol Scand.* 2017;17(1):46-9.
8. Barber FA. Suprascapular nerve block for shoulder arthroscopy. *Arthrosc J Arthrosc Related Surg.* 2017; 21(8):1015.
9. Concina C, Szarko M, Pearse E, Tennent D. Anatomical evaluation of a technique for suprascapular nerve blockade. *J Orthop.* 2014;4:237-42.
10. Hassen GW, Bergmann-Dumont D, Duvvi A, Sudol S, Choy D, Yeo T, et al. The use of a suprascapular nerve block to facilitate the reduction of an anterior shoulder dislocation: an alternative for elderly and patients with cardiopulmonary comorbidities?. *J Emerg Med.* 2022; 63(2):265-71.
11. Tezel O, Kaldirim U, Bilgic S, Deniz S, Eyi YE, Ozyurek S, et al. A comparison of suprascapular nerve block and procedural sedation analgesia in shoulder dislocation reduction. *Am J Emerg Med.* 2014;32(6): 549-52.
12. Jerosch J, Saad M, Greig M, Filler T. Suprascapular nerve block as a method of preemptive pain control in shoulder surgery. *Knee Surg Sports Traumatol Arthrosc.* 2008;16:602-7.
13. Piper SL, Kramer JD, Kim HT, Feeley BT. Effects of local anesthetics on articular cartilage. *Am J Sports Med.* 2011;39(10):2245-53.
14. Gleeson AP, Graham CA, Jones I, Beggs I, Nutton RW. Comparison of intra-articular lignocaine and a suprascapular nerve block for acute anterior shoulder dislocation. *Injury.* 1997;28(2):141-2.
15. Ugras AA, Mahirogullari M, Kural C, Erturk AH, Cakmak S. Reduction of anterior shoulder dislocations by Spaso technique: clinical results. *J Emerg Med.* 2008;34(4):383-7.
16. Guler O, Ekinici S, Akyildiz F, Tirmik U, Cakmak S, Ugras A, et al. Comparison of four different reduction methods for anterior dislocation of the shoulder. *J Orthop Surg Res.* 2015;10:80.

Cite this article as: Madeira SAS, Alves MPT, Nunes CFC, Rocha MIS, Cabaço JDP. Suprascapular nerve block in shoulder dislocation. *Int J Res Orthop* 2024;10:14-8.