

## Original Research Article

# Comparative study of functional and radiological outcomes of the usage of two devices, derotation type cephalomedullary nail and the helical blade type in unstable intertrochanteric fractures in the geriatric population at a tertiary-level center

Vishal Prakash<sup>1\*</sup>, Neelu Singh<sup>2</sup>, Govind Kumar Gupta<sup>1</sup>, Vinay Prabhat<sup>1</sup>

<sup>1</sup>Department of Orthopaedics, Rajendra Institute of Medical Sciences, Ranchi, Jharkhand, India

<sup>2</sup>Department of Obstetrics and Gynaecology, CHC Sahebganj, Mujaffarpur, Bihar, India

**Received:** 11 October 2023

**Revised:** 25 October 2023

**Accepted:** 26 October 2023

### \*Correspondence:

Dr. Vishal Prakash,

E-mail: Vish.vjs@gmail.com

**Copyright:** © the author(s), publisher and licensee Medip Academy. This is an open-access article distributed under the terms of the Creative Commons Attribution Non-Commercial License, which permits unrestricted non-commercial use, distribution, and reproduction in any medium, provided the original work is properly cited.

## ABSTRACT

**Background:** Intertrochanteric fracture is a common osteoporotic fracture among elderly populations in an aging society. Early surgical fixation on these aging patients has been proposed recently for early rehabilitation and has had a positive impact on reducing comorbidities. For unstable fractures, intramedullary implants generally present biomechanical advantages over their extramedullary counterparts.

**Methods:** The study was a 2 years prospective comparative study from 1<sup>st</sup> December 2020 to 1<sup>st</sup> December 2022 conducted in the department of orthopaedics, Rajendra institute of medical sciences, Ranchi, Jharkhand, India. Total number of patients were 50, PFN done in 25 cases and PFN-A2 in another 25 cases.

**Results:** Mean age is 64.4 years in PFN group as compared to 67.3 years in PFN-A2 group. PFN-A2 was done in 84% male while PFN in only 76 % male and in both groups right side was mostly affected. Average surgery time, amount of blood loss, average number of C-arm shoot was more in PFN group.

**Conclusions:** In this study of 50 patients, 25 treated by PFN and 25 by PFN-A2, it was concluded that PFN-A2 was a better construct to treat patients of older age group having osteoporosis because here reaming was not done and helical blade was inserted by hammering which caused compaction of bones in head and neck region.

**Keywords:** Intertrochanteric fractures, Harris hip score, Cleveland index, Helical blade

## INTRODUCTION

Intertrochanteric fracture is a common osteoporotic fracture among elderly populations in an aging society.<sup>1-3</sup> Early surgical fixation on these aging patients has been proposed recently for early rehabilitation and has had a positive impact on reducing comorbidities.<sup>4-6</sup>

Femoral pertrochanteric fractures are associated with a high rate of mortality in the first year after the event.<sup>7</sup> For unstable fractures, intramedullary implants generally present biomechanical advantages over their

extramedullary counterparts.<sup>7,8</sup> The dynamic hip screw, which has become the gold standard treatment of stable fractures, was found to be inappropriate to treat the unstable class of intertrochanteric fractures.<sup>9</sup> For fixation of unstable fractures, the use of an intramedullary nail coupled with a dynamic femoral head/neck stabilization implant is the ideal method.<sup>10</sup> Over time, various designs of nails incorporating a single compression screw or a compression screw coupled with an antirotating screw like the PFN, have become popular for treating unstable fractures. Biomechanical studies have proven that the helical blade, by compaction of cancellous bone around it

because it is inserted without reaming, has superior resistance to rotation and varus collapse.<sup>11</sup>

The entry point plays an important role in acceptable reduction, stable fixation, and avoiding implant-related complications.<sup>12,13</sup> It has been suggested in a study that lateral entry point causes damage to the gluteus muscle tendon while reaming of intramedullary nail insertion. The study on anatomy of greater trochanter has concluded that entry point should be at the rear tip to accommodate the implant in proximal femoral medullary canal curvature.<sup>14</sup> To achieve good quality of fixation and minimal damage to the gluteus medius, the entry point for PFNA-2 should be 5 mm medial to the greater trochanter tip. The lateral entry point showed more cases with lateral cortex impingement as compared to medial entry.<sup>15</sup>

Clinical studies have also shown that osteoporosis is associated with inferior outcomes in intertrochanteric fractures.<sup>16</sup> Therefore, various methods are being used in attempt to improve fixation in osteoporotic intertrochanteric fractures, including cement augmentation and improvements in implant design.<sup>17</sup>

Baumgaertner et al proposed the concept of tip-apex distance (TAD), which describes the optimal position of the lag screw in intertrochanteric fracture surgery.<sup>18</sup> It has been widely accepted that a lag screw or helical blade with a TAD  $\leq 25$  mm has a lower risk of devastating complications, like screw cutout or fixation failure.<sup>19,20</sup> In order to achieve a TAD  $\leq 25$  mm, the lag screw or helical blade should be inserted close to the bisector of the femoral head and femoral neck, which could be termed as the center-center position. Biomechanical evidence revealed that an inferior-center position of the lag screw or helical blade had comparable strength to the center-center position in both extramedullary and intramedullary implants.<sup>21-23</sup> An inferior-center position of the lag screw or blade with an increased TAD would not increase the fixation failure rate irrespective of the types of implants used, as compared with the center-center position. This was because of greater postoperative neck-shaft angle (valgus reduction) for those with the lag screw or blade placed inferiorly. A valgus reduction might produce a biomechanically stable environment for the hip joint.

Objective of study is to assess the functional and radiological outcomes according Harris hip scoring systems, Cleveland's index, Parker's ratio and compare them in PFN group vs PFN-A2 group and also compare the incidence of complications in each group.

## METHODS

The study was a 2 years prospective comparative study from 1<sup>st</sup> December 2020 to 1<sup>st</sup> December 2022 conducted in the department of orthopaedics, Rajendra institute of medical sciences, Ranchi, Jharkhand, India. Total number of patients were 50, PFN done in 25 cases and PFN-A2 in another 25 cases.

## Inclusion criteria

Patients with age  $>50$  years and both sexes, cases of unstable trochanteric fractures (Boyd and Griffin type II, III, IV), closed fracture and osteoporotic fractures (Singh index  $\leq 3$ ) were included in study.

## Exclusion criteria

Compound fractures, stable trochanteric fractures (Boyd and Griffin type I), patient with associated ipsilateral lower limb injuries hindering the postoperative weight bearing, patients with severe OA knee, patients having neurological co-morbidities and non-ambulant patients were excluded from study.

According to the AO classification, type 31-A1.1, 1.2, 1.3, and 2.1 were classified as stable fracture patterns while the rest types of 31-A were classified as unstable ones.

The quality of the reduction was categorized into three grades based on a modification of the method developed by Baumgaertner et al.<sup>18</sup> The first criterion used was a normal or slightly valgus neck-shaft angle ( $130^\circ$  to  $150^\circ$ ) on the AP view and an angulation  $< 20^\circ$  on the lateral view. The second criterion used was the presence of a  $< 4$  mm displacement of any fragments in the AP and lateral views. A reduction was categorized as good if both criteria were met, acceptable if only one criterion was met, and poor if neither criterion were met.

The lag screw tip position in the femoral head was classified by the Cleveland index.<sup>24</sup>

Singh's index was used to grade the radiographs for the degree of osteoporosis.<sup>25</sup> A rough judgment of the nail angle was decided as per the position of the center of the femoral head and the tip of the greater trochanter on the normal side. If the tip of the greater trochanter is higher, which means a coxa vara, an angle of  $130^\circ$  was selected.

All nails were available in 9-, 10-, and 11-mm diameters. Long nails were available in lengths from 340 to 420 mm. Short nails were available in lengths of 180 and 250 mm. Helical blades were available in 70 mm to 120 mm lengths.

The reduction was held by inserting guide wires in the anterosuperior quadrant of the head and neck, keeping in mind the trajectory of future nail. Adduction was done (which now occurs at the hip joint rather than at the fracture site) to make the greater trochanter more prominent and palpable (in obese patients) for the entry of the nail and checked under the C-arm. Entry was made with an awl at the medial sloping edge of the greater trochanter (medial to the tip of the greater trochanter). A guide wire was inserted into the femoral shaft. Reaming of the femur was done with the reamer provided with the set in the sizes 8-9-10-11-12. Proximal reaming with a proximal reamer of size 15 mm was done before the insertion of the nail. A proper-size nail was inserted with

the zig in a routine manner. For neck screws, first, the distal guide wire was inserted (parallel to the lower border of the neck) followed by the proximal one. In the case of PFNA2 likewise, a guide wire was inserted through the center of the femoral head up to the subchondral bone.

First, the 6.4 mm derotation screw was inserted followed by the 8 mm hip screw (mind the concept of the TAD). The screws were finally tightened after releasing the traction. This principle helps to prevent the Z-effect or reverse Z-effect (if we do not release the traction before tightening the screws, on transfer from the fracture table, the screw will back out). For PFNA2, a helical blade of proper size was impacted in an unlocked state, and compression of 5 mm was achieved after final positioning and releasing the traction. Distal locking was done as per the surgeon's choice (both static and dynamic versus only distal dynamic) with 4.9 mm locking screws. Usually, when the surgeon wants some micromotion on mobilization, only the distal dynamic option is selected.

Ethical approval done.

#### Statistical tool

Excel software and Microsoft words were used to analyse the data. Percentage was calculated for qualitative data.

## RESULTS

Mean age is 64.4 years in PFN group as compared to 67.3 years in PFNA2 group. PFN-A2 was done in 84% male while PFN in only 76% male and in both groups right side was mostly affected. Average surgery time, amount of blood loss, average number of C-arm shoot were more in PFN group. Even post operative hospital stay was more in PFN group, 84% cases of PFN-A2 and 76% cases of PFN were showing signs of union by 16 weeks. Mean Harris Hip score was better in PFN-A2 group.

Although parkers ratio was correlating with the Cleveland index, it wasn't found to be a reliable indicator of Implant related complications. Patients with parkers ratio less than 50 % and Cleveland index as 8, were found to have good functional outcome.

Most of the patients had nail protrusion height less than 5 mm. Similarly, on comparing neck shaft angle with the normal side, a variation of more than 10° was noted only in 5 case of PFN and 2 cases of PFN- A2. TAD was mostly in range of 20-30 mm in our study. We had 1 case each of broken implants in both the groups. Z effect was found in 8% cases of PFN. And there was 1 case of screw cut out in PFN-A2 group.

Figure 1 shows pre op X-ray of 81 years old female. In this case PFNA2 was done. This reduced time of surgery in this old lady. In figure 3, 75 years old male fracture of trochanteric region was present. This case was also treated by PFNA2. Figure 5 shows intertrochanteric fracture in 63

years old female and treated by PFN. Figure 7 shows pre op X-ray of IT fracture in left hip which treated by PFN.

**Table 1: Age, sex and side distribution.**

Variables	PFN (%)	PFN-A2 (%)
Mean age (In years)	64.4	67.3
Male	19 (76)	21 (84)
Female	6 (24)	4 (16)
Right	14 (56)	15 (6)
Left	11 (44)	10 (4)

**Table 2: Result summary.**

Variables	PFN	PFN-A2
Avg surgery time (Min)	61.3	50.5
Average blood loss (ml)	165.7	120.9
Average no. of C-Arm shots	49.1	41.8
Post op hospital stay (Days)	12.3	10.1
Radiological union at 6 months (%)	91.1	100

**Table 3: Union time.**

Week	PFN, n (%)	PFN-A2, n (%)
Upto 10 weeks	5 (20)	6 (24)
10-16 weeks	14 (56)	15 (60)
>16 weeks	6 (24)	4 (16)

**Table 4: Mean Harris hip score at different time interval postoperatively.**

HHS score at	PFN	PFN-A2
6 weeks	79.22	83.75
3 months	83.98	84.60
6 months	85.20	86.46

**Table 5: Tip apex distance.**

Variables	PFN, n (%)	PFNA2, n (%)
<20 mm	4 (16)	3 (12)
20-30 mm	16 (64)	15 (60)
>30 mm	5 (20)	7 (28)

**Table 6: Cleveland index.**

Variables	PFN, n (%)	PFN-A2, n (%)
Optimal position (5 and 8)	17 (68)	19 (57)
Suboptimal position (1-9)	8 (32)	6 (24)

**Table 7: Parkers ratio.**

Variables	PFN, n (%)	PFN-A2, n (%)
<50	18 (72)	15 (60)
>50	7 (28)	10 (40)

**Table 8: Nail protrusion height.**

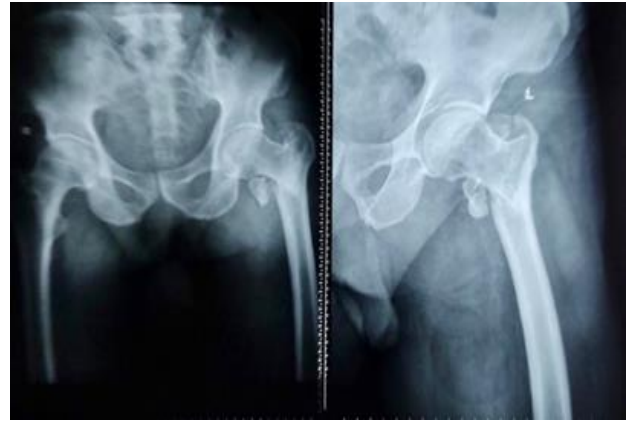Variables	PFN, n (%)	PFN-A2, n (%)
0-5 mm	20 (80)	22 (66)
>5 mm	5 (20)	3 (12)

**Table 9: Neck shaft angle.**

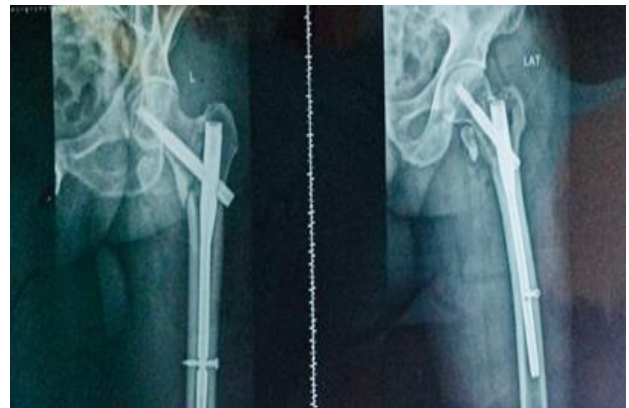Variables	PFN, n (%)	PFN-A2, n (%)
<5 mm	2 (8)	3 (12)
5-10 mm	18 (72)	20 (80)
>10 mm	5 (20)	2 (8)

**Table 10: Complications.**

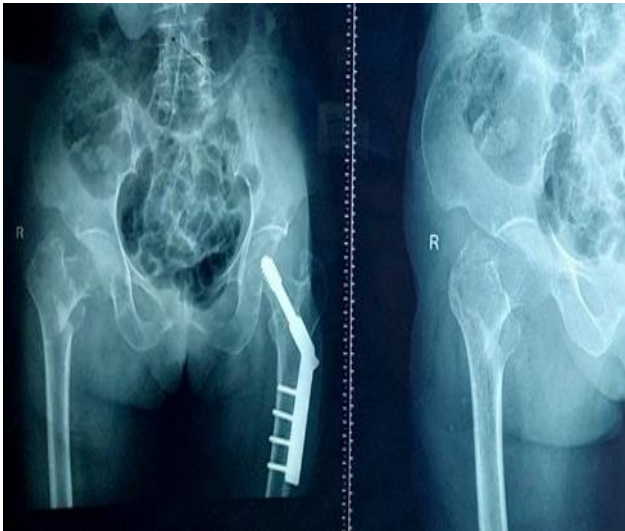
Variables	PFN, n (%)	PFN-A2, n (%)
Broken implant	1 (4)	1 (4)
Z- effect	2 (8)	0
Screw cut out	0	1 (4)
Revision surgery	2 (8)	1 (4)
Wound infection	2 (8)	1 (4)



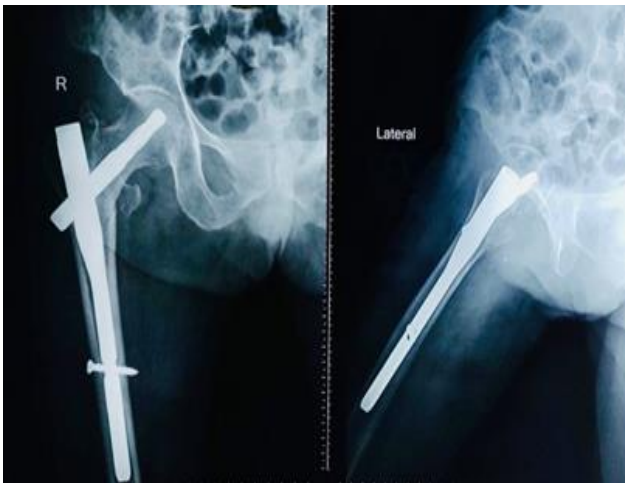
**Figure 3: A 75 years old male (case 2).**



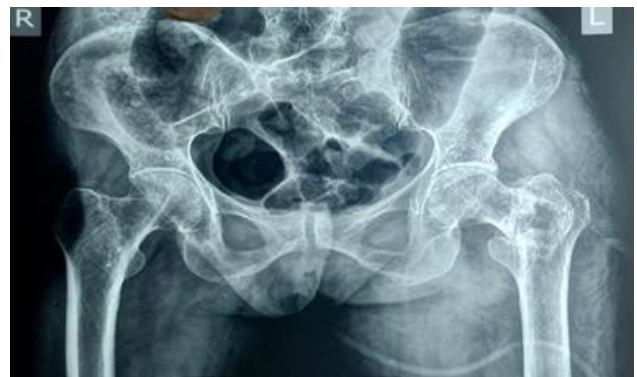**Figure 4: Post op X-ray of (case 2).**



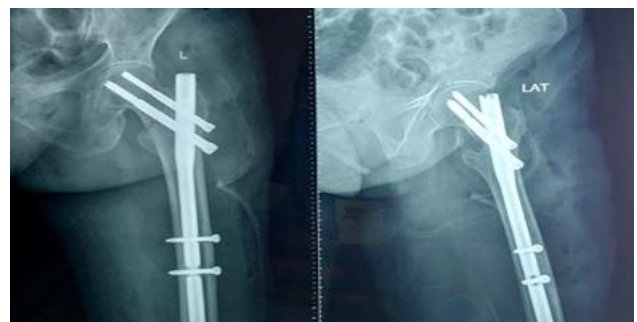**Figure 1: A 81 years old female (case 1).**



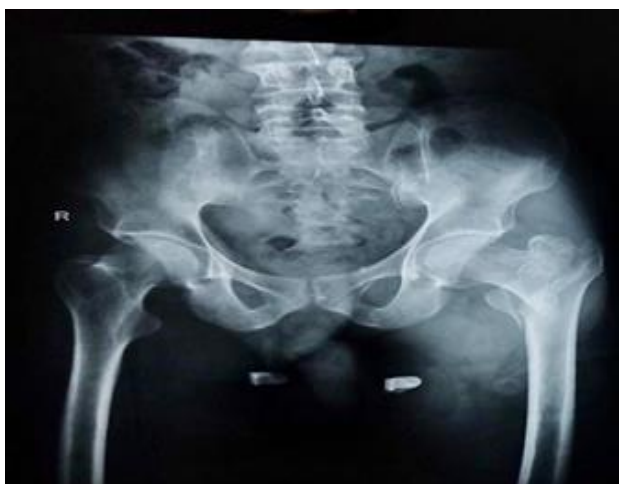**Figure 2: Post op X-ray of case 1.**



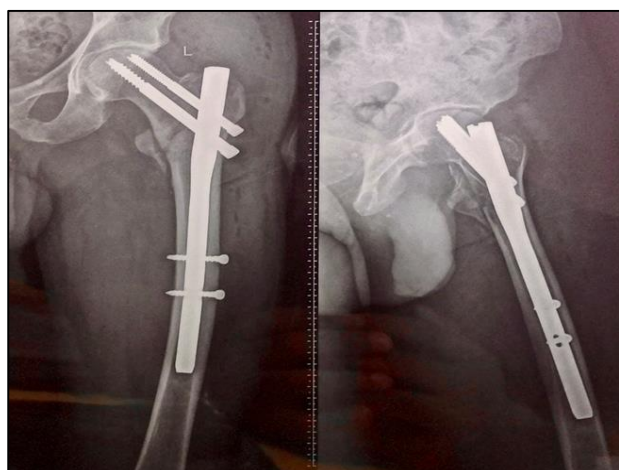**Figure 5: A 63 years old female (case 3).**



**Figure 6: Post op X-ray of (case 3).**



**Figure 7: A 55 years old male (case 4).**



**Figure 8: Post op X-ray of (case 4).**

## DISCUSSION

There is no evidence in the literature demonstrating that an intramedullary nail is superior to extramedullary devices, such as a DHS, when used for stable fracture types.<sup>26-30</sup> Biomechanically, intramedullary devices have been shown to be superior for unstable fracture types.<sup>31</sup>

Some studies have reported the occurrence of serious complications after using such procedures, including migration of the proximal screws and perforation of the femoral head, varus collapse of the fracture, cut-out, and fracture at or below the level of the terminus of the femoral nail.<sup>7,8,32</sup>

In PFN, 2 screws are used for the neck the larger screw is the lag screw to take the load. Smaller screw for rotation stability if the length of smaller screw increases vertical force increases and induces the cutout causing effect (Z-effect), or reverse Z effect.<sup>33</sup>

The first account of the Z-effect has been attributed to Werner-Tutshcku et al who reported a series of 70 cases of

fractures treated using PFN.<sup>34</sup> The Z-effect involves the lateral migration of the inferior screw, varus collapse of the fracture and perforation of the femoral head by the superior screw. The reverse Z-effect involves the lateral migration of the superior screw accompanied by the medial migration of the inferior screw. These authors also advised that fixation of the fracture at a cervico-diaphyseal angle of  $<125^\circ$  is a predisposing factor for the Z-effect and reverse Z-effect, as well as for cut-out of the femoral head by the screw. The cause of this complication has been explained by varus collapse of the fracture and the lack of medial cortical support.<sup>35</sup> When the femoral neck presented a lower bone density than the femoral head, which is typical of unstable fractures, there was a tendency for the inferior screw to migrate. Strauss et al also suggested that the use of femoral nails comprising two interlocking head screws should be avoided in cases of fractures with intense comminution and loss of medial support.<sup>35</sup> Devices with helical blades that are introduced under impaction towards the femoral head, have been designed with the aim of increasing rotational stability, preserving the bone material of the femoral head and preventing varus collapse. Although such implants offer greater biomechanical stability in comparison with conventional PFN, they are not free of complications.<sup>36</sup> Thus, Brunner et al have described three cases of perforation of the femoral head by helical blade devices in patients showing good fracture reduction and satisfactory positioning of the implant.<sup>37</sup> These authors advise that in cases of severe osteoporosis, positioning of the blade at 5 mm or less below the joint should be avoided in order to prevent perforation of the femoral head.

The change to a helical blade with the introduction of the PFNA 2 and was intended to reduce the likelihood of cut-out and to eliminate the occurrence of the Z-effect mode of failure of the old PFN. Several biomechanical studies have supported this.<sup>38</sup> The phenomenon of cut-out has however not been eliminated and is in fact still the most common mode of failure. A recent biomechanical study by Born et al. comparing threaded screw and helical blade constructs in a model of pertrochanteric fracture fixation using polyurethane femoral heads found that the blade device is more prone to cut-out.<sup>39</sup> Pu et al reported an average TAD of 16.8 mm, but suggested not putting the helical blade tip closer than 10 mm from subchondral bone and using a shorter blade in order to avoid head perforation.<sup>40</sup> Nikoloski et al believe that the TAD rule of  $<25$  mm should not apply for the PFNA2.<sup>41</sup> They suggest avoiding a TAD  $<20$  mm due to possible axial cut-out (medial migration) and avoiding a TAD  $>30$  mm to avoid cephalad cut-out.

The idea behind the innovation of the helical blade was its biomechanical superiority in the setting of osteoporosis.<sup>38</sup> The blade can be inserted without reaming, thereby preserving vital bone stock in the femoral head. During insertion, it compacts cancellous bone around it, providing a better purchase, with increased resistance to varus collapse and rotational stress.<sup>42</sup> The tip of the PFNA2 is

flexible which reduces the stress on the bone at the tip and therefore, there will be less implant failure (distal nail breakage and distal locking screw breakage).<sup>43</sup>

Park et al found significantly better mobility scores and complication rates with helical blade nails.<sup>44</sup> Gardenbroek et al in their study found that the risk of a secondary late complication and re-surgery is much higher with a PFN than the helical blade device.<sup>45</sup>

Other advantages of the helical blade device over a two-screw design reported in literature include its ease of insertion, lesser operative time and lesser fluoroscopic exposure.<sup>46-47</sup>

### Limitation

Limitation of study are small number of patients in each treatment group, a short follow-up period, a failure to measure inter-observer errors in radiographic interpretation or functional evaluation and operated by two senior surgeons.

Image results solely based on radiological findings are potential causes that might affect the study results. Our use of the Singh's index rather than a dual energy x-ray absorptiometry (DEXA) scan to assess osteoporosis was due to financial constraints and makes our inference of the effect of osteoporosis on the performance of these implants subjective.

### CONCLUSION

In this study of 50 patients, 25 treated by PFN and 25 by PFN-A2, it was concluded that PFN-A2 was a better construct to treat patients of unstable intertrochanteric fracture of older age group having osteoporosis because here reaming was not done and helical blade was inserted by hammering which caused compaction of bones in head and neck region. And result was better with favourable Cleveland index (5 centre centre position and 8 centre inferior position) and Parker ratio less than 50%. Complications were also less in PFN-A2 group.

*Funding: No funding sources*

*Conflict of interest: None declared*

*Ethical approval: The study was approved by the Institutional Ethics Committee*

### REFERENCES

- Burge R, Dawson-Hughe B, Solomon DH, Wong JB, King A, Tosteson A. Incidence and economic burden of osteoporosis-related fractures in the United States, 2005-2025. *J Bone Miner Res.* 2017;22:465-75.
- Cummings SR, Rubin SM, Black D. The future of hip fractures in the United States. Numbers, costs, and potential effects of postmenopausal estrogen. *Clin Orthop Relat Res.* 1990;252:163-6.
- Tamaki J, Fujimori K, Ikehara S, Kamiya K, Nakatoh S, Okimoto N, et al. Estimates of hip fracture incidence in Japan using the National Health Insurance Claim Database in 2012-2015. *Osteoporos In.* 2019;30:975-83.
- Sasabuchi Y, Matsui H, Lefor AK, Fushimi K, Yasunaga H. Timing of surgery for hip fractures in the elderly: A retrospective cohort study. *Injury.* 2018;49:1848-54.
- Sheehan KJ, Sobolev B, Guy P. Mortality by Timing of Hip Fracture Surgery: Factors and Relationships at Play. *J Bone Joint Surg Am.* 2017;99:e106.
- Sobolev B, Guy P, Sheehan KJ, Kuramoto L, Sutherland JM, Levy AR et al. Mortality effects of timing alternatives for hip fracture surgery. *CMAJ.* 2018;190:E923-33.
- Guimarães JAM, Guimarães ACA, Franco JS. Avaliação do emprego da haste femoral curta na fratura transtrocanterica instável do fêmur. *Rev Bras Ortop.* 2008;43:406-17.
- Tyllianakis M, Panagopoulos A, Papadopoulos A, Pappasmos S, Mousafiris. Treatment of extracapsular hip fractures with the proximal femoral nail (PFN): Long term results in 45 patients. *Acta Orthop Belg.* 2004;70:444-54.
- Zhang K, Zhang S, Yang J, Dong W, Wang S, Cheng Y et al. Proximal femoral nail vs. dynamic hip screw in treatment of intertrochanteric fractures: a meta-analysis. *Med Sci Monit.* 2014;20:1628-33.
- Kulkarni GS, Limaye R, Kulkarni M, Kulkarni S. Intertrochanteric fractures. *Indian J Orthop.* 2006;40:16-23.
- Strauss E, Frank J, Lee J, Kummer F, Tejwani N. Helical blade versus sliding hip screw for treatment of unstable intertrochanteric hip fractures: a biomechanical evaluation. *Injury.* 2006;37(10):984-9.
- Anastopoulos G, Chissas D, Dourountakis J. Computer-assisted three-dimensional correlation between the femoral neck-shaft angle and the optimal entry point for antegrade nailing. *Injury.* 2010;41(3):300-5.
- Ansari CMM, Ten HJD, Oey PL, De Kort GA, Van der Meulen W, Van der Werken C et al. Intramedullary femoral nailing through the trochanteric fossa versus greater trochanter tip: a randomized controlled study with in-depth functional outcome results. *Eur J Trauma Emergency Surg.* 2011;37(6):615-22.
- Farhang K, Desai R, Wilber JH, Cooperman DR, Liu RW. An anatomical study of the entry point in the greater trochanter for intramedullary nailing. *Bone Joint J.* 2014;96-B(9):1274-81.
- Sharan M, Surendra UK, Rajendra A, Nithin EN, Krithika K, Pragya T. The Results of Unstable Intertrochanteric Femur Fracture Treated with Proximal Femoral Nail Antirotation-2 with respect to Different Greater Trochanteric Entry Points. *Adv Ort.* 2020;2834816.
- Akan K, Cift H, Ozkan K, Eceviz E, Tasyikan L, Eren A. Effect of osteoporosis on clinical outcomes in

- intertrochanteric hip fractures treated with a proximal femoral nail. *J Int Med Res.* 2011;39(3):857-65.
17. Gupta RK, Gupta V, Gupta N. Outcomes of osteoporotic trochanteric fractures treated with cement-augmented dynamic hip screw. *Indian J Orthop.* 2012;46(6):640-45.
  18. Baumgaertner MR, Curtin SL, Lindskog DM, Keggi JM. The value of the tip-apex distance in predicting failure of fixation of peritrochanteric fractures of the hip. *J Bone Joint Surg Am.* 1995;77:1058-64.
  19. Andruszkow H, Frink M, Frömke C, Matityahu A, Zeckey C, Mommsen P et al. Tip apex distance, hip screw placement, and neck shaft angle as potential risk factors for cut-out failure of hip screws after surgical treatment of intertrochanteric fractures. *In Orthop.* 2012;36:2347-54.
  20. Rubio-Avila J, Madden K, Simunovic N, Bhandari M. Tip to apex distance in femoral intertrochanteric fractures: a systematic review. *I Orthop Sci.* 2013;18:592-8.
  21. Kuzyk PR, Zero R, Shah S, Olsen M, Waddell JP, Schemitsch EH. Femoral head lag screw position for cephalomedullary nails: a biomechanical analysis. *J Orthop Trauma.* 2012;26:414-21.
  22. Wu CC, Shih CH, Lee MY, Tai CL. Biomechanical analysis of location of lag screw of a dynamic hip screw in treatment of unstable intertrochanteric fracture. *J Trauma.* 1996;41:699-702.
  23. Kane P, Vopat B, Heard W, Thakur N, Paller D, Koruproluet S et al. Is tip apex distance as important as we think? A biomechanical study examining optimal lag screw placement. *Clin Orthop Relat Res.* 2014;472:2492-8.
  24. Cleveland M, Bosworth DM, Thompson FR, Wilson HJ Jr, Ishizuka T. A ten-year analysis of intertrochanteric fractures of the femur. *J Bone Joint Surg Am.* 1959;41-a:1399-408.
  25. Singh M, Nagrath AR, Maini PS. Changes in trabecular pattern in the upper end of the femur as an index of osteoporosis. *J Bone Joint Surg Am.* 1970;52(1):457-67.
  26. Baumgaertner MR, Curtin SL, Lindskog DM: Intramedullary versus extramedullary fixation for the treatment of intertrochanteric hip fractures. *Clin Orthop Relat Res.* 1998;348:87-94.
  27. Lenich A, Mayr E, Ruter A, Möckl C, Füchtmeier B. First results with the trochanter fixation nail (TFN): a report on 120 cases. *Arch Orthop Trauma Surg.* 2006;126:706-12.
  28. Saudan M, Lübbecke A, Sadowski C, Riand N, Stern R, Hoffmeyer P. Peritrochanteric fractures: is there an advantage to an intramedullary nail? A randomized, prospective study of 206 patients comparing the dynamic hip screw and proximal femoral nail. *J Orthop Trauma.* 2002;16(6):386-93.
  29. Butt MS, Krikler SJ, Nafie S, Ali MS. Comparison of dynamic hip screw and gamma nail: a prospective, randomized, controlled trial. *Injury.* 1995;26:615-8.
  30. Zou J, Xu Y, Yang H. A comparison of proximal femoral nail antirotation and dynamic hip screw devices in trochanteric fractures. *J Int Med Res.* 2009;37(4):1057-64.
  31. Rethnam U, Cordell-Smith J, Kumar TM, Simha A. Complex proximal femoral fractures in the elderly managed by reconstruction nailing - complications and outcomes: a retrospective analysis. *J Trauma Manag Outcomes.* 2007;1(7):1-7.
  32. Adams CI, Robinson CM, Court Brown CM, McQueen MM. Prospective randomized study-controlled trial of an Intramedullary Nail versus dynamic screw or plate for intertrochanteric fractures of femur *J Ortho Trauma.* 2001;15(6):394-400.
  33. Werner-Tutschku W, Lajtai G, Schmiedhuber G, Lang G, Pirkl C, Orthner E. Intra-und perioperative Komplikationen bei der Stabilisierung von per-und subtrochantären Femurfrakturen mittels PFN. *Unfallchirurg.* 2002;105:881-5.
  34. Strauss EJ, Kummer FJ, Koval KJ, Egol KA. The "Z-effect" phenomenon defined: a laboratory study. *J Orthop Res.* 2007;25:1568-73.
  35. Al-yassari G, Langstaff RJ, Jones JW, Al-Lami M. The AO/ASIF proximal femoral nail (PFN) for the treatment of unstable trochanteric femoral fracture. *Injury.* 2002;33:395-9.
  36. Brunner A, Jöckel JA, Babst R. The PFNA proximal femoral nail in treatment of unstable proximal femur fractures-3 cases of postoperative perforation of the helical blade into the hip joint. *J Orthop Trauma.* 2008;22:731-6.
  37. Strauss E, Frank J, Lee J, Kummer F, Tejwani N. Helical blade versus sliding hip screw for treatment of unstable intertrochanteric hip fractures: a biomechanical evaluation. *Injury.* 2006;37(10):984-9.
  38. Born C, Karich B, Bauer C, von Oldenburg G, Augat P. Hip screw migration testing: first results for hip screws and helical blades utilizing a new oscillating test method. *J Orthop Res.* 2011;29(5):760-66.
  39. Pu JS, Liu L, Wang GL, Fang Y, Yang TF. Results of the proximal femoral nail anti-rotation (PFNA) in elderly Chinese patients. *Int Orthop.* 2009;33(5):1441-4.
  40. Andrej NN, Anthony LO, Piers JY. Should the tip-apex distance (TAD) rule be modified for the proximal femoral nail antirotation (PFNA)? A retrospective study. *J Orthop Surg Res.* 2013;8:35.
  41. Gavaskar A, Subramanian M, Tummala N. Results of proximal femoral nail antirotation for low velocity trochanteric fractures in the elderly. *Indian J Orthop.* 2012;46(5):556-60.
  42. Simmormacher RK, Ljungquist J, Baish H, Hockertz T, Vochteloo AJH, Ochs U et al. The new Proximal Femoral Nail Antirotation in daily practice; results of a multicentric clinical study *Injury.* 2008;39(8):932-9.
  43. Park JH, Lee YS, Park JW, Wang JH, Kim JG. A comparative study of screw and helical proximal femoral nails for the treatment of intertrochanteric fractures. *Orthopaedics.* 2010;33(2):81-5.

44. Gardenbroek T, Segers M, Simmermacher R, Hammacher E. The proximal femoral nail antirotation: an identifiable improvement in the treatment of unstable pertrochanteric fractures? *J Trauma.* 2011;71(1):169-74.
45. D'Arrigo C, Carcangiu A, Perugia D, Scapellato S, Alonzo R, Frontini S et al. Intertrochanteric fractures: Comparison between two different locking nails. *Int Orthop.* 2012;36:2545-51.
46. Xu Y, Geng D, Yang H, Wang X, Zhu G. Treatment of unstable proximal femoral fractures: comparison of the proximal femoral nail antirotation and gamma nail 3. *Orthopedics.* 2010;33(7):473.
47. Garg B, Marimuthu K, Kumar V, Malhotra R, Kotwal PP. Outcome of short proximal femoral nail antirotation and dynamic hip screw for fixation of unstable trochanteric fractures. A randomised prospective comparative trial. *Hip Int.* 2011;21:536.

**Cite this article as:** Prakash V, Singh N, Gupta GK, Prabhat V. Comparative study of functional and radiological outcomes of the usage of two devices, derotation type cephalomedullary nail and the helical blade type in unstable intertrochanteric fractures in the geriatric population at a tertiary-level center. *Int J Res Orthop* 2024;10:35-42.