

Original Research Article

Osteological morphometric analysis of instrumentation safe zones of C1 and C2 vertebra in North Indian population: a multicentric study

Tushar Gogia¹, Tirthankar Dasgupta¹, Neha Goel², Narender Singh¹,
Aravind Rajan^{1*}, Mainak Das³, Dhairya Khera¹

¹Department of Orthopaedic Surgery, Army College of Medical Sciences and Base Hospital, Delhi, India

²Department of Radio diagnosis and Interventional Radiology, Max Smart Super Speciality Hospital, Saket, New Delhi, India

³Department of Orthopaedics, 5 Airforce Hospital, Jorhat, Assam, India

Received: 25 September 2023

Revised: 02 October 2023

Accepted: 10 October 2023

*Correspondence:

Dr. Aravind Rajan,

E-mail: orthodocresearch@gmail.com

Copyright: © the author(s), publisher and licensee Medip Academy. This is an open-access article distributed under the terms of the Creative Commons Attribution Non-Commercial License, which permits unrestricted non-commercial use, distribution, and reproduction in any medium, provided the original work is properly cited.

ABSTRACT

Background: The complex anatomy and critical functional role of the C1 and C2 vertebrae necessitate precise understanding of safe zones for instrumentation to mitigate risks during surgical interventions. This study aimed to conduct a comprehensive morphometric analysis to identify and characterize safe zones for instrumentation within C1 and C2 vertebrae. Though there are multiple radiological based studies, actual osteological measurements are not available for North Indian population.

Methods: 200 atlas and axis vertebrae were measured within an accuracy of 0.01 mm to ascertain various dimensions, distances and angles to guide safe exposure and instrumentation. To the best of our knowledge this observational morphometric study is first to provide actual osteological measurements in large number of C1 and C2 vertebrae in North Indian population.

Results: The morphometric analysis revealed precise measurements of pedicle dimensions, transverse foramen parameters, and distances from key anatomical landmarks within C1 and C2 vertebrae. Safe zones for instrumentation were identified based on these measurements, considering the optimal implant size and trajectory to minimize the risk of neural or vascular damage. Differences between the morphology of North Indian, South Indian and Turkish C1 and C2 morphology was also identified.

Conclusions: This study provides critical insights into the morphometric parameters which can be used to identify safe zones for instrumentation within the C1 and C2 vertebrae. The identified safe zones and associated measurements are essential for optimizing surgical strategies, enhancing instrumentation accuracy, and ultimately improving patient outcomes during craniovertebral surgical procedures. Spine Surgeons can utilize this data to tailor surgical approaches and implant placements, promoting safer and more effective interventions in the challenging anatomical region of the craniovertebral junction.

Keywords: Atlas, Axis, Morphometric analysis, Safe zones, Pedicle screw, Cervical spine surgery, Odontoid fracture, Vertebral artery damage

INTRODUCTION

The first two cervical vertebrae, namely the atlas (C1) and the axis (C2), have complex anatomical features which

differentiate them from other cervical vertebrae. They are an integral part of the cranio-cervical complex comprising the occipital bone, the atlas and the axis. As trauma is the most frequent etiology for problems in this region, which

frequently need surgical reconstruction. Tumours, degenerative and inflammatory diseases, infections, vascular problems, congenital malformations and iatrogenic reasons are other frequent reasons of the instability of the cranio-cervical complex which also may require surgical instrumentation.

The occipito-atlas (atlanto-occipital) joint is critically located close to the vital centres of the medulla oblongata, which can get compressed by the dislocation of the atlanto-axial complex or the instability of the atlanto-occipital joint.

The vertebral artery on its way from foramen transversarium to the formation of basilar artery in the cranial cavity is vulnerable to damage or distortion from external factors like bony or ligamentous structures. The retro-articular canal of the atlas vertebra (formed by posterior bridging) is one such example which may cause external pressure on vertebral artery.^{1,2}

The second cervical vertebra, acts as the axle for the rotation of the head. A deep groove is formed by the vertebral artery in anterolateral surface of pedicle axis, which runs cranially near the facies articularis superior and leaves from transverse foramen of the atlas and then curves posteriorly over the posterior arch of the atlas.⁴ The vertebral artery may be injured during the exposure especially with the lateral or postero-lateral approaches, which are carried out to treat instability of the occipito-atlanto-axis region.⁵ Anomalous development of the odontoid is uncommon, and its clinical significance lies in its potential for producing fractures leading to serious neurologic sequelae.⁶ These anomalies include either odontoid invagination, in which the odontoid process bulges upward into the foramen magnum and compresses the brainstem without deformity of the occipital bone, or Congenital and developmental osseous abnormalities and anomalies that affect the cranio-cervical junction complex which can result in neural compression and vascular compromise and can manifest itself with abnormal cerebrospinal fluid dynamics.^{7,8} Chiari I malformations are often associated with congenital cranio-cervical anomalies, such as platybasia, basilar invagination, and retroflexion of the odontoid process.⁹

There are several surgical methods for the treatment of these pathologies like anterior transoral fixation, anterolateral C1-2 trans-articular fixation, posterior trans-articular screw fixation, posterior wirings and other clamping techniques. However, the current techniques of stabilization either poses a risk to injuring the vertebral artery, are not stable enough, or cause loss of motion of the occipito-cervical joint.¹⁰ The working area is rather narrow in the anterior intraoral approach, and it has a very high risk for the infections and fistulas of the cerebrospinal fluid. It is also noted that the extra oral retropharyngeal approach has relatively narrow working area.¹¹ Cranial and other nerve injuries (laryngeal nerve and hypoglossal

nerve) have been reported after some of these techniques.^{12,13}

A variety of complications for posterior trans-articular fixation have also been reported such as dural tears, infarcts of the brainstem because of vascular injuries, pseudoarthrosis and placement of the screw in the wrong direction.¹⁴ It must be noted that, even if the variations of this region are very small, they can cause very serious complications due to complex anatomy of the craniocervical region.¹⁵

Current stabilization methods may not be feasible when there is vertebral artery anomaly, unilateral vertebral artery occlusion, or erosion of lateral mass by a degenerative process or tumor invasion into C1 lateral mass or the C2 pedicle. This is due to higher risk of injuring the vertebral artery or those risks associated when one of these factors involves the area where the screw is intended to be inserted.¹⁶⁻¹⁸

Many surgical approaches need the correct and common landmarks to place implants such as screws and plates. Structural features of the materials used in the surgery such as the thickness of the screw and screw length, also need accurate morphometric knowledge.¹⁹ It is useful to know the important landmarks, which are helpful to shorten the time needed for surgery, to decrease the frequencies of the complications, and to reveal the differences between different populations before the surgery.

The objective of this study was to conduct a comprehensive observational morphometric analysis to evaluate the various dimensions of the first two vertebrae, their relationship with vertebral artery foramen and to identify and characterize safe zones for instrumentation within C1 and C2 vertebrae using different surgical approaches. Though there are multiple radiological based studies, actual osteological measurements are not available for North Indian population.

METHODS

A total of three hundred fifty-two human C1 and four hundred and three C2 vertebrae from the anatomy department of M.L.N. Medical college, Allahabad; KGMC Lucknow; GSVM Medical College Kanpur, and ACMS Delhi were examined. All samples were inspected to ensure that the vertebrae were intact before measurements were made. The inclusion criteria were intact vertebrae free from disease and exclusion was and presence of osteophytes, tumors or deformity. After careful application of inclusion and exclusion criteria, two hundred human C1 and C2 vertebrae each were chosen for further morphometric analysis.

All parameters were measured using a calliper accurate to 0.1 mm for linear measurements (Figure 1); angular measurements made with standard goniometer accurate to

1 degree. Different parameters for C1 and C2 as described in figures were defined and measured.



Figure 1: Measurement using Calliper (accurate to 0.01 mm).

Type of study

Type of the study was observational morphometric study.

Duration of study

The study conducted for 15 months (Sep 2020 to Nov 2021).

Statistical analysis

Data were summarized as Mean±SD (standard deviation). Paired (left and right) groups were compared by paired t test. Independent groups were compared by Student’s t test. Pearson correlation analysis was used to assess association between the variables. A two-tailed ($\alpha=2$) p value less than 0.05 ($p<0.05$) was considered statistically significant. All analyses were performed on SPSS software (Windows version 17.0).

Procedure of measurements

Atlas

Description of atlas measurements taken from superior aspect (A-J) and from inferior aspect (K-L) (Figure 2 and 3).

Axis

Description of axis measurements taken from the anterior-posterior aspect (A-H), supero-inferior aspect (I-P) and lateral aspect (R) (Figure 4-6).

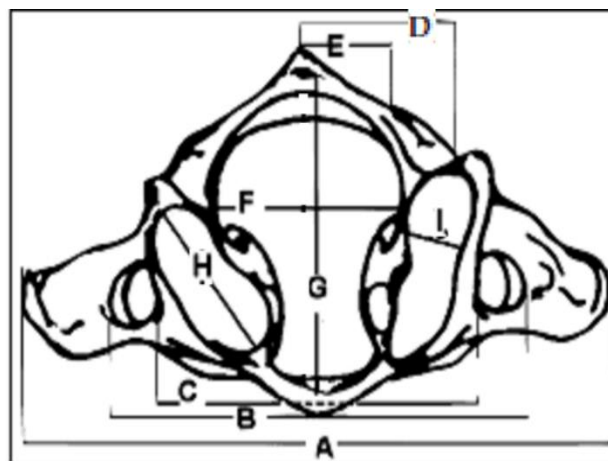


Figure 2: Atlas measurements taken from the superior aspect.

(A) The width of atlas as the distance between both tip of transverse process. (B) Outer distance of vertebral artery foramen measured as the distance between both lateral-most edges of the transverse foramen. (C) Inner distance of vertebral artery foramen measured as the distance between both lateral-most edges of the transverse foramen. (D) Outer distance of vertebral artery groove measured as the distance from Midline to the lateral-most edge of the vertebral artery groove on outer cortex. (E). Inner distance of vertebral artery groove measured as the distance from midline to the medial most edge of the vertebral artery groove on inner cortex. (F) The maximum transverse diameter of the vertebral canal measured along the frontal plane passing through the canal’s midpoint. (G) The maximum A-P diameter of the vertebral canal measured along the midsagittal plane passing through the canal’s widest point. (H) The length of superior articular facets measured as the A-P dimension of articular surface. (I) The width of superior articular facets measured as the transverse dimension of articular surface.

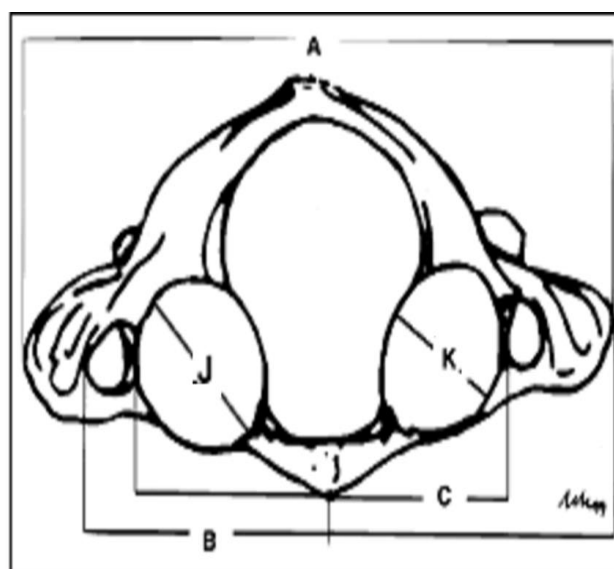


Figure 3: Atlas measurements taken from the inferior aspect.

(J) The length of inferior articular facets measured as the A-P dimension of articular surface. (K) The width of inferior articular facets measured as the transverse dimension of articular surface.

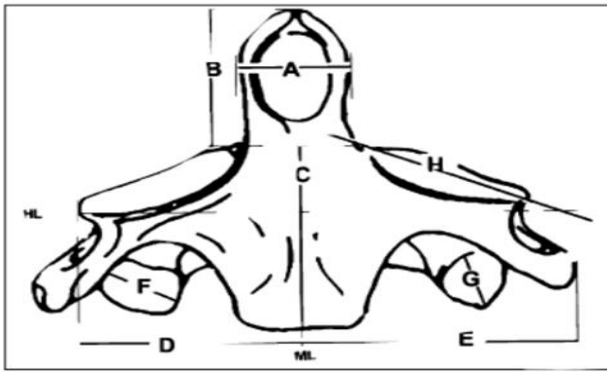


Figure 4: Axis measurements taken from anterior-posterior aspect.

(A) The width of dens axis measured as the widest diameter of dens axis on coronal plane. (B) The height of dens axis measured as the distance from the tip of dens axis to the horizontal line, which arbitrarily passed superior to superior articular facets of axis. (C) Height of anterior corpus axis measured as the distance from the line, which arbitrarily passed superior to superior facets to the lowest point corpus of axis on midline. (D) The distance of the superior articular facet measured as distance from most lateral border of superior articular facets of axis to the midline. (E) The distance of transverse process measured the distance from the most lateral border of the transverse processes of axis to the midline. (F) Length of inferior articular facets measured as A-P dimension of articular surface. (G) The width of inferior articular facets measured as the transverse dimension of articular surface. (H) Superior articular facet frontal angle measured as an opening supposed to be superior facets and the line, which arbitrarily passed superior to them on transverse plane.

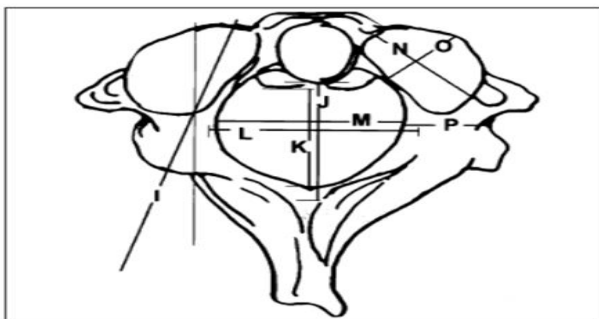


Figure 5: Axis measurements taken from superior-inferior aspect.

(I) Pedicle horizontal angle measured as a trajectory from back of pedicle to superior facet, farthest to vertebral artery foramen, localized in the thickest part of pedicle, according to parasagittal midline on transverse plane. (J) Maximum A-P diameter of vertebral canal measured along the midsagittal plane passing through canal's widest point. (K) Min A-P diameter of vertebral canal measured along midsagittal plane passing through canal's narrowest point. (L) Max transverse diameter of vertebral canal measured along frontal plane passing through canal's midpoint. (M) Minimum transverse diameter of vertebral canal measured along frontal plane passing through canal's narrowest point. (N) Length of superior articular facets measured as AP dimension of articular surface. (O) Width of superior articular facets measured as transverse dimension of articular surface. (P) Pedicle width measured as distance from axis' external surface to internal surface at level of transverse foramen.

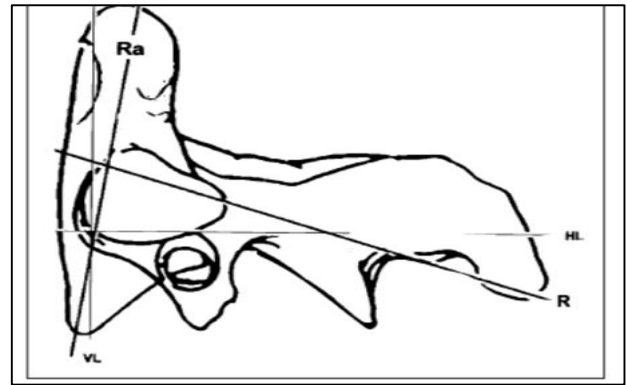


Figure 6: Measurements taken from the lateral view of the axis.

(R) The pedicle sagittal angle measured as a trajectory from back of pedicle to superior facet, the farthest to vertebral artery foramen, localized in the thickest part of pedicle, according to horizontal line on sagittal plane (Ra). Dens axis sagittal angle measured as a narrow angle between an axis that was supposed to passing longitudinally to dens axis and vertical line on sagittal plane. HL: Horizontal line, VL: Vertical line.

RESULTS

Atlas vertebrae

The measurements of atlas vertebrae were all linear. Some of measurements were independent, while some of them were paired, i.e., measured for left and right side both.

Individual values have been summarised in Table 1, which reveals that mean (\pm SD) measurement of distance between both tip of transverse process was the highest (71.34 ± 6.01) followed by distance between both lateral most edge of transverse foramen (57.43 ± 4.62), distance between both medial most edge of transverse foramen (48.24 ± 4.55), A-P dimension of vertebral canal (28.96 ± 2.10), transverse dimension of vertebral canal (26.71 ± 2.12), A-P diameter of superior articular facet (22.08 ± 1.91), distance from midline to lateral most edge of vertebral artery groove on outer cortex (20.26 ± 2.54), A-P diameter of inferior articular facet (18.20 ± 1.39), transverse diameter of inferior articular facet (14.89 ± 1.23), distance from midline to medial most edge of vertebral artery groove on inner cortex (11.75 ± 2.01) and transverse diameter of superior articular facet (11.53 ± 2.01) being the least.

Further, comparing the paired measurements (the left and the right sided values have been compared to each other in Table 1 and Figure 7 and 8), using paired t test, revealed significantly different and higher right distance from midline to medial most edge of vertebral artery groove on inner cortex as compared to left (11.67 ± 1.99 vs. 11.83 ± 2.10 , $t=2.30$, $p=0.023$). A significantly different and higher left A-P diameter of superior articular facet as compared to right (22.23 ± 2.17 vs. 21.93 ± 1.97 , $t=2.06$, $p=0.041$). However, distance from midline to lateral most edge of vertebral artery groove on outer cortex, transverse diameter of superior articular facet, A-P diameter of

inferior articular facet and transverse diameter of inferior articular facet were not significantly different ($p>0.05$) between the two sides i.e., found to be the statistically same.

The inter-correlation of the measurements is summarized in the Table 2. Most of the measurements showed significant ($p<0.05$ or $p<0.01$ or $p<0.001$) and the positive

(direct) correlation with each other. Highest value of the correlation was found in between the distance between both lateral most edge of transverse foramen as well as the distance between both medial most edge of the transverse foramen ($r=0.73$ and $p<0.001$), and, the distance between both tip of transverse process and distance between both lateral most edge of the transverse foramen ($r=0.71$, and $p<0.001$).

Table 1: Linear anatomic parameter measurements of atlas vertebrae of north Indian population, (n=200).

Abbreviation	ATLAS parameters	Range (min-max)	Mean±SD	T value	P value
A	Distance b/w both tip of transverse process (mm)	51.62-84.72	71.34±6.01	-	-
B	Distance b/w both lateral most edge of transverse foramen (mm)	45.20-73.75	57.43±4.62	-	-
C	Distance b/w both medial most edge of transverse foramen	38.60-63.68	48.24±4.55	-	-
D	Distance from midline to lateral most edge of vertebral artery groove on outer cortex (mm):	10.90-26.09	20.26±2.54	-	-
	Left	10.96-25.65	20.21±2.54	1.03	0.304
	Right	10.72-27.18	20.32±2.66		
E	Distance from midline to medial most edge of vertebral artery groove on inner cortex (mm):	5.75-21.59	11.75±2.01	-	-
	Left	6.01-20.51	11.67±1.99	2.30	0.023
	Right	5.49-22.67	11.83±2.10		
F	Transverse dimension of vertebral canal (mm)	22.85-36.90	26.71±2.12	-	-
G	A-P dimension of vertebral canal (mm)	22.45-36.12	28.96±2.10	-	-
H	A-P diameter of superior articular facet (mm):	16.73-25.76	22.08±1.91	-	-
	Left	15.60-26.04	22.23±2.17	2.06	0.041
	Right	16.44-26.20	21.93±1.97		
I	Transverse diameter of superior articular facet (mm):	8.48-17.65	11.53±2.01	-	-
	Left	8.53-17.84	11.56±2.10	0.51	0.609
	Right	7.75-19.35	11.49±2.20		
J	A-P diameter of inferior articular facet (mm):	14.72-21.15	18.20±1.39	-	-
	Left	14.47-21.92	18.13±1.45	1.48	0.140
	Right	14.18-21.46	18.26±1.49		
K	Transverse diameter of inferior articular facet (mm):	10.89-19.61	14.89±1.23	-	-
	Left	11.14-19.60	14.95±1.24	1.63	0.105
	Right	10.64-19.61	14.84±1.34		

The left and right measurements were compared by paired t test. (-): not comparable.

Axis vertebrae

The linear and angular measurements of 200 dried human axis vertebrae from North Indian population were studied. The linear measurements have been calibrated in millimeters (mm), and, the angular measurements have been calibrated in degrees ($^{\circ}$). The measurements are summarized in Table 3. Among linear measurements, the mean (\pm SD) measurement of distance from tip of transverse process to midline was the highest (27.67 ± 2.43), while, width of pedicle the least (8.19 ± 1.41). Similarly, among the angular measurements, the mean (\pm SD) measurement of pedicle horizontal angle was the highest (16.27 ± 4.11), while, dens sagittal angle the least (4.68 ± 4.15).

Further, comparing the left and right sided mean measurements of paired parameters (Table 3 and Figure 9 and 10), paired t test revealed significantly different and higher left sided distance from lateral edge of superior articular facet to midline as compared to right (22.64 ± 1.83 vs. 22.28 ± 1.94 , $t=3.22$, $p=0.002$). Further, the mean left sided maximum length of inferior articular facet was also found to be significantly different and higher as compared to right (12.62 ± 1.61 vs. 12.15 ± 1.74 , $t=2.67$, $p=0.009$). However, distance from tip of transverse process to midline, maximum width of inferior articular facet, superior articular facet frontal angle, pedicle horizontal angle, maximum length of superior articular facet, maximum width of superior articular facet, width of pedicle and pedicle sagittal angle between the two sides

(i.e., the right and left) were found to be statistically the same ($p>0.05$). The inter-correlation of linear and angular measurements is summarised in Table 4. Like atlas, most of the linear and angular measurements of the axis vertebrae also showed significant ($p<0.05$ or $p<0.01$ or $p<0.001$) and positive (direct) correlation with each other.

The highest between maximum transverse diameter of vertebral canal and minimum transverse diameter of vertebral canal ($r=0.76$, $p<0.001$) followed by maximum AP diameter of vertebral canal and minimum AP diameter of vertebral canal ($r=0.69$, $p<0.001$), width of dens and height of dens ($r=0.64$, $p<0.001$), and distance from lateral edge of superior articular facet to midline and distance from tip of transverse process to midline ($r=0.54$, $p<0.001$). Conversely, height of dens and pedicle horizontal angle ($r=-0.18$, $p<0.05$), superior articular facet frontal angle and maximum transverse diameter of vertebral canal ($r=-0.19$, $p<0.05$), and minimum transverse diameter of vertebral canal and width of pedicle ($r=-0.19$, $p<0.05$) showed significant and negative (inverse) correlation. However; especially, maximum length of inferior articular facet did not show significant ($p>0.05$) correlation with other variables.

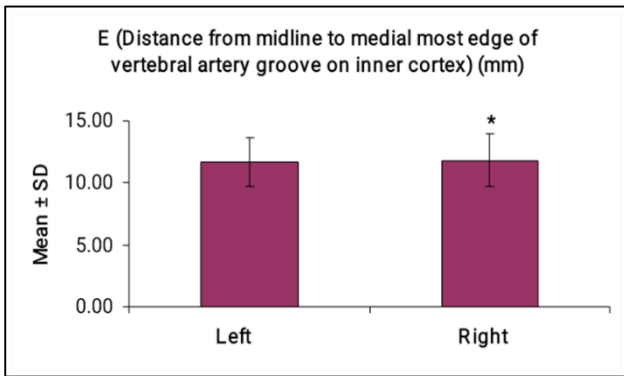


Figure 7: Comparative left and right mean distance from midline to medial most edge of vertebral artery groove on inner cortex of north Indian population.
* $p<0.05$ - as compared to left.

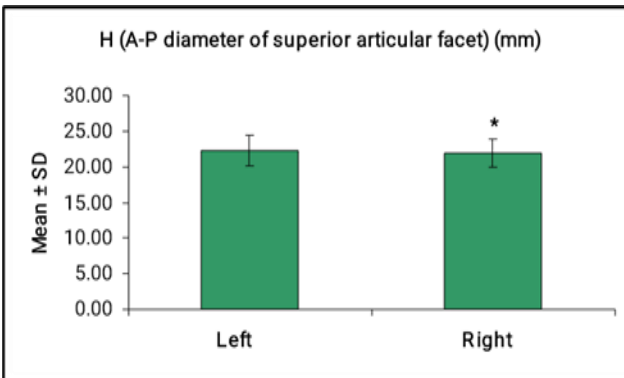


Figure 8: Comparative left and right mean A-P diameter of superior articular facet of north Indian population.
* $p<0.05$ - as compared to left.

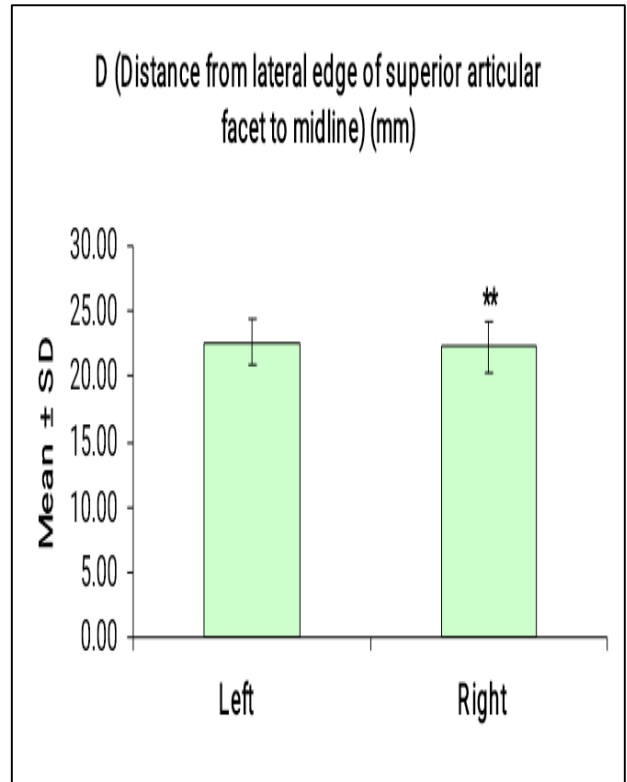


Figure 9: Comparative left and right mean distance from lateral edge of superior articular facet to midline of north Indian population.
** $p<0.01$ - as compared to left.

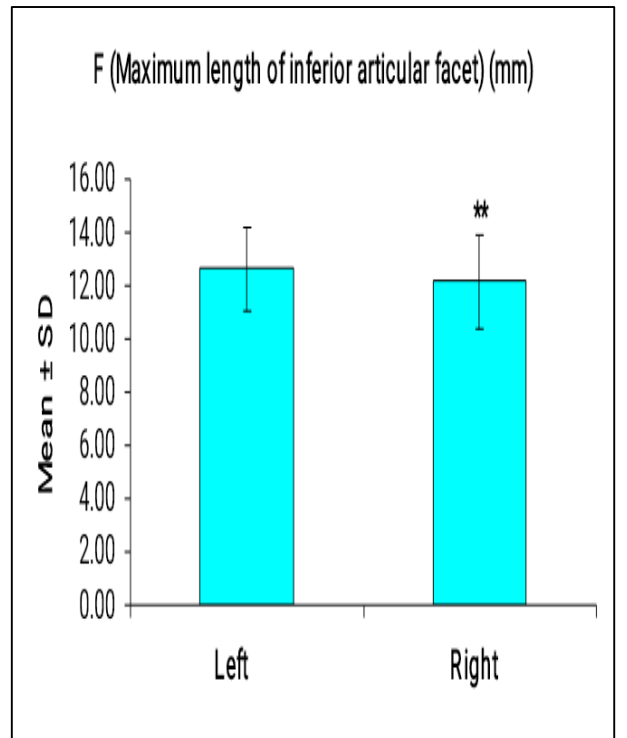


Figure 10: Comparative left and right mean maximum length of inferior articular facet of north Indian population.
** $p<0.01$ - as compared to left.

Table 2: Inter-correlation of linear ATLAS parameters of north Indian population, (n=200).

Variables	A	B	C	D	E	F	G	H	I	J	K
A	1.00										
B	0.71***	1.00									
C	0.58***	0.73***	1.00								
D	0.26**	0.27**	0.26**	1.00							
E	0.23*	0.09 ^{ns}	0.05 ^{ns}	0.31***	1.00						
F	0.43***	0.56***	0.45***	0.22*	0.40***	1.00					
G	0.28**	0.25**	0.16 ^{ns}	-0.01 ^{ns}	0.00 ^{ns}	0.25**	1.00				
H	0.34***	0.35***	0.41***	0.14 ^{ns}	0.06 ^{ns}	0.26**	0.34***	1.00			
I	-0.02 ^{ns}	0.04 ^{ns}	-0.14 ^{ns}	0.13 ^{ns}	0.16 ^{ns}	0.19*	0.10 ^{ns}	0.04 ^{ns}	1.00		
J	0.27**	0.38***	0.32***	0.28**	0.19*	0.35***	0.29**	0.35***	0.27**	1.00	
K	0.33***	0.34***	0.27**	0.19*	0.06 ^{ns}	0.05 ^{ns}	0.16 ^{ns}	0.16 ^{ns}	0.25**	0.41***	1.00

ns- p>0.05, *- p<0.05, **- p<0.01, ***- p<0.001. Correlation was done by using Pearson correlation analysis. A: Distance b/w both tip of transverse process, B: Distance b/w both lateral most edge of transverse foramen, C: Distance b/w both medial most edge of transverse foramen, D: Distance from midline to lateral most edge of vertebral artery groove on outer cortex, E: Distance from midline to medial most edge of vertebral artery groove on inner cortex, F: Transverse dimension of vertebral canal, G: A-P dimension of vertebral canal, H: A-P diameter of superior articular facet, I: Transverse diameter of superior articular facet, J: A-P diameter of inferior articular facet, K: Transverse diameter of inferior articular facet.

Table 3: Linear and angular anatomic parameter measurements of AXIS vertebrae of north Indian population, (n=200).

Abbreviation	AXIS parameters	Range (min-max)	Mean ± SD	T value	P value
A	Width of dens (mm)	7.46-11.77	9.43±0.86	-	-
B	Height of dens (mm)	10.22-19.13	15.36±1.70	-	-
C	Height of anterior corpus (mm)	14.97-24.24	20.27±1.79	-	-
D	Distance from lateral edge of superior articular facet to midline (mm):	17.82-29.98	22.46±1.78	-	-
	Left	18.67-30.44	22.64±1.83	3.22	0.002
	Right	16.35-29.52	22.28±1.94		
E	Distance from tip of transverse process to midline (mm):	21.28-34.04	27.67±2.43	-	-
	Left	21.34-34.88	27.72±2.57	0.72	0.476
	Right	21.01-33.20	27.63±2.47		
F	Maximum length of inferior articular facet (mm):	9.56-16.85	12.39±1.37	-	-
	Left	9.16-18.51	12.62±1.61	2.67	0.009
	Right	8.83-20.30	12.15±1.74		
G	Maximum width of inferior articular facet (mm):	6.61-13.79	9.59±1.42	-	-
	Left	5.86-15.12	9.50±1.61	1.40	0.165
	Right	5.77-14.65	9.69±1.61		
H	Superior articular facet frontal angle (degree):	9.00-26.50	14.43±3.99	-	-
	Left	9.00-28.00	14.53±4.38	0.92	0.358
	Right	9.00-25.00	14.34±3.87		
I	Pedicle horizontal angle (degree):	9.50-26.00	16.27±4.11	-	-
	Left	9.00-30.00	16.26±4.18	0.08	0.939
	Right	9.00-30.00	16.28±4.37		

Continued.

Abbreviation	AXIS parameters	Range (min-max)	Mean ± SD	T value	P value
J	Maximum AP diameter of vertebral canal (mm)	14.88-23.82	19.21±1.69	-	-
K	Minimum AP diameter of vertebral canal (mm)	11.91-17.75	15.11±1.23	-	-
L	Maximum transverse diameter of vertebral canal (mm)	18.40-27.14	22.70±1.69	-	-
M	Minimum transverse diameter of vertebral canal (mm)	17.73-24.76	21.36±1.67	-	-
N	Maximum length of superior articular facet (mm):	13.32-20.53	17.76±1.50	-	-
	Left	11.68-22.12	17.66±1.72	1.74	0.085
Right	12.32-21.25	17.87±1.55			
O	Maximum width of superior articular facet (mm):	10.07-18.08	15.20±1.31	-	-
	Left	11.11-18.51	15.27±1.40	1.44	0.154
Right	8.33-18.50	15.13±1.41			
P	Width of pedicle (mm):	4.37-11.48	8.19±1.41	-	-
	Left	4.36-12.05	8.23±1.67	0.73	0.469
Right	3.42-10.91	8.15±1.43			
R	Pedicle sagittal angle (degree):	8.50-26.00	14.62±3.74	-	-
	Left	9.00-26.00	14.77±4.05	1.52	0.132
Right	8.00-26.00	14.47±3.74			
Ra	Dens sagittal angle (degree)	0.00-20.00	4.68±4.15	-	-

Table 4: Inter-correlation of linear and angular AXIS parameters of north Indian population, (n=200).

Variables	A	B	C	D	E	F	G	H	I	J	K	L	M	N	O	P	R	Ra	
A	1.00																		
B	0.64 ^{***}	1.00																	
C	0.28 ^{**}	0.37 ^{***}	1.00																
D	0.30 ^{***}	0.08 ^{ns}	0.40 ^{***}	1.00															
E	0.41 ^{***}	0.28 ^{**}	0.27 ^{**}	0.54 ^{***}	1.00														
F	0.05 ^{ns}	0.00 ^{ns}	0.14 ^{ns}	0.00 ^{ns}	-0.03 ^{ns}	1.00													
G	0.30 ^{***}	0.26 ^{**}	0.29 ^{**}	0.22 [*]	0.33 ^{***}	-0.03 ^{ns}	1.00												
H	0.09 ^{ns}	0.19 [*]	-0.04 ^{ns}	0.05 ^{ns}	0.05 ^{ns}	-0.04 ^{ns}	0.13 ^{ns}	1.00											
I	-0.07 ^{ns}	-0.18 [*]	0.18 [*]	0.27 ^{**}	0.11 ^{ns}	-0.09 ^{ns}	0.20 [*]	0.01 ^{ns}	1.00										
J	0.20 [*]	0.14 ^{ns}	0.18 [*]	0.27 ^{**}	0.17 ^{ns}	0.09 ^{ns}	0.11 ^{ns}	-0.02 ^{ns}	0.29 ^{**}	1.00									
K	0.06 ^{ns}	0.00 ^{ns}	-0.01 ^{ns}	0.04 ^{ns}	0.07 ^{ns}	0.13 ^{ns}	-0.04 ^{ns}	-0.05 ^{ns}	0.10 ^{ns}	0.69 ^{***}	1.00								
L	0.18 [*]	0.10 ^{ns}	0.18 [*]	0.32 ^{***}	0.19 [*]	0.05 ^{ns}	-0.03 ^{ns}	-0.19 [*]	0.27 ^{**}	0.47 ^{***}	0.41 ^{***}	1.00							
M	0.22 [*]	0.26 ^{**}	0.18 [*]	0.12 ^{ns}	0.17 ^{ns}	0.12 ^{ns}	0.07 ^{ns}	-0.05 ^{ns}	0.10 ^{ns}	0.29 ^{**}	0.32 ^{***}	0.76 ^{***}	1.00						
N	0.12 ^{ns}	0.11 ^{ns}	0.37 ^{***}	0.37 ^{***}	0.21 [*]	0.06 ^{ns}	0.29 ^{**}	0.10 ^{ns}	0.18 [*]	0.02 ^{ns}	-0.13 ^{ns}	0.15 ^{ns}	0.14 ^{ns}	1.00					
O	-0.06 ^{ns}	0.03 ^{ns}	-0.11 ^{ns}	0.02 ^{ns}	0.11 ^{ns}	0.00 ^{ns}	-0.02 ^{ns}	0.07 ^{ns}	-0.04 ^{ns}	0.08 ^{ns}	0.04 ^{ns}	0.10 ^{ns}	-0.11 ^{ns}	1					
P	0.21 [*]	0.03 ^{ns}	0.09 ^{ns}	0.30 ^{***}	0.40 ^{***}	-0.06 ^{ns}	0.46 ^{***}	0.16 ^{ns}	0.08 ^{ns}	0.08 ^{ns}	-0.09 ^{ns}	-0.16 ^{ns}	-0.19 [*]	0.23 [*]	0.22 [*]	1.00			
R	0.16 ^{ns}	-0.03 ^{ns}	0.11 ^{ns}	0.24 [*]	0.24 [*]	-0.11 ^{ns}	0.26 ^{**}	0.23 [*]	0.05 ^{ns}	0.18 [*]	0.14 ^{ns}	-0.10 ^{ns}	-0.06 ^{ns}	0.04 ^{ns}	-0.05 ^{ns}	0.26 [*]	1.00		
Ra	0.10 ^{ns}	-0.03 ^{ns}	0.11 ^{ns}	0.16 ^{ns}	0.28 ^{**}	-0.08 ^{ns}	0.16 ^{ns}	0.36 ^{***}	0.17 ^{ns}	0.30 ^{***}	0.28 ^{**}	0.04 ^{ns}	-0.02 ^{ns}	-0.02 ^{ns}	0.01 ^{ns}	0.14 ^{ns}	0.48 ^{***}	1	

ns- p>0.05, *- p<0.05, **- p<0.01, ***- p<0.001. Correlation was done by using Pearson correlation analysis. A: Width of dens, B: Height of dens, C: Height of anterior corpus, D: Distance from lateral edge of superior articular facet to midline, E: Distance from tip of transverse process to midline, F: Maximum length of inferior articular facet, G: Maximum width of inferior articular facet, H: Superior articular facet frontal angle, I: Pedicle horizontal angle, J: Maximum AP diameter of vertebral canal, K: Minimum AP diameter of vertebral canal, L: Maximum transverse diameter of vertebral canal, M: Minimum transverse diameter of vertebral canal, N: Maximum length of superior articular facet, O: Maximum width of superior articular facet, P: Width of pedicle, R: Pedicle sagittal angle, Ra: Dens sagittal angle

DISCUSSION

As surgical techniques and instrumentation for treatment of unstable cervical spine continue to evolve, more knowledge about bones and surrounding anatomy is required. The relationship between the vertebral artery and C1-C2 vertebrae has a determining role in planning an operative approach. Various techniques such as interlaminar clamp and hook plating, lateral screw and plate fixation, and interspinous wiring have been described for treating cervical instability. Transpedicular screw fixation is one of the most sophisticated procedures currently in use to treat atlas and axis instabilities. Recently, screw fixation has gained popularity for treating dens axis fractures. Use of transpedicular screws has been reported for treating spinal trauma, extensive laminectomies, and destruction of bony elements by neoplasm. Pedicle screws can cause injury to vertebral arteries under the superior facets of axis during insertion.

The rate of recognized vertebral artery injury was identified as 2% in Gupta and Goel's report, 4.1% in Wright and Laurysen's study, and 8% in Madawi et al's paper.^{7,20} However, the actual incidence of vertebral artery injury may be higher than those reported because of the low survey response and the possibility of unrecognized vertebral artery injury.

According to our study, the mean distance between both transverse processes of atlas of North Indian population was 71.34 mm which was closest to study in Gujrati population conducted by Patel et al (71.19) and statistically significant higher from South Indian Population (69.37 mm as concluded in the study performed by Gosavi) and lower than study by Sharma observed as 77 mm in Punjabi population.²¹ The mean distance between the outermost edges of the transverse foramens was 57.43 mm; the mean distance between the innermost edges of the transverse foramens was 48.24 mm. Lang found that the mean distance between the transverse processes was 78.2 mm; the mean distance between outermost edges of the transverse foramens was 64 mm, and the mean distance between the innermost edges of the transverse foramens was 52.3 mm.²²

In present study, the mean value for width of atlas was 71.19 ± 4.51 mm with a range from 59.6 to 79.34 mm. In previous studies Sengul and Kodiglu et al calculated as 74.6 mm, Gosavi calculated as 69.37 mm and Sharma T observed as 77 and 68 mm for male and female Punjabi population.^{21,22,24}

The mean distance between the outermost edges of the transverse foramens (OD) was 55.48 ± 3.83 mm with a range from 46.68 to 64.02 mm which is matched to the observation of Gosavi SN which was 55.66 ± 6.57 mm² However observation is differed from other authors observation. The mean distance between both medial-most edge of the transverse foramen (ID) was 44.77 ± 4.34 mm and matched with observation of Gosavi and Gupta

which was reported as 45.93mm and 45.2 mm, but it is unmatched with other's study reported as 48.6 mm by Sengul and Kodiglu and 52.3mm by Lang et al.²³

The transverse foramen through which the vertebral artery passes lies lateral to the transverse process of C1. Immediately behind the superior articular facet is a transverse groove for the vertebral artery. The articular process usually overhangs this groove anteriorly. There is often a bony bridge over the course of the vertebral artery. Ebraheim et al suggested that dissection of soft-tissue attachments on the posterior arch of C1 was limited to 8-12 mm.¹⁵ Anatomically, the bony groove on the superior surface of the posterior arch of C1 represents the exact location of the vertebral artery. Damage to the vertebral artery can be avoided if exposure of the posterior arch of C1 remains medial to the groove. The mean thickness of the vertebral artery groove on C1 was 5.05 mm in our study. This thickness is satisfactory for applying some fixation techniques such as clamp and hook plating, and atlantoaxial wiring. Thickness of the vertebral artery groove on the atlas was found by Ebraheim et al. to be 3-5 mm.¹⁵ Data obtained from the present study revealed that the range from the sagittal midline to the innermost edge of the vertebral artery was 11.83 mm for right side and 11.67 mm for left side. According to these data, we can say that dissection on the posterior arch of the C1 should be limited to 10 mm to prevent injury to the vertebral artery during dissection through a posterior approach.

The vertebral artery groove (VAG) on the superior surface of the posterior arch of atlas represents the exact location of the third part of the vertebral artery the thickness of the vertebral artery groove on atlas was 4.15 ± 1.28 mm with a range of 1.1 to 10mm on right side and 3.99 ± 0.98 mm with a range of 1.48 to 6.56 mm on left side. Whereas Ebraheim et al reported as 4.1 ± 1.2 mm, Sengul and Kodiglu as 5.05 mm and Gosavi observed as 3.72 ± 1.06 mm.^{15,21,22,24}

Ebraheim et al as 4.1 ± 1.2 mm. Senegul and Kodiglu explained that this thickness is sufficient for some fixation techniques such as clamp and hook plating and atlantoaxial wiring.^{2,14} Tan et al reported groove thickness of 4.65 mm in their study on manual and radiological measurements of fifty isolated atlases.⁸ In four of their cases (8%), the groove was less than 4 mm in thickness. In the present study, there were 65 cases in which the thickness was <4 mm.

The length of the inferior facet of C2 was slightly more than its width. In other words, the shape of the inferior facet of C2 was slightly oval. In present study, the maximum length of inferior articular facet of axis (12.35 mm) was more than the width (9.59 mm) suggesting oval shaped inferior articular facet while in the study by Gosavi in south Indian population these values were almost equal (9.8-9.9 mm) suggesting a circular facet.²¹

Cacciola et al reported that in 76% of the vertebrae studied, the superior articular facet was oval in shape and kidney

shaped in 24%.⁷ Senegul and Kodiglu observed oval superior articular facets in 72% and kidney shaped in 28%.² As noted above, our measurements were similar regarding facet shape. Lang found that facets were sometimes completely divided into a larger anterior and a smaller posterior section; we found a similar variation in the two facets of the vertebrae bilaterally.²²

The best safe mean angle of the inferior facet of C1 (especially for screw implantation) was 15.7 degrees (varied from 10-20) medial to the sagittal plane and mean of 15 degrees (varied from 10-20) superior to the axial plane which corresponded with Gupta and Goel, who stressed that the thickness of the inferior facet under the lateral aspect of the posterior arch was 10.65 mm, provided adequate space for insertion of the screw with little danger of injury to the vertebral artery at the C1-C2 level.²³ They advised that screws must be implanted from the middle of the posterior surface of the inferior facet and directed 15 degrees medial to the sagittal plane and 15 degrees superior to the axial plane.

Treatment of odontoid fractures, in which the fracture occurs across the base of the odontoid process at its junction with the corpus of axis, remains controversial. The most commonly used surgical treatment, either as initial therapy or when immobilisation fails, is a posterior fusion between the arches of the atlas and the axis, which might require an additional period of external immobilization. On the contrary, anterior screw fixation allows direct fixation across the fracture site and achieves immediate stability, while restoring and preserving normal movements of the cervical spine. In the present study, we observed that the mean widest diameter of dens axis on the coronal plane was 9.4 mm as compared to 9.28 mm in South Indian population (Gosavi) and 11 mm in Turkish population (Senegul).^{21,24} The distance from tip of dens axis to the anterior inferior edge of corpus axis was approximately 35 mm as compared to 35 mm in South Indian population and 36 mm in study by Senegul.²⁴

In the present study, the width of C2 pedicle ranged from 4.4 to 11.5 mm; with a mean width of 8.2 mm. Karaikovic et al measured isthmus height and width of C2 in 53 cadavers' axis vertebrae.²⁵ They found that approximately 92% of their 53 specimens had widths measuring more than 4 mm, and the heights were less than 5 mm in 12% of cases. Ebraheim et al.¹⁵ reported the superior pedicle width to range from 4-11 mm. Gupta and Goel reported that the mean screwable thickness of C2 pedicle was 7.8 mm, and that the mean height of the pedicle was 8 mm.²³ In the present study, the width of C2 pedicle ranged from 4.3 to 12.0 mm; and we suggest that placing a 3.5 mm screw in a patient with C2 isthmus dimensions (smaller than 5 mm in either the height or width) is technically difficult. In the presence of a small C2 isthmus width and/or height, approximately 10% of patients may be at risk for a vertebral artery injury with placement of C1- C2 transarticular screws.

A condition that increases the risk of vertebral artery injury in this region is due to the presence of two characteristics of the superior facet of C2 vertebra, which differs from the facets of all other vertebrae. Firstly, the superior facet of C2 presents proximity to the corpus and the medial aspect of pedicle axis when compared to other facets, which are located in proximity to the junction of pedicle and lamina. The second and more crucial characteristic is that the vertebral artery foramen is present partially or completely in the undersurface of superior facet of axis, while, in other cervical vertebrae, vertebral artery foramen is located entirely in relation to the transverse process. This unusual location of vertebral artery can deem the artery prone to injury if the screw is directed straight ahead anteriorly in a sagittal plane.

We found the mean pedicle sagittal angle to be 14.6 degrees; as compared to 21 degree in Turkish population. A relatively safe screw trajectory was found to be at 40 degrees medial to the sagittal plane and 20 degrees superior to the axial plane by Gupta and Goel.²³ Madawi et al reported a screw trajectory through C2 vertebra meaning that a safe screw trajectory ranges between 0 degrees in the parasagittal and 14 degrees medial in the horizontal plane.²⁰ In the present study the mean pedicle horizontal angle was found to be 16 degrees; and the mean pedicle sagittal angle to be 15 degrees.

During the study, a significant difference was observed in various morphometric measurements between North Indian and Turkish populations. Specifically, higher mean height of dens, distance from lateral edge of superior articular facet to midline, maximum length of inferior articular facet, and maximum width of superior articular facet were found significantly higher in North Indian populations compared to Turkish populations. On the other hand, lower measurements were observed in North Indian populations for all remaining factors compared to Turkish populations.

Additionally, when comparing North Indian and South Indian morphometric measurements, it was found that most mean linear measurements were significantly higher in North Indians except for transverse dimension of vertebral canal in the Atlas as well as width of dens body, height of anterior corpus, maximum width of inferior articular facet and diameter of vertebral canal.

CONCLUSION

It is therefore clear that significant ethnic variations exist between the morphometric parameters which need to be kept in mind by spine surgeons for planning and execution of reduction and instrumentation of C1 and C2. This study was able to shed light upon the parameters in North Indian population, offering significant new knowledge on the morphometric variables that can be used to pinpoint the C1 and C2 vertebrae's safe zones for instrumentation. During craniovertebral surgical procedures, the established safe zones and corresponding measurements are crucial for

strengthening instrumentation accuracy, maximizing operative strategies, and ultimately improving patient outcomes. This information can be used by spine surgeons to customize procedures and implant placements, leading to safer and more efficient treatments in the complex anatomical area of the craniovertebral junction. However, larger studies especially with virtual reconstruction and computer-generated analysis is required to construct a predictive model which will further improve the safety and ease of operative procedures in this region.

The strengths of the study lie in the fact that though there are multiple studies which have provided radiological measurements usually CT bases or Computer-generated virtual vertebrae based, there were very few studies providing actual osteological measurements especially in the Indian Population. As this study was conducted in four different government medical colleges in different geographic location of North India in reputed anatomy department with osteology museums, it covers the North Indian population more completely. This study also has one of the largest sample size in morphological study of C1 and C2 vertebrae. The study is limited by the fact that age, sex and ethnicity of the sample vertebrae are unknown. Hence, the application of the measurements in stratified groups is not completely applicable.

ACKNOWLEDGEMENTS

Authors would like to acknowledge and thank the department of anatomy of M. L. N. medical college, Allahabad; KGMC, Lucknow; GSVM medical college, Kanpur, and ACMS, Delhi; their HODs and faculty for facilitation of our research.

Funding: No funding sources

Conflict of interest: None declared

Ethical approval: The study was approved by the Institutional Ethics Committee

REFERENCES

1. Abou MA, Solanki G and Casey AT. Variation of the groove in the axis vertebra for vertebral artery: implication for instrumentation. J Bone Joint Surg Br. 1997;79(5):820-3.
2. An HS, Simpson JM. Spinal instrumentation of the cervical spine. In: Surgery of the Cervical Spine. London, Martin Dunitz. 1994;379-400.
3. Doherty BJ, Heggeness MH. The quantitative anatomy of the atlas. Spine. 1999;19(22):2497-500.
4. Brookes AL, Jenkins EB. Atlanto-axial arthrodesis by wedge compression method. J Bone Joint Surg Am. 1978;60(3):279-84.
5. Taitz C, Nathan H, Arensburg B. Anatomical observations of the foramina transversaria. J Neurol, Neurosurg Psychiatr. 1978;41(2):170-6.
6. Taitz C, Arensburg B. Vertebral artery tortuosity with concomitant erosion of the foramen of the transverse process of the axis. Possible clinical implications. Acta Anatomica. 1991;141(2):104-8.
7. Cacciola F, Phalke U, Goel A. Vertebral artery in relationship with C1-C2 vertebra: An anatomical study. Neurol India. 2004;52(2):178-84.
8. Cattrysse E, Provyn S, Gagey O, Kool P, Clarys JP, Roy PV. In vitro three dimensional morphometry of the lateral atlantoaxial articular surfaces. Spine. 2008;33(14):1503-8.
9. Cavalcanti DD, Agrawal A, Garcia-Gonzalez U, Crawford NR, Tavares PL, Theodore N et al. Anterolateral C1-C2 transarticular fixation for atlantoaxial arthrodesis: landmarks, working area, and angles of approach. Neurosurgery. 2010;67:38-42.
10. Cheung JP, Luk KD. Complications of anterior and posterior cervical spine surgery. Asian Spine J. 2016;10(2):385-400.
11. Cooper PR, Cohen A, Rosiello A. Posterior stabilization of cervical spine fractures and subluxations using plates and screws. Neurosurgery. 1988;23:300-6.
12. Dickman CA, Hurlbert RJ. Cannulated screws for odontoid And atlantoaxial transarticular screw fixation. In: Rengachary SS, Wilkins RH (eds). Neurosurgical Operative Atlas. Illinois: AANS, 1998;7:29-41.
13. Dugailly PM, Sobczak S, Sholukha V, Jan SV, Salvia P, Feipel V. In vitro 3D-kinematics of the upper cervical spine: helical axis and simulation for axial rotation and flexion extension. Surg Radiol Anat. 2010;32(2):141-51.
14. Ebraheim NA, Xu R, Lin D, Ahmad M, Heck BE. The quantitative anatomy of the vertebral artery groove of the atlas and its relation to the posterior atlantoaxial approach. Spine. 1998;23(3):320-3.
15. Ebraheim NA, Xu R, Lin D, Steve H, Yeasting RA. Quantitative anatomy of the transverse foramen and pedicle of the axis. J Spinal Disord. 1998;11(6):521-5.
16. Afsharpour S, Hoiriis KT, Fox RB, Demons S. An anatomical study of arcuate foramen and its clinical implications: a case report. Chiropr Man Therap. 2016;24:4.
17. Yew A, Lu D, Lu DC. CT-based morphometric analysis of C1 laminar dimensions: C1 translaminar screw fixation is a feasible technique for salvage of atlantoaxial fusions. Surg Neurol Int. 2015;6(4):S236-9.
18. Tsuji T, Chiba K, Horiuchi Y, Urabe T, Fujita S, Matsumoto M. Atlantoaxial Stabilization Using C1 and C2 Laminar Screw Fixation. Asian Spine J. 2017;11:314-8.
19. Cacciola F, Phalke U, Goel A. Vertebral artery in relationship to C1-C2 vertebrae: an anatomical study. Neurology. 2004;2:178-84.
20. Madawi AA, Case ATH, Solanki GA, Tuite G, Veres R, Crockard HA. Radiological and anatomical evaluation of the atlantoaxial transarticular screw fixation technique. J Neurosurg. 1997;86:961-8.

21. Shilpa Gosavi, Vatsala Swamy. Morphometric study of the Axis vertebra. *Eur J Anat.* 2012;16(2):98-103.
22. Lang J. *Skull Base and Related Structures.* 1st ed. Stuttgart: Schattauer. 1995;292.
23. Gupta S, Goel A. Quantitative anatomy of the lateral masses of the atlas and axis vertebrae. *Neurol India.* 2000;48(2):120-5.
24. Sengul G, Kodiglu HH. Morphometric anatomy of atlas and axis vertebra. *Turkish Neurosurg.* 2006;16(2):69-76.
25. Karaikovic EE, Daubs MD, Madsen RW. Morphologic characteristics of human cervical pedicles. *Spine.* 1997;22(5):493-500.

Cite this article as: Gogia T, Dasgupta T, Goel N, Singh N, Rajan A, Das M, et al. Osteological morphometric analysis of instrumentation safe zones of C1 and C2 vertebra in North Indian population: a multicentric study. *Int J Res Orthop* 2023;9:1148-59.