

## Original Research Article

# An anthropometric study of intercondylar femur notch with MRI analysis

Aditya Patidar, Harshul Arora\*, Jay Kumar Sharma, Sarvagya Jain

Department of Orthopaedics, RD Gardi Medical College, Ujjain, Madhya Pradesh, India

**Received:** 18 August 2023

**Revised:** 02 October 2023

**Accepted:** 08 October 2023

**\*Correspondence:**

Dr. Harshul Arora,

E-mail: [harshularora40@gmail.com](mailto:harshularora40@gmail.com)

**Copyright:** © the author(s), publisher and licensee Medip Academy. This is an open-access article distributed under the terms of the Creative Commons Attribution Non-Commercial License, which permits unrestricted non-commercial use, distribution, and reproduction in any medium, provided the original work is properly cited.

### ABSTRACT

**Background:** Anterior cruciate ligament is the most common ligament injury of knee. The bony anatomy of femur and tibia is responsible for normal knee kinematics and static stability. Intercondylar notch dimensions is considered as a significant predictive risk factor for ACL tear. Narrow femoral intercondylar notch width in either sex were major correlating factors. Aim was to evaluate the intercondylar femur notch dimensions in patients of knee injury using magnetic resonance imaging at RD Gardi Medical College, Ujjain, Madhya Pradesh.

**Methods:** This is a prospective study consist of 400 patients carried out from October 2020 to August 2022 in the Department of Orthopaedics, RDGMC Ujjain. All the patients of knee injury including ACL tear and age 18 years to 60 years are included in the study. Patient less than 18 years and more than 60 years were excluded from the study. Dicom radiant software is used as statistical tool to analyse the data. Various intercondylar notch dimensions in different sections are measured using MRI in the dicom software.

**Results:** The cut off values of axial NWI, NSI, NDI as 0.238, 0.662, 0.472 respectively.

**Conclusions:** We conclude that narrow femoral intercondylar notch, lower notch width index increases the risk of an ACL tear in the given population. This would help in identification of people at risk for ACL injuries. Our study provides a comprehensive analysis on the risk factor of ACL tear, which would help in betterment of the patients at danger for anterior cruciate ligament injury. People with decreased notch dimensions should be educated on the high risk of ACL tear and be given proper prophylactic precautions.

**Keywords:** Anterior cruciate ligament, Intercondylar notch, Notch width index, Notch shape index, Notch depth index, Notch angle, Roof angle

### INTRODUCTION

The Anterior cruciate ligament (ACL) is the most frequently injured ligament of the knee joint and is a serious knee injury.<sup>1</sup> An increased risk of ligament tears is linked to the femur variable morphology.

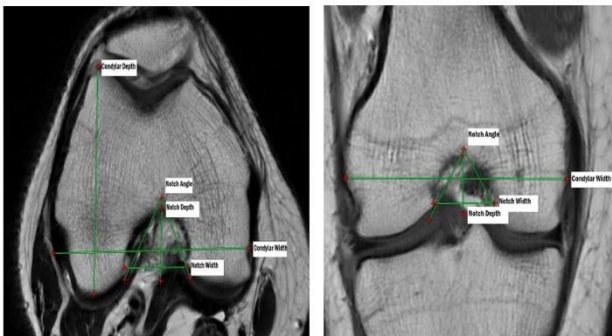
The size of the intercondylar notch is regarded as a major risk factor for ACL damage.<sup>2,3</sup> Increased engagement in sports activities is to blame for the recent rise in the frequency of ligament injuries in and around the knee

joint.<sup>4,5</sup> Initially, it was thought that a traumatic mechanism involving rotation, hyperextension or contraction of the quadriceps muscle was the cause of ACL rupture.<sup>6</sup> However, some research demonstrates a morphological propensity and some authors have assessed the size of the intercondylar femur notch. They had demonstrated that patients with a high propensity for ACL tears in which the femoral intercondylar notch is narrow.<sup>7,8</sup> Women overall and narrow femoral intercondylar notch width in either sex were key correlated factors to ligament injury, according to epidemiological studies.<sup>9</sup> Thin and

weak ACLs are known to be correlated with smaller femoral notches.<sup>10,11</sup> The stenotic notch causes the ACL to impinge onto the lateral femoral condyle, where it is subjected to anterior shear forces or tibial rotation that might lead to ACL rupture.<sup>12,13</sup> Notch angle (NA), Notch width index (NWI), Notch shape index (NSI), Notch depth index (NDI) and Roof angle are some of the various characteristics used to demonstrate the relationships. Individual differences in the anatomy of the knee joint may make ligament damage more likely. Increased awareness of the propensity for these injuries is encouraged by knowledge of the femur and tibia bony architecture. The majority of recent studies concentrate on the intercondylar femur notch width index. The relationship between the risk of ACL tears and the intercondylar femur notch angle, notch shape index, and morphology of the same is poorly understood. The goal of this study is to assess the intercondylar femoral notch using Magnetic resonance imaging (MRI) in individual with known knee injury due to the potential relationship between the femoral intercondylar notch morphology and ACL injury.

## METHODS

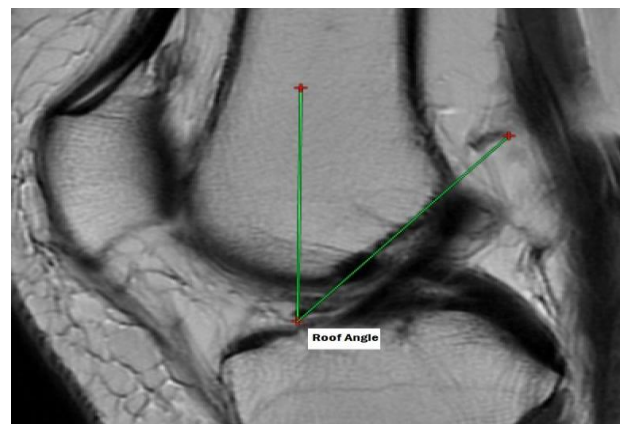
This is a prospective study carried out in the Department of Orthopaedics, RDGMC Ujjain from October 2020 to August 2022. All the patients of knee injury including ACL tear and age 18 years to 60 years are included in the study. Patient less than 18 years and more than 60 years were excluded from the study. Dicom radiant software is used as statistical tool to analyse the data. Various intercondylar notch dimensions in different sections are measured using MRI in the dicom software.



**Figure 1: Measurement of the femoral notch dimensions in axial image and coronal image. The notch depth is perpendicular to a line tangent to the posterior condyles. The notch width and the condylar width are parallel to that line at 2/3 of the notch depth. Condylar depth is the maximum depth of lateral condyle in axial image. Notch angle is formed between the apex of the notch and the inferior aspect of the base of notch.**

A total of 400 knee magnetic resonance imaging series were included in the study. The study aims to evaluate the intercondylar femur notch dimensions in patients of knee injury and its correlation with ACL injury. The MR images

were collected after determining knee injury to the patient. MR imaging was performed employing 3 T scanner with proton density fat suppression, coronal plane, 3.5 mm slice thickness, 1 mm space, matrix of 360\*360, 41.3 m s echo time and repetition time of 2438m s. Sagittal images 3.5 mm slice thickness, 0.5 mm space, matrix of 360\*360, 37.2 m s echo time and repetition time of 2465 m s and axial images, thickness of 3.5 mm, space of 1 mm, matrix of 380\*380, echo time of 46.1 m s, repetition time of 2644 m s with the knees in near normal extension. Axial, sagittal and coronal images were obtained for all examined knee MR images. The axial and coronal MR image slice that contained the popliteal groove was used to calculate the femoral notch parameters. The posterior condylar reference line is drawn tangent to the lowermost points of medial and lateral condyles first.



**Figure 2: Sagittal T2W image showing the intercondylar roof angle formed between the Femoral axis and the Bluemensaat line.**

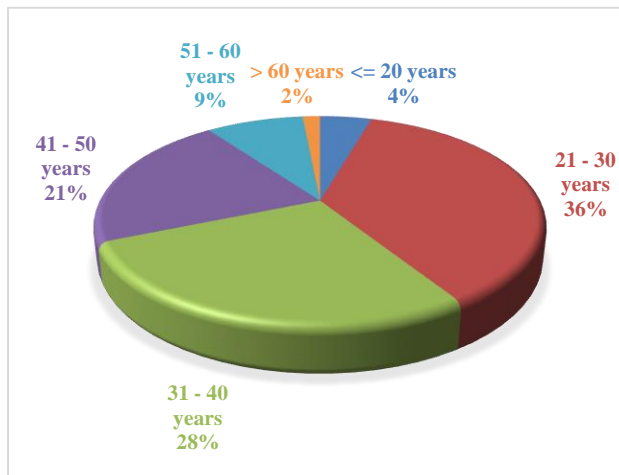
The inter-condylar depth is defined as the distance at right angle from the bicondylar reference line to the top of the intercondylar notch. Intercondylar width is measured at two thirds of the intercondylar depth. The widths of the medial and lateral condyles are measured at the same level. The sum of the inter-condylar width, the medial condylar width, and the lateral condylar width provided the condylar width. The angle between the most inferior aspects of the notch at the medial and lateral condyles and the top of the intercondylar notch was the intercondylar angle. This method has shown adequate reproducibility<sup>15</sup>. The NWI is defined as the ratio between the intercondylar notch width and the femoral condylar width. The ratio between the notch width and the notch depth gives the NSI (notch shape index). The NDI (notch depth index) is the ratio between the notch depth and the depth of the lateral condyle in axial image. The T2W images were used to calculate the above parameters. Roof angle is calculated on the sagittal MRI slice where the line is visible. The femoral axis is obtained by joining the centre of the circles drawn along the shaft. The angle between the blumensaat line and the femoral axis provides the Roof angle. Magnetic resonance imaging series were included in the study.

**RESULTS**

We have studied 400 patients with knee problems, mean age of the cases was 34.28±10.99 years. Majority of cases 222 (55.5%) were female and 178 (44.5%) cases were male (Table 1).

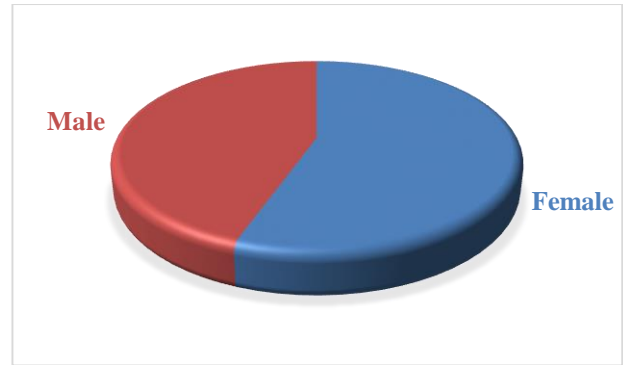
**Table 1: Comparison of the intercondylar femur notch parameters in axial, coronal and sagittal images (n=400).**

Variables	Subjects			P value
	Mean	Males (N=178)	Females (N=222)	
<b>Axial</b>				
Notch width index	0.248	0.248	0.247	>0.05
Notch shape index	0.719	0.703	0.732	<0.05
Notch depth index	0.512	0.520	0.506	>0.05
Notch angle	51.35	51.67	51.09	<0.05
<b>Coronal</b>				
Notch width index	0.229	0.230	0.228	>0.05
Notch shape index	0.778	0.778	0.778	>0.05
Notch angle	59.82	60.23	59.50	>0.05
<b>Sagittal</b>				
Roof angle	38.99	38.89	39.06	>0.05



**Figure 3: Age based distribution.**

In the axial images the mean NWI was 0.248 with no significant difference in males and females. The mean NSI was 0.719, and males had smaller NSI as compared to females. NA averaged with 51.35 degree. The mean NDI was 0.512, with females had smaller NDI as compared to males. In the coronal knee MRI images, the mean NWI, NSI and NA was 0.229, 0.778 and 59.82 degree with no significant difference in males and females. In sagittal images, the roof angle averaged 38.99 degree with no significant difference in males and females.



**Figure 4: Gender based distribution.**

**DISCUSSION**

The ACL is a crucial element in stabilizing the knee joint. The number of patients of ACL tear has been increased due to more involvement in sports activities. Consequently, identification of the factors associated with an increased risk of having an ACL tear is important. Some studies have shown that morphology of the femur intercondylar notch is one of the major parameters that predisposes to an ACL tear. In our study on 400 patients, significant association was found between age group and ACL injury with p<0.05. Majority of the cases with ACL injury were belongs to 21-30 years age group are 72 (49.3%), 48 (43.2%) cases in 31-40 years of age group, 12 (66.7%) cases in less than 20 years of age group, 20 (58.8%) cases in 51-60 years of age group, 10 (11.8%) cases in 41-50 years of age group and 5 (83.3%) case in more than 60 years of age group. Male cases 85 (47.8%) had significantly higher ACL injury as compare to female cases 82 (36.9%). The dimensions of the femoral notch are typically defined in terms of NWI (Notch width index). Thin and weak ACL are known to be correlated with smaller femoral notch.<sup>10,11</sup> This assumption is challenged by certain investigations. It is challenging to compare results because the site of measurement on the distal femur varied across the literature. In our study the cut off value for NWI in axial images was 0.238 for predicting ACL injury. Souryal et al depicted NWI on Xray and the cut off value in their study was 0.231.<sup>14</sup> The cut off value for NWI on Xray in investigation done by Uhorhak et al was 0.26.<sup>15</sup> Investigated intercondylar femur notch parameters on MRI and concluded the mean value for NWI as 0.266.<sup>16</sup> Alentron-Geli et al concluded the cut off value for NWI (MRI) in axial and coronal images as 0.25 and 0.24 respectively.<sup>17</sup> Balgovind et al in their study done on south population of India and concluded the cut off value for NWI (MRI) as 0.258 in axial images, 0.254 in coronal images.<sup>18</sup> In our study the cut off values of NSI and NDI were 0.662 and 0.472 for discriminating ACL injuries. In previous studies, Wada et al discovered the NDI (MRI) cut off value as 0.55.<sup>19</sup> Anderson et al concluded the Notch angle parameter on CT as 54.7.<sup>20</sup> Alentron-Geli et al in their study depicted the mean value for Notch angle (MRI) as axial and coronal images as 50.1 and 60.3 respectively.<sup>21</sup> Scheffel et al concluded the cut off value

for Roof angle in X-ray as 34.7.<sup>22</sup> Vaswani et al in their study found the cut off value for Notch base width in MRI as 16.5.<sup>23</sup> Sheik et al concluded the cut off value for NWI in MRI as 0.29. To further study the notch morphology in Indian population, our study findings can be used as a reference in future.

The first to propose that a shallow intercondylar notch may enhance the risk of ACL injury was Palmer et al.<sup>24</sup> Souryal et al who created the idea of NWI as a means of predicting the likelihood of ACL damage in 1998, backed up this assertion.<sup>14</sup> Anderson et al reported that anterior outlet notch stenosis increases the likelihood of ACL damage.<sup>20</sup> determined via CT that a small posterior notch may predispose a person to ACL injury.<sup>25</sup> LaPrade and Burnett found that athletes with a stenotic notch were significantly more likely to experience an ACL rupture after conducting a two-year prospective analysis.<sup>26</sup> The assumption that the intercondylar notch's size and the ACL size are correlated led to the postulated association between the risk of ACL injury and a small intercondylar notch. New information, however casts doubt on this theory. In knees with a NWI larger than 0.20 and less than 0.20, Muneta et al discovered no difference in ligament size.<sup>10</sup> Clinically, Herzog et al reported no significant variations in the radiograph and MRI measurements of the notch in athletes with chronic ACL rupture compared to the control group.<sup>27</sup> Shickendantz and Weiker discovered no changes between the groups when they compared participants with unilateral ACL damage, bilateral ACL injury, and non injured subjects.<sup>28</sup> They came to the conclusion that intercondylar notch measures should not be used to forecast the likelihood of ACL injury. Additionally, Lombardo et al. did not discover a link between NWI and the frequency of ACL injuries in professional male basketball players.<sup>29</sup>

We detect substantial differences in the mean NWI and NSI in patients with and without an ACL tear, male and female patients separately, taking into account the relationship between NWI and the rate of ACL damage. A summary of literature depicting the intercondylar notch morphology is depicted in (Table 1). However, it is important to be cautious when interpreting our findings. A prospective study's findings would be more dependable than that study's cross-sectional design. We looked at those who had knee issues, which could have biased our study. We think that these characteristics are not crucial because there is no evidence linking NWI to any other knee issues besides osteoarthritis. Another drawback of our study was that it did not just include athletes. Also, the inclusion of alternative ACL damage causes, such as direct trauma, may mitigate the impact of narrow NWI in ACL injury. Our study is done on Indian population. Though ethnicity affects the geometry of knee and the distal femoral intercondylar notch morphology, the same variables should apply to them. Apart from the anatomical risk factors there are other several variables like hormonal, cognitive function, genetic, gender, weight and activity status. These factors were not ruled out in this study.

## CONCLUSION

The present study aimed to compare the femoral notch morphological variables in patients of knee injury. We conclude that narrow femoral intercondylar notch, lower notch width index increases the risk of an ACL tear in the given population. The cut off values of axial NWI, NSI, NDI as 0.238, 0.662, 0.472 respectively. This would help in identification of people at risk for ACL injuries. Our study provides a comprehensive analysis on the risk factor of ACL tear, which would help in betterment of the patients at danger for anterior cruciate ligament injury. People with decreased notch dimensions should be educated on the high risk of ACL tear and be given proper prophylactic precautions. This study provide a future reference to further studies on assessment of femur intercondylar notch dimensions as a risk factor for ACL tear.

*Funding: No funding sources*

*Conflict of interest: None declared*

*Ethical approval: The study was approved by the Institutional Ethics Committee*

## REFERENCES

1. Dragoo JL, Braun HJ, Durham JL, Chen MR, Harris AH. Incidence and risk factors for injuries to the anterior cruciate ligament in National Collegiate Athletic association football: data from the 2004-2005 through 2008-2009 National Collegiate Athletic association injury surveillance system. *Am J Sports Med.* 2012;40:990.
2. Shelbourne KD, Davis TJ, Klootwyk TE. The relationship between intercondylar notch width of the femur and the incidence of anterior cruciate ligament tears. A prospective study. *Am J Sports Med.* 1998; 26(3):402.
3. Feucht MJ, Mauro CS, Brucker PU, Imhoff AB, Hinterwimmer S. The role of the tibial slope in sustaining and treating anterior cruciate ligament injuries. *Knee Surgery Sports Traumatol Arthrosc.* 2013;21:134.
4. Boden BP, Dean GS, Feagin JA, et al. Mechanisms of anterior cruciate ligament injury. *Orthoped.* 2000;23: 573.
5. Feagin Jr JA, Lambert KL. Mechanism of injury and pathology of anterior cruciate ligament injuries. *Orthop Clin N Am.* 1985;16(1):41.
6. Chambat P, Guier C, Sonnery-Cottet B, Fayard JM, Thauinat M. The evolution of ACL reconstruction over the last fifty years. *Int Orthop.* 2013;37:181-6.
7. Dienst M, Schneider G, Altmeyer K, et al. Correlation of intercondylar notch cross sections to the ACL size: a high resolution MR tomographic in vivo analysis. *Arch Orthopedics Trauma Surg.* 2007;127:253-60.
8. Fu FH, Musahl V. *Anatomic ACL reconstruction.* Preface. *Clin Sports Med.* 2013;32.
9. Canale ST, Beaty JH, Campbell WC, Daugherty K, Burns B. *Campbell's Operative Orthopedics: Get Full*

- Access and More at ExpertConsult.Com. 12. internet. Philadelphia: Elsevier; 2013.
10. Muneta T, Takakuda K, Yamamoto H. Intercondylar notch width and its relation to the configuration and cross-sectional Area of the anterior cruciate ligament: a cadaveric knee study. *Am J Sports Med.* 1997; 25(1):69.
  11. Olsen O-E, Myklebust G, Engebretsen L, Bahr R. Injury mechanisms for anterior cruciate ligament injuries in team handball: a systematic video analysis. *Am J Sports Med.* 2004;32(4):1002.
  12. Kennedy JC, Weinberg HW, Wilson AS. The anatomy and function of the anterior cruciate ligament. As determined by clinical and morphological studies. *J Bone Joint Surgery Am.* 1974;56(2):223.
  13. Stijak L, Nikolic V, Malis M, Maksimovic R, Aksic M, Filipovic B. The influence of the morphometric parameters of the intercondylar notch on rupture of the anterior cruciate ligament. *Vojnosanit Pregl.* 2012; 69(7):576.
  14. Souryal TO, Freeman TR. Intercondylar notch size in anterior cruciate ligament injuries in athletes. A prospective study. *Am J Sports Med.* 1993;21:535.
  15. Uhorchak JM, Scoville CR, Williams GN, Arciero RA, St Pierre P, Taylor DC. Risk factors associated with noncontact injury of the anterior cruciate ligament: a prospective four-year evaluation of 859 West Point cadets. *Am J Sports Med.* 2003;31:831.
  16. Hoteya K, Kato Y, Motojima S. Association between intercondylar notch narrowing and bilateral anterior cruciate ligament injuries in athletes. *Arch Orthop Trauma Surg.* 2011;131:371.
  17. Alentorn-Geli E, Xavier P. An evaluation of the association between radiographic intercondylar notch narrowing and anterior cruciate ligament injury in men: the notch angle is a better parameter than notch width. *J Arthroscop Related Surg.* 2015;31:2004.
  18. Balgovind SR, Raunak B, Anusree A. Intercondylar notch morphometrics in Indian population: An anthropometric study with magnetic resonance imaging analysis. *J Clin Orthopaed Trauma.* 2019; 10(4):702-5.
  19. Wada M, Tatsuo H, Baba H, Asamoto K, Nojyo Y. Femoral intercondylar notch measurements in osteoarthritic knees. *Rheumatology.* 1999;38(6):554.
  20. Anderson AF, Lipscomb AB, Liudahl KJ. Analysis of the intercondylar notch by computed tomography. *Am J Sports Med.* 1987;15:547.
  21. Xavier P. An evaluation of the association between radiographic intercondylar notch narrowing and anterior cruciate ligament injury in men: the notch angle is a better parameter than notch width. *J Arthroscop Related Surg.* 2015;31:2004.
  22. Scheffel PT, Henninger HB, Burks RT. Relationship of the intercondylar roof and the tibial footprint of the ACL: implications for ACL reconstruction. *Am J Sports Med.* 2013;41(2):396e401.
  23. Vaswani R, Meredith SJ, Lian J, Li R, Nickoli M, Fu FH, Musahl V. Intercondylar notch size can be predicted on preoperative magnetic resonance imaging. *Arthroscopy, sports medicine, and rehabilitation.* 2020;2(1):e17-22.
  24. Palmer I. On the injuries to the ligaments of the knee joint: a clinical study. 1938. *Clin Orthop Relat Res.* 2007;454:17-22.
  25. Houseworth SW, Mauro VJ, Mellon BA, Kieffer DA. The intercondylar notch in acute tears of the anterior cruciate ligament: a computer graphics study. *Am J Sports Med.* 1987;15(3):221-4.
  26. La Prade RF, Burnett QM. Femoral intercondylar notch stenosis and correlation to anterior cruciate ligament injuries: a prospective study. *Am J Sports Med.* 1994;22:198.
  27. Herzog RJ, Silliman JF, Hutton K, Rodkey WG, Steadman JR. Measurements of the intercondylar notch by plain film radiography and magnetic resonance imaging. *Am J Sports Med.* 1994;22:204-10.
  28. Schickendantz MS, Weiker GG. The predictive value of radiographs in the evaluation of unilateral and bilateral anterior cruciate ligament injuries. *Am J Sports Med.* 1993;21(1):110-3.
  29. Lipscomb AB, Johnston RK, Snyder RB. Evaluation of hamstring strength following use of semitendinosus and gracilis tendons to reconstruct the anterior cruciate ligament. *Am J Sports Med.* 1982;10:340-42.

**Cite this article as:** Patidar A, Arora H, Sharma JK, Jain S. An anthropometric study of intercondylar femur notch with MRI analysis. *Int J Res Orthop* 2023;9:1207-11.