

## Case Series

# Management of patella fracture with percutaneous wiring

M. B. Lingayat, Nilesh I. Kachnerkar\*, Prashant R. Bansode,  
Sufyan M. Muslim, Omkar Rashinkar

Department of Orthopaedics, Government Medical College, Aurangabad, Maharashtra, India

**Received:** 31 July 2023

**Revised:** 08 August 2023

**Accepted:** 17 August 2023

**\*Correspondence:**

Dr. Nilesh I. Kachnerkar,

E-mail: [bansodeprashant48@gmail.com](mailto:bansodeprashant48@gmail.com)

**Copyright:** © the author(s), publisher and licensee Medip Academy. This is an open-access article distributed under the terms of the Creative Commons Attribution Non-Commercial License, which permits unrestricted non-commercial use, distribution, and reproduction in any medium, provided the original work is properly cited.

### ABSTRACT

Patella fractures are fixed traditionally in orthopaedics by open reduction and internal fixation as it is an intra-articular fracture. Open operative techniques are associated with high incidence of infections, cosmetic problems, and delayed rehabilitation. Percutaneous, arthroscopic techniques have fewer complications but these are technically demanding procedures to master. Percutaneous wiring of patella being a newer technique, in our study of 25 patients we evaluated its results over other conventional methods of treatment of patella fracture. The patients were followed up for 30 months and its results were studied.

**Keywords:** Patella fractures, Minimally invasive, Percutaneous encercage wiring, Early rehabilitation

### INTRODUCTION

Patella is very important bone as it forms the patellofemoral joint and plays part in extensor mechanism of knee joint. So the management of the fracture patella has been constantly reviewed by many authors. Various treatment options advocated in comminuted fracture are excision of fragments, open reduction and internal fixation by tension band wires or cerclage wires, compression with screws and others. Open reduction and fixation is associated with relatively higher incidence of complications. Percutaneous encercage wiring is a newer minimally invasive technique particularly of useful in comminuted patella fractures where fixation and anatomic reduction of fracture is very difficult to achieve.<sup>1</sup> In our research article we study results of closed reduction and internal fixation with percutaneous encercage wires.

### CASE SERIES

Management of patella fracture with percutaneous wiring study was conducted at Government Medical College Aurangabad from May 2019 to May 2022 on 25 patients and results evaluated. We use percutaneous encercage

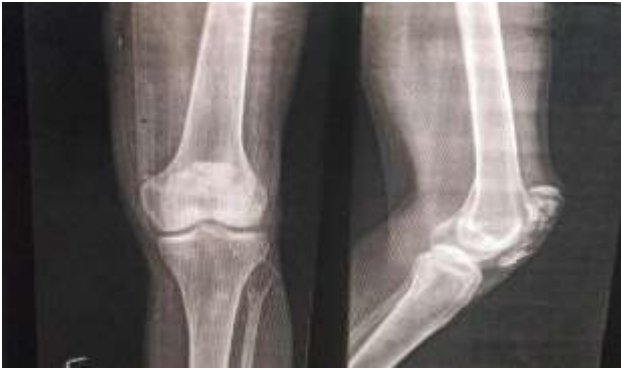wiring as the procedure under c-arm control. Inpatients were evaluated for mode of trauma, side of limb affected, closed or open fractures and associated injuries. Antero-posterior and lateral X-rays of the affected knee joint were taken. Comminuted fractures, transverse fractures and lower pole fractures were selected for the study. Primary treatment included hemarthrosis aspiration and Robert Jones compression bandage and above knee slab and limb elevation. Anaesthetic fitness was done and all patients received I.V. antibiotics one hour prior to surgery.

#### Case 1

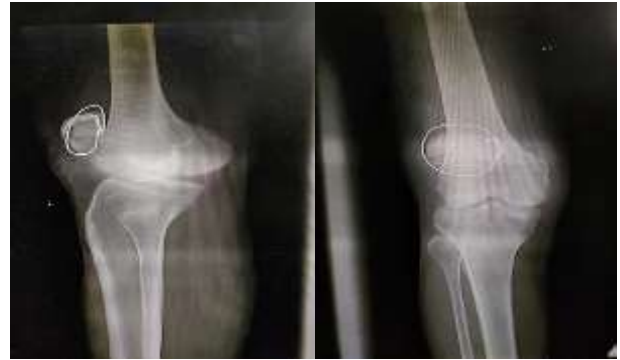35-year-old male patient with history of road traffic accident, with direct fall on right knee resulting in comminuted patella fracture with no other injuries, fixed with percutaneous fixation using SS wire (Figures 1-3).

#### Case 2

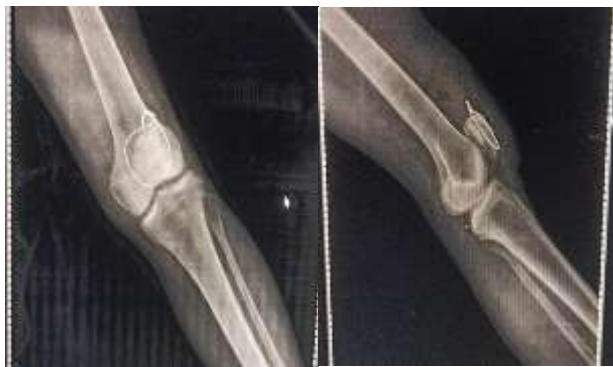37-year-old female patient with history of direct fall on left knee after fall in bathroom, resulting in transverse patella fracture fixed with SS wire (Figures 4 and 5).



**Figure 1: Preoperative X ray of comminuted patella fracture.**



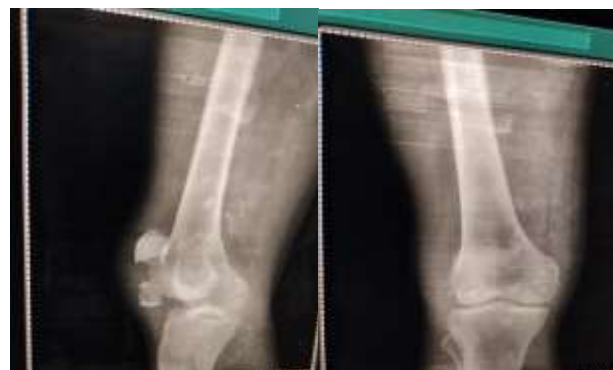**Figure 5: Postoperative X-ray with encircage.**



**Figure 2: Postoperative X-ray encircage.**



**Figure 3: Postoperative range of movement.**



**Figure 4: Pre-operative X-rays.**

### ***Surgical operative technique***

Patient was operated in spinal anaesthesia in supine position. All aseptic precautions were followed and limb was prepared from mid-thigh to mid leg. Small 1 cm incision was taken on knee on superolateral side of patella. Dental wire no. 18 was introduced and was threaded through quadriceps tendon with the help of cannula or dental wire passer to medial side. Medial end of wire was taken out through small superomedial incision. In a similar way the dental wire was passed through tissues of medial side of patella and then through patellar ligament and then through tissues along lateral border to take end of dental wire out through incision on superolateral side. Both the ends of dental wire were pulled and twisted over each other and tightened. In this way reduction was achieved and checked under image intensifier. Excess dental wire was cut and wire buried so that it is not prominent. Incision was sutured in single layer, compression dressing done and a long posterior slab applied.

### ***Post-operative care***

Broad spectrum antibiotics, NSAIDS and antacids were given for 48 hours. Suture and slab was removed after 3 weeks. Follow up was done at 3 weeks interval to see the range of movements and any other complains. Antero-posterior and lateral X-rays were found out.

### ***Assessment of results***

Results were grouped as excellent, good, fair and poor based on objective and subjective criteria as follows:

Objective assessment was done on following points- ROM of knee joint, quadriceps power, and wasting of quadriceps in cm. Subjective assessment- patient general feeling, pain, ability to get out of chair, ability to climb stairs, and ability to squat.

The majority age of patients was between 20-50 years (19-64 years). The majority of patients were male 88% (22 out of 25). The mode of injury was mainly road traffic accidents 68% cases. 96% of patients arrived to hospital within 48 hours of trauma. In our study 80% patients had

closed fractures and 86% of patients included had comminuted fractures. Associated injuries present in 32% patient. The mean operating time was 20 (range, 15-40) minutes. Majority had hospital stay for 3 days other than with associated injuries. 32% fractures united in 6 weeks, 40% fractures united in 7 weeks and 24% fractures united in 8 weeks.

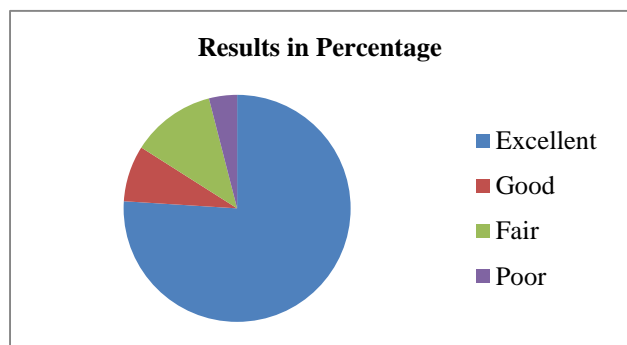


Figure 6: Results.

Table 1: Complications.

Complication	No. of cases	Percentage
Painful knee	-	-
Infection	1	4.00
Extension lag	1	4.00
Nonunion	1	4.00
Breaking of wire	1	4.00
Stiffness	--	--
Total	4	16.00

## DISCUSSION

Percutaneous cerclage wiring for patella fracture is indeed a minimally invasive approach that offers several advantages.<sup>1</sup> This technique involves the use of small skin incisions without dissecting the fractured region and surrounding soft tissues. By doing so, it minimizes trauma to the tissues and allows for a quicker recovery compared to traditional open surgery.

Comminuted fractures involve the fragmentation of the patella into multiple pieces, making the application of the classic tension band wiring technique challenging. However, the percutaneous cerclage wiring method can be a suitable alternative in such cases, providing favourable bone union and promoting successful fracture healing.

One of the benefits of percutaneous cerclage wiring is that it enables early range-of-motion training after surgery. Because the soft tissues are included in the wire fixation, there is less concern about disrupting the fracture site during rehabilitation exercises. Patients started continuous passive motion (CPM) just after 3 weeks, which aids in maintaining joint mobility and preventing stiffness.

Torchia et al in 1996 had reported road traffic accident as mode of trauma in 90% cases.<sup>9</sup> In present series 68% were due to road traffic accident and 24% due to domestic fall.

Pizzarro et al in 2006 in their studies found that percutaneous osteosynthesis required short surgical time. In present study duration of surgery was short, less than 30 minutes and it was easy to perform, technically less demanding.<sup>10</sup>

Bostrom et al advocated full weight bearing with crutches, quadriceps exercise with straight leg raising within few days of intervention. In present series, patient was encouraged to perform static quadriceps exercises within limits of pain in early post-operative period. Following removal of cylinder cast active physiotherapy given in form of guarded knee bending, straight leg raising, simple resisted exercise.<sup>11</sup>

Yannis et al in 2006 had reported average union time of operated fracture patella of 6 weeks. In present study average period of union was 7 weeks.<sup>12</sup>

Torchia et al in 1996 in retrospective analysis of 57 operated cases of compound fracture patella reported excellent results in 17%, good in 60%, fair in 17%, poor in 6%. In present series, out of 25 cases excellent results obtained in 76%, good in 8%, fair in 12%, poor in 4%.<sup>9</sup>

Pailo et al in 2005 in their series had found infection rate of 6.8%. Schwartz et al in 2006 in their series found infection rate of 2-10%, loss of reduction in 20% hardware prominences in 5% cases. In present series, Complications occurred in 4 out 25 patients that were infection in 1 case and extension lag in 1 case. Breaking of wire in 1 case where it was due to infection in which implant was removed. Non-union was seen in 1 case which was later operated with tension band wiring.<sup>13</sup>

## CONCLUSION

Percutaneous wiring of fracture patella is a demanding procedure to master compared to the traditionally performed open reduction and internal fixation. Despite these facts percutaneous encirclage wiring is a minimally invasive procedure, it reduces operative time, reduces hospital stay, it has less overall infection rate and it is cosmetic.

*Funding: No funding sources*

*Conflict of interest: None declared*

*Ethical approval: Not required*

## REFERENCES

1. Biyani A, Mathur NC, Sharma JC. Percutaneous tension band wiring for minimally displaced fractures of the patella. Int Orthop. 1990;14:281-3.
2. Melvin SJ, Mehta S. Patellar fractures in adults. J Am Acad Orthop Surg. 2011;19(4):198-207.

3. Yang L, Yueping O, Wen Y. Management of displaced comminuted patellar fracture with titanium cable cerclage. *The Knee.* 2010;17(4):283-6.
4. Wu CC, Tai CL, Chen WJ. Patellar tension band wiring: a revised technique. *Arch Orthop Trauma Surg.* 2001;121:12-6.
5. Wardak MI, Siawash AR, Hayda R. Fixation of patella fractures with a minimally invasive tensioned wire method: compressive external fixation. *J Trauma Acute Care Surg.* 2012;72(5):1393-8.
6. Wajid MA, Cheema MQ, Siddique MS. Vertical axis patellar dislocation with ipsilateral femoral fracture: use of a closed percutaneous technique for reduction of the dislocation. *J Orthop Trauma.* 2006;20(2):143-6.
7. Boström Å. Fracture of the patella: a study of 422 patellar fractures. *Acta Orthopaedica Scandinavica.* 1972;43(43):1-80.
8. Cho JH. Percutaneous cannulated screws with tension band wiring technique in patella fractures. *Knee Surg Relat Res.* 2013;25(4):215.
9. Torchia ME, Lewallen DG. Open fractures of the patella. *J Orthop Trauma.* 1996;10(6):403-9.
10. Luna-Pizarro D, Amato D, Arellano F, Hernández A, López-Rojas P. Comparison of a technique using a new percutaneous osteosynthesis device with conventional open surgery for displaced patella fractures in a randomized controlled trial. *J Orthop Trauma.* 2006;20(8):529-35.
11. Boström Å. Fracture of the patella: a study of 422 patellar fractures. *Acta Orthopaedica Scandinavica.* 1972;43(43):1-80.
12. Yanmis İ, Oguz E, Atesalp AS, Özkan H, Kürklü M, Demiralp B, Basbozkurt M. Application of circular external fixator under arthroscopic control in comminuted patella fractures: technique and early results. *J Trauma Acute Care Surg.* 2006;60(3):659-63.
13. Pailo AF, Malavolta EA, Santos AL, Mendes MT, Rezende MU, Hernandez AJ, et al. Patellar fractures: a decade of treatment at IOT-HC-FMUSP-part I: functional analysis. *Acta Ortopédica Brasileira.* 2005;13:221-4.

**Cite this article as:** Lingayat MB, Kachnerkar NI, Bansode PR, Muslim SM, Rashinkar O. Management of patella fracture with percutaneous wiring. *Int J Res Orthop* 2023;9:1033-6.