

## Original Research Article

# Outcome of ganglion impar block in chronic coccydynia

Muhammad Farooq Butt<sup>1</sup>, Tanveer Ahmed Bhat<sup>2</sup>, Zubair Ahmad Lone<sup>3\*</sup>,  
Sanjeev Gupta<sup>1</sup>, Abdul Ghani<sup>1</sup>

<sup>1</sup>Department of Orthopaedics, Government Medical College Jammu, Jammu and Kashmir, India

<sup>2</sup>Department of Orthopaedics, Rajasthan Medical Centre, Tohana, India

<sup>3</sup>Department of Orthopaedics, Government Medical College, Handwara, Jammu and Kashmir, India

**Received:** 10 July 2023

**Revised:** 21 July 2023

**Accepted:** 24 July 2023

### \*Correspondence:

Dr. Zubair Ahmad Lone,

E-mail: [lonezubair1255@gmail.com](mailto:lonezubair1255@gmail.com)

**Copyright:** © the author(s), publisher and licensee Medip Academy. This is an open-access article distributed under the terms of the Creative Commons Attribution Non-Commercial License, which permits unrestricted non-commercial use, distribution, and reproduction in any medium, provided the original work is properly cited.

## ABSTRACT

**Background:** Chronic coccydynia is an annoying condition and is characterized by pain in the tail bone. Most cases are treated conservatively initially but failed conservative management calls for interventions of various type. One of the interventions in the armamentarium of the orthopaedic surgeon is a ganglion impar block. The present study aimed at assessing the outcome of ganglion impar block in chronic coccydynia.

**Methods:** This prospective study of five years duration included 27 patients with chronic coccydynia with failed conservative treatment. Visual analogue score (VAS) and Oswestry disability index (ODI) were used to quantify pain and the improvement in symptoms. Minimum final follow-up was two years.

**Results:** The mean VAS and ODI scores pre-injection were  $5.98 \pm 1.86$  and  $52.13 \pm 2.13$ , respectively. The mean VAS and ODI scores at final follow-up were  $2.47 \pm 1.65$  and  $23.59 \pm 2.34$ , respectively. The improvement in the above objective scores was found to be statistically significant with a  $p=0.00257$  for VAS score and  $0.00425$  for ODI score. One patient developed syncope post-injection and one patient complained of superficial injection site pain which persisted for three weeks. No significant or major complication was encountered.

**Conclusions:** Ganglion impar block appears to be a very impressive modality of treatment for chronic coccydynia in view of the simplicity, ease and reproducibility of the technique along with minimal complication rates. However, randomized control trials with large sample size are recommended.

**Keywords:** Coccydynia, Ganglion impar block, VAS, ODI

## INTRODUCTION

Coccydynia is a painful condition of the coccyx or the tail bone. Simpson is credited to be the first to have explained this condition.<sup>1</sup> Chronic coccydynia occurs due to inflammation of the coccyx due to abnormal mobility and the pain tends to be very annoying, especially during and after prolonged sitting.<sup>2</sup> It is more common in females and tends to involve the middle-aged individuals.<sup>3</sup> Coccydynia usually follows a trauma, mostly due to direct injury to

coccyx. However, idiopathic coccydynia is very common and in fact the most common type. Although, the etiology of idiopathic coccydynia is not clear, many risk factors have been quoted in literature including hypermobility of the sacrococcygeal joint, degenerative disc disease, obesity, altered coccygeal morphology and other pathologies of the anorectal area.<sup>4</sup> The initial management for all the patients with coccydynia is conservative and includes a variety of treatment options like anti-inflammatory analgesics, warm water sitz bath, ring

cushions and muscle relaxation exercises.<sup>5</sup> Patients not responding to conservative management can be offered various interventions including transcutaneous electrical stimulation, local steroid injections and coccyx excision.<sup>6</sup>

Ganglion impar lies just posterior to the rectum, anterior to the sacrococcygeal joint and coccyx. A block given into ganglion impar has shown good promise in treatment of chronic and recalcitrant coccydynia. In the present study, the authors assessed the outcome of the ganglion impar block in the management of chronic coccydynia not responding to conservative measures.

## METHODS

This prospective study of five years duration with a minimum follow-up of two years was carried out on 27 patients with chronic coccydynia with failed conservative treatment from August, 2017 to October, 2022. Informed written consent was taken from all the study participants and due ethical approval was given by the institutional ethical committee.

### Inclusion criteria

Patients with coccydynia of more than six months duration, failed conservative treatment and no pathology on radiographs and other investigations were included in study.

### Exclusion criteria

Patients with coccydynia of less than six months duration, overlying skin infection/sinus, uncontrolled diabetes and known bleeding diathesis were excluded.

27 patients of chronic recalcitrant coccydynia were enrolled in the present study and none of the patients were lost to follow-up. The patients were enrolled from the orthopaedic out patient department (OPD) of Government Medical College Jammu and ganglion impar block was given under sterile conditions in an orthopaedic operating room under fluoroscopy guidance. The patients were placed in a prone position on a C-arm compatible operating table. The inter-gluteal cleft and the surrounding area was prepared, painted with a sterile antiseptic and draped with sterile sheets. Using a C-arm under image intensity, the sacrococcygeal joint was delineated in a lateral C-arm picture. Lignocaine was injected in the overlying skin and subcutaneous tissues. A 25G spinal needle was inserted, under C-arm image guidance in lateral and anteroposterior projections, through the sacrococcygeal interval. Once the tip of the spinal needle reached just anterior to the coccyx, an iodine containing radiopaque dye was pushed into the space to confirm proper position of the needle, which is classically seen as a 'comma sign' under C-arm image guidance. A 5 ml mixture of 2% lignocaine and methylprednisolone was injected. The patients were kept under observations for one hour after injection to look out for any complications and were discharged the same day.

Quantification of pain was done pre-injection as well as 2 weeks, 1 month, 3 months, 6 months, 1 year and 2 years, post-injection. VAS and ODI were used to quantify pain and the improvement in symptoms thereof.<sup>7,8</sup> The minimum final follow-up in the present study was two years.

The data was analyzed using SPSS version 21 (IBM, New York, United states). Percentage, mean, range of the data was calculated. The pre-injection values of VAS and ODI were compared with the scores at final follow-up using Paired Student's T-test. Statistical significance was set at a  $p < 0.05$ .

## RESULTS

The present study included 27 patients with chronic coccydynia with failed conservative measures. Demographic details of the study participants have been tabulated in Table 1. Our study included 20 males (74.04%) with a male to female ratio of 2.85:1. Average age of the patients was  $44.56 \pm 8.7$  years (range: 34-53 years). In 15 patients (55.55%) there was no cause that could be ascertained to the symptoms (idiopathic). 12 patients (44.44%) gave a clear history of fall with direct trauma to tailbone. One patient developed syncope post-injection and one patient complained of superficial injection site pain which persisted for three weeks (Table 1). No significant or major complication was encountered. One patient had no improvement in symptoms and underwent a coccygectomy later. The mean VAS and ODI scores pre-injection were  $5.98 \pm 1.86$  and  $52.13 \pm 2.13$ , respectively. The mean VAS and ODI scores at final follow-up were  $2.47 \pm 1.65$  and  $23.59 \pm 2.34$ , respectively. The improvement in the above objective scores was found to be statistically significant with a  $p = 0.00257$  for VAS score and  $0.00425$  for ODI score (Tables 2 and 3). Also, significant immediate post-injection pain relief was also observed in all the patients (Figures 1 and 2).

**Table 1: Demographic details of the study group and complications observed**

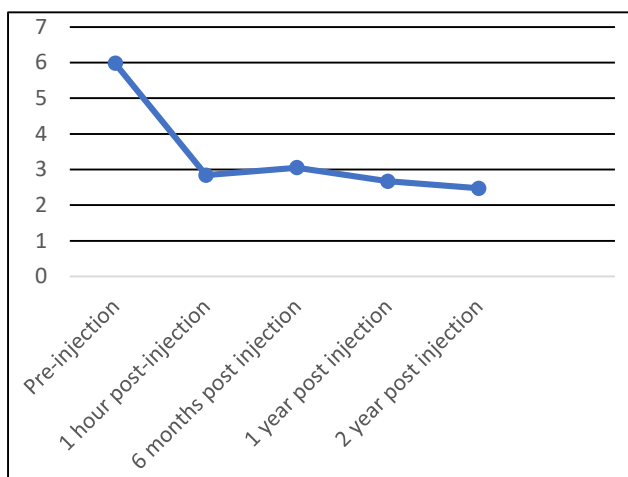
Variables	Observations, n (%)
Age of patients (Mean $\pm$ SD) (In years)	44.56 $\pm$ 8.7 (range: 34-53)
<b>Gender</b>	
Male	20 (74.04)
Female	07 (25.92)
Male: female	2.85:1
<b>Type of coccydynia</b>	
Idiopathic	15 (55.55)
Post-traumatic	12 (44.44)
<b>Complications observed</b>	
Syncope (post-injection)	01 (3.7)
Superficial injection site pain	01 (3.7)
No improvement in symptoms	01 (3.7)

**Table 2: Mean VAS score pre-injection and post-injection during follow-up, (p=0.00257).**

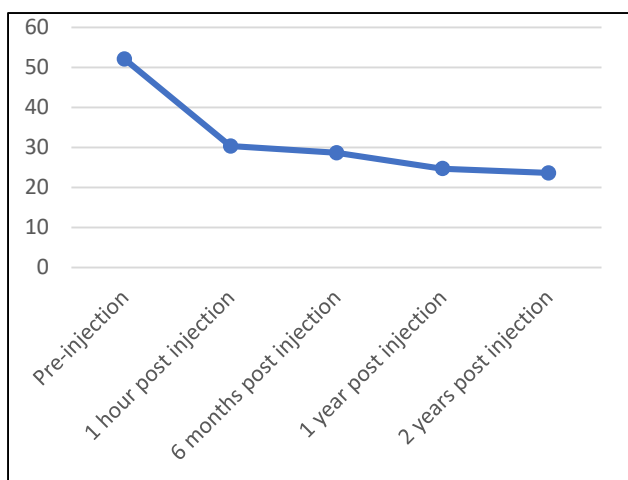
VAS scoring timing	Mean VAS score	Standard deviation
Pre-injection	5.98	±1.86
1 hour post injection	2.84	±1.01
6 months post injection	3.05	±1.02
1 year post injection	2.67	±1.42
2 years post injection	2.47	±1.65

**Table 3: Mean ODI score pre-injection and post-injection during follow-up, (p=0.00425).**

ODI scoring timing	Mean ODI score	Standard deviation
Pre-injection	52.13	±2.13
1 hour post injection	30.34	±2.54
6 months post injection	28.67	±2.10
1 year post injection	24.67	±2.44
2 years post injection	23.59	±2.34



**Figure 1: Line chart depicting improvement in VAS score over time with ganglion impar block.**



**Figure 2: Line chart depicting improvement in ODI score over time with ganglion impar block.**

## DISCUSSION

Coccydynia is still an ill understood entity in orthopaedics with respect to etiology, diagnosis and treatment.<sup>9</sup> Ganglion impar block has shown promising results in the management of chronic and recalcitrant coccydynia.<sup>10</sup> The relief in the coccydynia seems to be a result of the blockade of nociceptive and sympathetic pathways.<sup>11</sup> In the present study, the authors studied the outcome of the ganglion impar block in the management of chronic coccydynia in 27 patients with a minimum final follow-up of two years and observed statistically significant objective improvement in patients. No major complications were encountered with only one patient with a post-injection syncope noted. One patient complained of persistent symptoms and needed a surgical excision of the coccyx later. The results observed are encouraging and comparable to the results observed by the previous researchers in the field.<sup>10-14</sup>

The predominant involvement of the middle-aged individuals in the present study with a mean age of 44.56 years also seems to be similar to the previous studies.<sup>10-14</sup> The female predominance observed in the present study (M:F=2.85:1) is similar to the existing literature.<sup>10-14</sup>

The complication set observed by previous researchers seems to vary from author to author. Many have observed significant pain, tissue trauma and even rectal perforations. In the present study no such major complication was observed, which may be attributed to the use of straight needles and a gentle cautious approach, similar to the observations by Gonnade et al.<sup>10</sup>

In the present study, mean VAS and ODI scores pre-injection were 5.98±1.86 and 52.13±2.13, respectively. The mean VAS and ODI scores at final follow-up were 2.47±1.65 and 23.59±2.34, respectively. The improvement in the above objective scores was found to be statistically significant with a p=0.00257 for VAS score and 0.00425 for ODI score. Also, significant immediate post-injection pain relief was also observed in all the patients. Similar trends of objective improvement have been observed by the previous researchers using different scores and tools of pain assessment.<sup>10-14</sup>

The limitations of the present study include a small sample size and lack of control group. The authors recommend multi-centric randomized control trials be undertaken on the subject with large sample sizes.

## CONCLUSION

Ganglion impar block appears to be a very impressive modality of treatment for chronic coccydynia in view of the simplicity, ease and reproducibility of the technique along with minimal complication rates. However, randomized control trials with large sample size are recommended.

*Funding: No funding sources*

*Conflict of interest: None declared*

*Ethical approval: The study was approved by the Institutional Ethics Committee*

## REFERENCES

1. Lirette LS, Chaiban G, Tolba R, Eissa H. Coccydynia. An overview of the anatomy, etiology, and treatment of coccyx pain. *Ochsner J.* 2014;14:84-7.
2. Maigne JY, Doursounian L, Chatellier G. Causes and mechanisms of common coccydynia: Role of body mass index and coccygeal trauma. *Spine.* 2000;25:3072-9.
3. Gunduz OH, Sencan S, Kenis-Coskun O. Pain Relief due to Trans sacrococcygeal Ganglion Impar Block in Chronic Coccygodynia: A Pilot Study. *Pain Med.* 2015;16:1278-81.
4. Ellinas H, Sethna NF. Ganglion impar block for management of chronic coccydynia in an adolescent. *Paediatr Anaesth.* 2009;19:1137-8.
5. Maigne JY, Chatellier G. Comparison of three manual coccydynia treatments: A pilot study. *Spine.* 2001;26:E479-83.
6. Trollegaard AM, Aarby NS, Hellberg S. Coccygectomy: An effective treatment option for chronic coccydynia: Retrospective results in 41 consecutive patients. *J Bone Joint Surg Br.* 2010;92:242-5.
7. Jensen MP, Chen C, Brugger AM. Interpretation of visual analog scale ratings and change scores: A reanalysis of two clinical trials of postoperative pain. *J Pain.* 2003;4:407-14.
8. Fairbank JC, Pynsent PB. The Oswestry Disability Index. *Spine.* 2000;25:2940-52.
9. Wallace MS, Leung AY, McBeth MD. Malignant Pain, Textbook of Regional Anesthesia. Edited by Prithvi Raj. Pennsylvania: Churchill Livingstone Publishers. 2002;585.
10. Gonnade N, Mehta N, Khera PS, Kumar D, Rajagopal R, Sharma PK. Ganglion impar block in patients with chronic coccydynia. *Indian J Radiol Imaging.* 2017;27(3):324-8.
11. Toshniwal GR, Dureja GP, Prasanth SM. Trans sacrococcygeal Approach to Ganglion Impar Block for Management Of Chronic Perineal Pain: A Prospective Observational Study. *Pain Phys.* 2007;10:661-6.
12. Munir MA, Zhang J, Ahmad M. A modified needle-inside-needle technique for the ganglion impar block. *Can J Anaesth.* 2015;51:915-7.
13. Nebab EG, Florence IM. An alternate needle geometry for interruption of the ganglion impar. *Anesthesiology.* 1997;86:1213-4.
14. Wemm K Jr., Saberski L. Modified approach to block the ganglion impar (Ganglion of Walther). *Reg Anesth.* 1995;20:544.

**Cite this article as:** Butt MF, Bhat TA, Lone ZA, Gupta S, Ghani A. Outcome of ganglion impar block in chronic coccydynia. *Int J Res Orthop* 2023;9:952-5.