

Original Research Article

Comparative study of radiological outcomes of intertrochanteric fractures managed with intra medullary nailing with or without intraoperative temporary K-wire's stabilization

Chitturi Yashwanth*, Madhav Khadilkar, Denish Aghara

Department of Orthopaedics, Bharati Hospital and Medical Research Center, Pune, Maharashtra, India

Received: 12 May 2023

Revised: 06 September 2023

Accepted: 04 November 2023

***Correspondence:**

Dr. Chitturi Yashwanth,

E-mail: drchitturiyashwanth@gmail.com

Copyright: © the author(s), publisher and licensee Medip Academy. This is an open-access article distributed under the terms of the Creative Commons Attribution Non-Commercial License, which permits unrestricted non-commercial use, distribution, and reproduction in any medium, provided the original work is properly cited.

ABSTRACT

Background: Inter-trochanteric fractures are one of the most common hip fractures, occurring in both young adults and the elderly, as a result of high-energy trauma or low-energy trauma. These fractures are three to four times more common in elderly women with osteoporosis. The primary concern with Intertrochanteric fractures is the 20% to 30% mortality risk in the first year after the fracture.

Methods: Various methods of fracture fixation have been used in treating this fracture with intramedullary nailing has been the most favoured. In this modality maintenance of reduction during and after fixation remains a concern. The temporary stabilization of fracture with K-wires for minimally invasive fixation of Intertrochanteric fracture with an intramedullary nail is advocated and aids in keeping the fracture reduction in place while proximal reaming and nail introduction.

Results: In this study a total of 80 patients with intertrochanteric fractures were included, of which 45 patients operated with temporary K-wire, 43 patients reduction was maintained and loss of reduction was noted in 2 patients (4.4%) and 35 patients operated without K-wire, 29 patients reduction maintained and lost in 6 patients (17.1%).

Conclusions: There was no statistically significant, difference in the 2 groups with respect to intra/post-operative loss of reduction. Having a larger study group the results may have a statistically significant outcome.

Keywords: K-wire stabilization, Intertrochanteric fractures, Intramedullary nailing

INTRODUCTION

Every year, approximately 250,000 hip fractures occur in the United States, with half of these being intertrochanteric. Because of the large number of these fractures, successful treatment is obviously important both for the individual patient's benefit and for economic reasons. The surgeon's job is to choose the right fixation device and apply it correctly after the fracture has been properly reduced.¹

Because of changes in population demographics, the incidence of proximal femoral fractures is on the rise. Regaining pre-fracture ambulatory function and autonomy is critical, especially for elderly patients. For intra- and extracapsular fractures, intramedullary and extramedullary fixations are the most common options. The unique anatomy of the trochanteric region of the femur, as well as the occurrence of high varying forces, make it difficult and necessitate sophisticated surgical treatment.²

Because the majority of patients with intertrochanteric fractures are elderly, surgical treatment must be quick and allow for immediate weight bearing.³ The goal of treatment in this already vulnerable population is to achieve a rapid return to previous functional levels with a low rate of complications and mortality. As a result, for the vast majority of intertrochanteric femur fractures (IFF), surgical management is the mainstay of treatment. Internal fixation (IF) is often the preferred treatment option intramedullary nails for fixation is the most favoured modality of fixation now compared to other modalities. A wide range of extramedullary and intramedullary devices are available for this purpose.^{4,5}

The Boyd and Griffin classification is used to classify intertrochanteric fractures: type I- linear Intertrochanteric; type II- with comminution of trochanteric region; type III- with comminution associated with the reverse obliquity; type IV- intertrochanteric fracture with extension into the subtrochanteric region.^{6,7} When treating trochanteric fractures, it is critical to distinguish between unstable and stable variants. A stable Intertrochanteric fracture has cortical contact without gaps posteriorly or medially when reduced.⁸

The primary concern with intertrochanteric fractures is a 20% to 30% mortality risk in the first year following the fracture. The majority of these fractures are treated surgically with a sliding hip screw or an intramedullary nail.¹²

Stable fracture patterns with an intact lateral wall are indications for the sliding hip screw. Intertrochanteric fractures can be treated with intramedullary nailing in a variety of ways, including the more unstable patterns like reverse obliquity.

Although the intramedullary fixation been one of the mainstay of treatment among other methods, maintenance of fracture reduction through surgery while reaming and passing nail poses an serious problem, causing loss of reduction. Use of temporary fracture stabilisation intraoperative with K-wires has been advocated to prevent loss of reduction in intraoperative/postoperative period. Compared to traditional open surgery, disadvantages for fracture fixation could be effectively addressed; operation and recovery times are significantly reduced. This technique is inexpensive, simple to use, quick to execute, safe, and repeatable with good results.¹³

In view of this, the present study aimed to compare the stability of reduction in patients with intertrochanteric fractures managed using intramedullary nailing with or without intraoperative temporary K-wire stabilization.

METHODS

The present study was prospective non-randomised control trail done in the Department of Orthopedics, Bharati Vidyapeeth (DTU) Medical College and Hospital, Pune.

The research was carried out over the course of 18 months, from October 1, 2020 to March 31, 2022. A total of 80 patients with an intertrochanteric femur fracture attending IPD/OPD of the orthopaedics department, of either gender, and above the age of 18 years, treated with closed reduction using intramedullary nailing, were included in the present study. Total 45 patients were managed with intramedullary nailing and intraoperative temporary K-wire stabilisation as a study group, and 35 patients were managed without intraoperative temporary K-wire stabilisation as controls. The convenient sampling was used. Patients with pathological fractures were excluded from the study.

All the necessary preoperative work-up for the patients was done in the form of hematological and radiological examinations. After explaining the study, informed consent was obtained from each participant, and the study was approved by the institutional ethics committee.

Surgical technique used

After anaesthesia induction manual fracture reduction was performed on fracture table or in lateral position before painting and draping. Once an acceptable reduction was achieved, scrubbing painting and draping done. Using percutaneous reduction technique two 3 mm K wire inserted starting from the lateral femoral wall around 1 centimetre below the trochanteric ridge just beneath the anterior cortex and was advanced superomedially into the neck and head to avoid the path of the intramedullary nail posteriorly. Patient assessment was done intraoperatively.

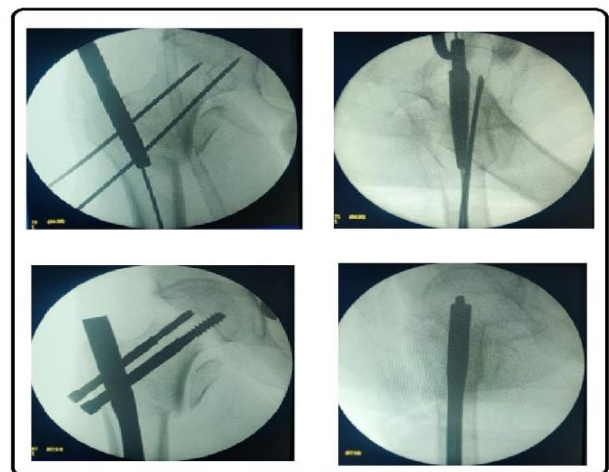


Figure 1: Fluoroscopic images showing temporary fixation with k wires passed intraoperatively to maintain reduction.

The collected data was entered into a Microsoft Excel sheet. The data was analysed using SPSS (Statistical Package for Social Sciences) version 26.0 software. The quantitative parameters were presented as mean \pm SD (standard deviation). The qualitative data was presented as frequencies and percentages and compared between

groups using the Chi-square test. The p value of <0.05 was considered significant.

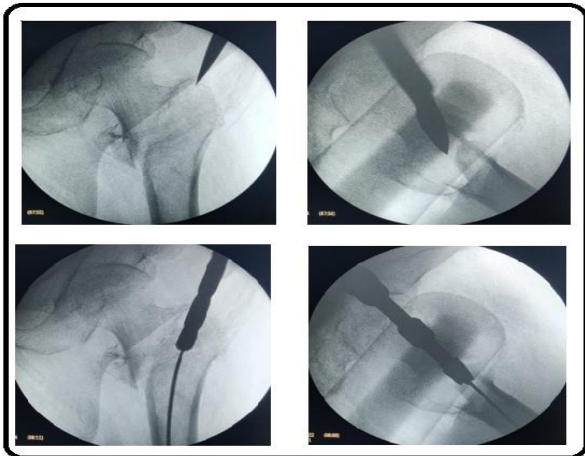


Figure 2: Fluoroscopic images showing loss in reduction while passing intramedullary nail intraoperatively without temporary fixation.

RESULTS

A total of 80 patients who had intertrochanteric fractures were included in the present study, of whom 45 were managed with intramedullary nailing with intraoperative temporary K-wire stabilisation and 35 without intraoperative temporary K-wire’s stabilization. The average age of the patients was 69.65±14.73 years. In the study population, the average neck shaft angle was 130.61±4.31 degrees. There were 42 (52.5%) males and 38 (47.5%) females, with a male-to-female ratio of 1.11:1. The mean age of the patients in whom K wire was used was 71.71±14.26 years, and that of the patients without K wire was 68.04±15.20 years, the difference in the means was non-significant (p=0.2706).

Table 1: Descriptive statistics.

		Frequency	Percent
Side	Right	45	56.25
	Left	35	43.75
Type of fracture	Type 1	16	20.0
	Type 2	53	66.2
	Type 4	11	13.8
State of reduction	Maintained	72	90.0
	Not maintained	8	10.0

In 45 (56.3%) of all patients, the right side had a fracture, while the left side in 35 (43.8%).The patients were distributed according to Boyd and Griffin's classification, with more than half (53/80, (66.3%)) of patients having type 2 fractures, followed by type 1 (16 (20%)) and type 4 (11 (13.8%)). Among 80 patients, in the majority, 72 (90%) patients’ reduction was maintained, and it was not maintained among 8 (10%) patients. The results are indicated in Table 1.

Among 80 patients in study, 45 patients operated with temporary K-wire, 43 patients reduction was maintained and loss of reduction was noted in 2 patients (4.4 %) and 35 patients operated without K-wire, 29 patients reduction maintained and lost in 6 patients (17.1%).

Table 2: Association of status of reduction with gender, use of K wire, type of fracture.

		Reduction				P value
		Maintained		Not maintained		
		N	%	N	%	
Sex	Female	33	45.8	5	62.5	0.467
	Male	39	54.2	3	37.5	
K wire used	No	29	40.3	6	75.0	0.129
	Yes	43	59.7	2	25.0	
Type of fractures	1	15	20.8	1	12.5	0.821
	2	47	65.3	6	75.0	
	4	10	13.9	1	12.5	

DISCUSSION

With a variety of fracture geometries and a large selection of implants and techniques, unstable intertrochanteric fractures pose a challenge to Orthopaedic surgeons. Patients tend to be osteoporotic, have numerous comorbidities, and have a low threshold for complications and repeat operations. For these challenging injuries, lateral wall reconstruction and the stability of the trochanteric fragments are thought to be crucial for a better outcome.¹⁴ Intertrochanteric fractures after reduction may often result in a limb length discrepancy causing maladaptation of the abductor lever arm. Functional limitations can also result from altered hip biomechanics.¹⁵

Elderly people frequently suffer from these fractures, which are typically brought on by falling from a standing position.^{16,17} In contrast, these fractures are uncommon in young adults and are typically brought on by high-energy injuries. Young intertrochanteric femoral fractures are thus severely comminuted and displaced. Anatomical reduction through closed maneuver is very challenging because the muscular forces of the hip could worsen fragment deformation.^{17,18}

The present study compared the outcomes of intertrochanteric fractures managed with intramedullary nailing with or without intraoperative temporary K-wire stabilization. A total of 80 patients with intertrochanteric fractures were included, of whom 45 were managed with intramedullary nailing with intraoperative temporary K-wire stabilization and 35 without intraoperative temporary K-wire stabilization.

In our study, the distribution of patients according to laterality was almost equal, with a slightly higher number having a right-side fracture. According to Boyd and Griffin's classification; more than half of the patients had type 2 fractures, followed by type 1 and type 4. The

majority of patients (90%) maintained the reduction, but the remaining 10% did not.

Among 80 patients in study, 45 patients operated with temporary K-wire, 43 patients reduction was maintained and loss of reduction was noted in 2 patients (4.4 %) and 35 patients operated without K-wire, 29 patients reduction maintained and lost in 6 patients (17.1%). In a related study, Gu-Hee J, demonstrated that provisional K-wire fixation in trochanteric fracture treated with PFN had an advantage in preventing loss of reduction as it facilitates a nail insertion in ideal position.²⁰

The effectiveness of K-wire stabilization with intramedullary nailing for intertrochanteric fractures has only been briefly studied. In a study by Wang ZH et al, have reported use of additional support techniques for intramedullary nailing like lateral locking plate and cerclage steel wire, the rate of fracture reduction quality was good in the plate group than in the encircalage wire group, with significantly lower fracture healing time.²²

With the use of same technique, Dr. Digambar S Maraskolhe et al, among the sample size of 30, intraoperative maintenance of reduction with temporary K-wire fixation was a good alternative for maintenance of reduction intraoperatively for AO-OTA31 A1 and A2 intertrochanteric fractures while passing intramedullary nail.²³ In our study also we found the technique to be good in maintaining intraoperative reduction with K-wire. However, in the above mentioned study there was no control group.

This study has some limitations. The current study provides valuable insights into the use of K-wire's for intertrochanteric femur fractures fixation. However, due to the limited sample size, there is a potential for bias and the generalizability of the results may be compromised. Moreover, a larger sample size will increase statistical power and precision, reducing the risk of type II errors and providing more accurate estimates of effect sizes. Doing so will enhance the validity, reliability, and generalizability of the findings, ultimately contributing to the advancement of medical knowledge and improving patient care.

CONCLUSION

The present study was carried out to compare outcomes of intertrochanteric fractures managed with Intra medullary nailing with or without intraoperative temporary K-wire's stabilization. Although we started with an assumption that temporary stabilisation with K-wire's may be a better way to maintain reduction. The study did not reveal any statistically significant difference in both the groups, with regards to maintenance of reduction intraoperatively.

Funding: No funding sources

Conflict of interest: None declared

Ethical approval: The study was approved by the Institutional Ethics Committee

REFERENCES

- Kokoroghiannis C, Aktseles I, Deligeorgis A, Fragkomichalos E, Papadimas D, Pappadas I. Evolving concepts of stability and intramedullary fixation of intertrochanteric fractures-a review. *Injury*. 2012;43(6):686-93.
- Hoffmann MF, Khoriaty JD, Sietsema DL, Jones CB. Outcome of intramedullary nailing treatment for intertrochanteric femoral fractures. *J Orthop Surg Res*. 2019;14(1):360.
- Ruecker AH, Rupprecht M, Gruber M, Gebauer M, Barvencik F, Briem D, et al. The treatment of intertrochanteric fractures: results using an intramedullary nail with integrated cephalocervical screws and linear compression. *J Orthop Trauma*. 2009;23(1):22-30.
- Huusko TM, Karppi P, Avikainen V, Kautiainen H, Sulkava R. Randomised, clinically controlled trial of intensive geriatric rehabilitation in patients with hip fracture: subgroup analysis of patients with dementia. *BMJ*. 2000;321(7269):1107-11.
- Kaplan K, Miyamoto R, Levine BR, Egol KA, Zuckerman JD. Surgical management of hip fractures: an evidence-based review of the literature. II: intertrochanteric fractures. *J Am Acad Orthop Surg*. 2008;16(11):665-73.
- Boyd HB, Griffin LL. Classification and treatment of trochanteric fractures. *Arch Surg (1920)*. 1949 Jun;58(6):853-66.
- Ahn J, Bernstein J. Fractures in brief: Intertrochanteric hip fractures. *Clin Orthop Relat Res*. 2010;468(5):1450-2.
- Balathithyan R, Venkatachalam K. Analysis of outcome of proximal femoral nailing in unstable trochanteric fractures: A prospective study. *Int J Orthop Sci*. 2019;5(2):661-9.
- Gong J, Liu P, Cai M. Imaging evaluation of the safe region for distal locking screw of proximal femoral nail anti-rotation in patients with proximal femoral fracture. *Med Sci Monit*. 2017;23:719-24.
- Wang F, Meng C, Cao XB, Chen Q, Xu XF, Chen Q. Hemiarthroplasty for the treatment of complicated femoral Intertrochanteric fracture in elderly patients. *Zhongguo Gu Shang*. 2018;31(9):818-23.
- Sharma A, Sethi A, Sharma S. Treatment of stable Intertrochanteric fractures of the femur with proximal femoral nail versus dynamic hip screw: a comparative study. *Rev Bras Ortop*. 2018;53(4):477-81.
- Attum B, Pilson H. Intertrochanteric Femur Fracture. In: *StatPearls*. Treasure Island (FL): StatPearls Publishing; 2020.
- Tian K, Liu C, Yan J, Fan K, Fan K, Ma W, et al. Feasibility study of Kirschner wire-fixation-cortical bone technique in treatment of intertrochanteric fracture. *Chin J Repar Reconstr Surg*. 2019;33(10):1239-44.
- Kulkarni SG, Babhulkar SS, Kulkarni SM, Kulkarni GS, Kulkarni MS, Patil R. Augmentation of

- intramedullary nailing in unstable intertrochanteric fractures using cerclage wire and lag screws: a comparative study. *Injury.* 2017;48:18-22.
15. Paul O, Barker JU, Lane JM, Helfet DL, Lorich DG. Functional and radiographic outcomes of intertrochanteric hip fractures treated with calcar reduction, compression, and trochanteric entry nailing. *J Orthop Trauma.* 2012;26(3):148-54.
 16. Koval KJ, Zuckerman JD. Hip fractures: II. Evaluation and treatment of intertrochanteric fractures. *J Am Acad Orthop Surg.* 1994;2(3):150-6.
 17. Gao YS, Guo YJ, Yu XG, Chen Y, Chen C, Lu NJ. A novel cerclage wiring technique in intertrochanteric femoral fractures treated by intramedullary nails in young adults. *BMC Musculoskelet Disord.* 2018;19(1):359.
 18. Kregor PJ, Obrebsky WT, Kreder HJ, Swiontkowski MF. Evidence-based orthopaedic trauma working group. Unstable pertrochanteric femoral fractures. *J Orthop Trauma.* 2005;19(1):63-6.
 19. Siddiqui YS, Khan AQ, Asif N, Khan MJ, Sherwani MKA. Modes of failure of proximal femoral nail (PFN) in unstable trochanteric fractures. *MOJ Orthop Rheumatol.* 2019;11(1):7-16.
 20. Gu-Hee J. Treatment of the intertrochanteric femoral fracture with proximal femoral nail: nailing using the provisional k-wire fixation. *JKFS.* 2011;24(3):223-9.
 21. Bhat TA, Butt MF, Beigh IA, Mantoo SA, Ahmad MN, Ganie IA. Comparative study of intramedullary nailing in reverse obliquity intertrochanteric fractures with or without cerclage wire augmentation. *Int J Orthop Sci.* 2019;5(4):192-5.
 22. Duan X, Tong D, Zhang H, Ji F. Intramedullary nailing of intertrochanteric fractures-minimal invasive techniques for reduction. *Res Squa.* 2021:1-11.
 23. Maraskolhe DS, Chawla AB, Harne NM. An alternate method to maintain reduction in proximal femur nailing of intertrochanteric femur fracture: temporary k wire fixation. *Paripex-Ind J Res.* 2020;9(8).

Cite this article as: Yashwanth C, Khadilkar M, Aghara D. Comparative study of radiological outcomes of intertrochanteric fractures managed with intra medullary nailing with or without intraoperative temporary K-wire's stabilization. *Int J Res Orthop* 2024;10:64-8.