

## Original Research Article

# Functional outcome of intertrochanteric fractures treated with trochanteric stabilizing plates

Sunil H. Shetty, Abdul Malik Nagori, Manan B. Paneliya\*, Vidur Sharma,  
Digvijay S. Patil, Aaishree Shetty

Department of Orthopaedics, D.Y. Patil Hospital and Research Centre, Nerul, Navi Mumbai, Maharashtra, India

**Received:** 02 March 2023

**Revised:** 14 March 2023

**Accepted:** 17 March 2023

### \*Correspondence:

Dr. Manan B. Paneliya,

E-mail: [paneliyamanan@gmail.com](mailto:paneliyamanan@gmail.com)

**Copyright:** © the author(s), publisher and licensee Medip Academy. This is an open-access article distributed under the terms of the Creative Commons Attribution Non-Commercial License, which permits unrestricted non-commercial use, distribution, and reproduction in any medium, provided the original work is properly cited.

## ABSTRACT

**Background:** Intertrochanteric fractures account for significant percentage of health care costs and result in high rates of morbidity and mortality. Since higher rate of mortality and complications most fractures can be successfully treated with trochanteric stabilizing plates. This study was conducted to assess functional outcome in intertrochanteric fracture femur treated with trochanteric stabilizing plates and define ideal mode of fixation for such fractures. Trochanter stabilizing plate (TSP) is modular extension of dynamic hip screw (DHS) that is mounted on lateral femoral wall to stabilize greater trochanter. It provides the flexibility to achieve plate to bone apposition as well as axial compression or angular stability because of three screw fixations at the proximal fragment. TSP can provide a stress shield for the lateral trochanteric wall and prevent lateral migration of proximal fragments. Thus, TSP does not fail at the screw bone interface and provide a strong anchor in osteoporotic bone. The multiple locking screw holes of the TSP provide various options to tackle complex fracture pattern. It functions as an internalized external fixator and minimizes the pressure on the periosteum and encourages biological healing.

**Methods:** A total of 30 subjects of intertrochanteric fractures undergoing treatment with trochanteric stabilizing plates were taken up for the study after informed consent.

**Results:** Significant results were obtained using Harris hip score (HHS) at different postoperative follow up time intervals with good outcome and low complication rate.

**Conclusions:** Trochanteric buttress plate creates biomechanically stable construct by incorporating the comminuted trochanter it restores the proximal femoral anatomy, ensuring anatomical reduction hence subsequently reduces limb length discrepancy. We thus conclude this is an effective technique and has excellent functional and radiological outcomes with minimal complication and early rehabilitation rates. As Intertrochanteric fractures of the hip is a very common condition affecting a large number of patients of variable demographics and racial background, a more widespread study is required for a more conclusive study.

**Keywords:** Intertrochanteric fractures, Femur, TSP

## INTRODUCTION

There were an estimated 1.66 million hip fractures worldwide in 1990.<sup>1</sup> This worldwide annual number is rising rapidly with an expected incidence of 6.26 million by the year 2050.<sup>1,4</sup> An increase in these fractures is on the rise due to the increased life expectancy of the people and

osteoporosis.<sup>1-5</sup> The mechanism of injury is mostly trivial trauma. Hip fractures comprise fractures of intracapsular and extracapsular region or combination of both. Intertrochanteric fractures are common in the elderly female due to osteoporosis and 90% of fractures result from simple fall.<sup>6</sup> As conservative methods resulted in higher mortality rates ranging from 4.5- 22% they are now

indicated only for elderly person with high medical risk for anesthesia and surgery.<sup>7</sup> Thus, surgery by internal fixation is the ideal choice. The aim of the surgery is to achieve initial stability and early mobilization of the patients and to avoid complications such as deep vein thrombosis, pulmonary embolism, urinary and lung infections and bed sores.<sup>7</sup> For most intertrochanteric fracture (ITF) patients, closed reduction and internal fixation is the standard treatment for pain relief and early mobility. DHS is one of the most common fixation devices for ITF, especially unstable fractures (Boyd and Griffin type I or II). TSP is a modular extension of DHS that is mounted on the lateral femoral wall to stabilize greater trochanter. It provides the surgeon with the flexibility to achieve plate to bone apposition as well as axial compression or angular stability because of three screw fixation at the proximal fragment. Unlike conventional compression plates, the screw head locks into the plate, thereby creating an angular stable construct. TSF can provide a stress shield for the lateral trochanteric wall and prevent lateral migration of proximal fragments. Thus, TSF does not fail at the screw bone interface and provide a strong anchor in osteoporotic bone. The multiple locking screw holes of TSF provide various options to tackle complex fracture pattern. It functions as an internalized external fixator and minimizes the pressure on the periosteum and encourages biological healing.<sup>12</sup>

However, studies related to TSP in stable intertrochanteric fractures are relatively scarce. In present study, we thus aimed to assess the functional outcome of intertrochanteric fractures treated with trochanteric stabilizing plate.

## **METHODS**

### **Study area**

Study conducted at department of orthopaedics, Dr. D. Y. Patil Medical College, Navi Mumbai.

### **Study population**

Patients with intertrochanteric fractures who were admitted in orthopaedic ward of Dr. D. Y. Patil Medical College, Navi Mumbai and were treated with trochanteric plates were included in the study.

### **Study design**

A prospective observational study design was used.

### **Sample size calculation**

A total of 30 subjects of intertrochanteric fractures undergoing treatment with TSP were taken up for the study after informed and written-consent.

### **Study duration**

Study conducted from July 2020 to December 2022.

## **Ethics**

Permission of the institutional ethics committee was taken before commencement of the study. An informed written consent was taken from each participant before being included in the study.

## **Inclusion criteria**

All adults, consenting patients and patients with intertrochanteric fractures type I to IV (Boyd and Griffin) were included.

## **Exclusion criteria**

Patients with age <18 years, non consenting patients and pathological fractures were excluded from the study.

## **Methodology**

Patients admitted with intertrochanteric fracture were examined and investigated with X-ray pelvis with both hips AP and lateral view (whenever possible). Blood and urine-examinations were ordered as follows:

### **Investigations**

Blood-Hb%, total count, differential count, E.S.R. and urine-albumin, sugar, microscopy. Blood grouping and Rh type and bleeding time and clotting time.

### **Special investigations**

In patients with age more than 40 years and as advised by an anesthetist: HIV, HbsAg, blood urea, serum creatinine, blood sugar level, ECG and chest X-ray.

## **Routine clinical follow up**

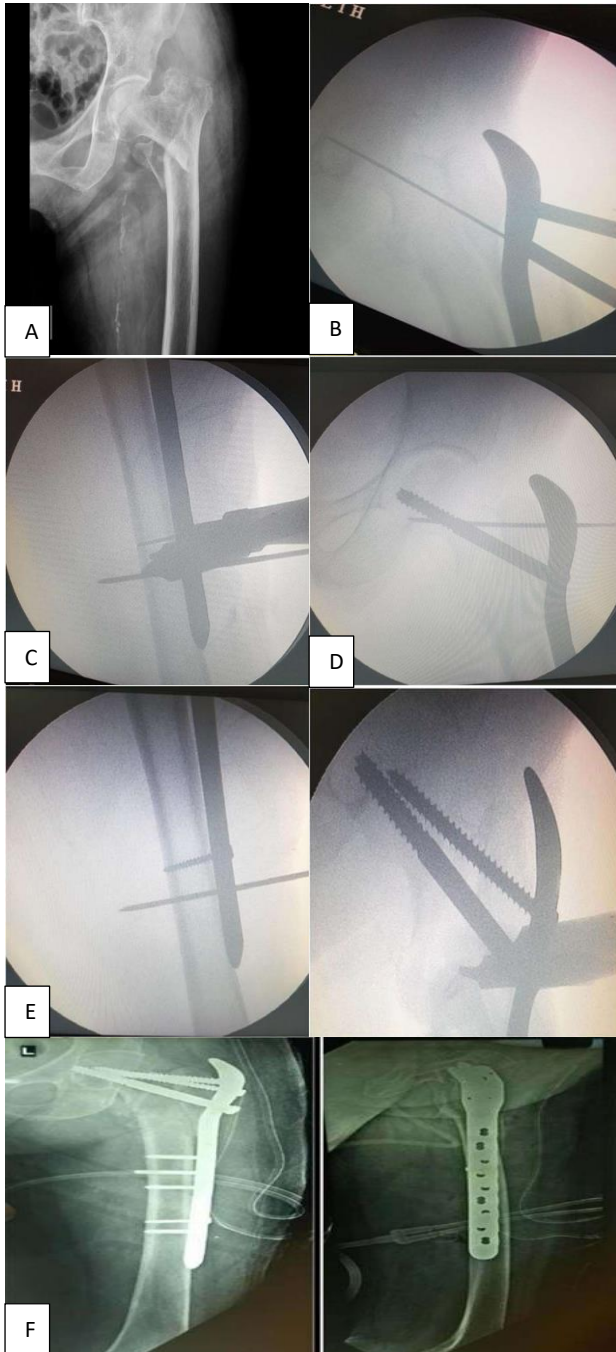
The patients were assessed in 1<sup>st</sup> week, 2<sup>nd</sup> week, 4<sup>th</sup> week, 12<sup>th</sup> week, 24<sup>th</sup> week (6 months), 36<sup>th</sup> week (9 month) and 48<sup>th</sup> week (12-month). In each follow up, functional HHS was recorded; range of motion and time taken for patients to weight bearing was also noted. Assessment to be done at each follow up with following points: Post-operative wound condition, reduction-varus/valgus, angulation, range of motion and time to weight bear, functional hip score at 1<sup>st</sup> month, 3<sup>rd</sup> month, 6<sup>th</sup> month, 9 months and 1 year, time duration for callus formation.

Following complications were noted: infection, implant failure, lysis and loosening of the implant site, a vascular necrosis of femur head and arthritis, non-union, malunion, bed sore.

Functional outcome was assessed using the HHS. A total score below 70 points is considered a poor result, 70 to 80 as reasonable, 80 to 90 as good and 90 to 100 as excellent.

**Statistical analysis**

The quantitative data was represented as their mean±SD. Categorical and nominal data was expressed in percentage. The t test was used for analysing quantitative data, or else non-parametric data was analysed by Mann Whitney test and categorical data was analyzed by using chi-square test. All analysis was carried out by using SPSS software version 21.



**Figure 1 (A-F): Pre op X-ray of intertrochanteric fracture. After reduction initial guide wire passed at 135°, 90° K wire in shaft (AP). 135° bolt passed in head, 90° locking screw passed in the shaft of femur, final post op X-ray (AP and Lateral).**

**RESULTS**

Mean age of the study group was 68.9 years with 66.7% of the cases being above 60 years of age.

**Table 1: Distribution of cases as per age group.**

Age group (years)	N	Percentages (%)
51-60	10	33.3
61-70	6	20
71-80	9	30
>80	5	16.7
<b>Total</b>	<b>30</b>	<b>100</b>
<b>Mean</b>	<b>68.9±9.8</b>	

**Table 2: Distribution of cases as per gender.**

Gender	N	Percentages (%)
<b>Male</b>	<b>9</b>	<b>30</b>
<b>Female</b>	<b>21</b>	<b>70</b>
<b>Total</b>	<b>30</b>	<b>100</b>

Female predominance was observed in the study with 70% female subjects to 30% males.

**Table 3: Distribution of cases as per laterality.**

Laterality	N	Percentages (%)
<b>Right</b>	<b>20</b>	<b>66.7</b>
<b>Left</b>	<b>10</b>	<b>33.3</b>
<b>Total</b>	<b>30</b>	<b>100</b>

Right side was predominantly involved (66.7%) than left side (33.3%).

**Table 4: Distribution of cases as per associated co-morbidities.**

Co morbidities	N	Percentages (%)
<b>DM (Unaccompanied)</b>	<b>4</b>	<b>13.3</b>
<b>HT (Unaccompanied)</b>	<b>2</b>	<b>6.7</b>
<b>HT and DM</b>	<b>7</b>	<b>23.3</b>
<b>Others</b>	<b>2</b>	<b>6.7</b>

Associated co-morbidities included only diabetes in 4 patients (13.3%), only hypertension in 2 patients (6.7%), both DM and HT (23.3%) and hyperthyroidism (others) in 2 patients (6.7%).

**Table 5: Distribution of cases as per mode of the injury.**

Mode of injury	N	Percentages (%)
<b>RTA</b>	<b>8</b>	<b>26.7</b>
<b>Fall</b>	<b>22</b>	<b>73.3</b>
<b>Total</b>	<b>30</b>	<b>100</b>

**Table 6: Mean operative time, intra-op blood loss and hospital stay.**

Variables	Mean	SD
Operative time (min)	112.2	28.8
Amount of blood loss (ml)	192.3	80.9
Duration of hospital stay (days)	7.8	2.2

Most common mode of injury was history of accident was fall (73.3%) as well as the history of road traffic accident was given by the 26.7% subjects.

The mean blood loss intraoperatively (ml) was 192.3±80.9 while mean operative time was 112.2±28.8 min. Average length of hospital stay (days) was 7.8±2.2 days.

**Table 7: Distribution of cases as per associated complications.**

Complications	N	Percentages (%)
Infections	2	6.7
Loosening of implant	0	0
AVN	0	0
Delayed union	0	0
Mal-union	2	6.7
Non-union	0	0
Implant failure	0	0
Bed sores	0	0

Complications included superficial surgical site infections (6.7%) and malunion (6.7%). No case of non-union or implant failure was noted in present study.

**Table 8: Mean time to full weight bearing, return to normal activity and bony union.**

Variables	Mean	SD
Time to full weight bearing (weeks)	1.21	0.23
Return to normal activity (weeks)	16.50	1.97
Complete bony union (weeks)	14.42	1.67

The time to independent full weight bearing was 1.21 weeks and return to the pre-fracture level of normal activity was possible in 16.5 weeks while complete bony union was achieved in 14.42 weeks.

Mean HHS was 68.1 at 1 month which improved to 88.53 by the end of 12 months.

**Table 9: Mean improvement in HHS at the follow ups.**

HHS (Months)	Mean	SD
1	68.10	5.76
3	75.33	8.70
6	81.53	6.10
9	85.00	5.10
12	88.53	5.10

**Table 10: Distribution of cases as per functional outcome.**

Functional outcome	N	Percentages (%)
Excellent	14	46.7
Good	13	43.3
Fair	3	10
Poor	0	0
Total	30	100

Overall excellent to good functional outcome was seen in 46.7% and 43.3% cases. A total of 3 cases (10%) reported fair outcome while none of the cases had poor outcome.

## DISCUSSION

The goal of our study was to assess the functional outcome of intertrochanteric fractures treated with trochanteric plates. A total of 30 patients with type 1-4 (Boyd and Griffin), intertrochanteric fracture cases undergoing treatment with TSP were taken up for the study after informed consent. Patients admitted with intertrochanteric fracture were examined and investigated with X-ray pelvis with both hips AP and lateral view (whenever possible). After plating, patients were assessed in 1st week, 2nd week, 3rd week, 12th week, 6th month, 9th month and 12th month. In each follow up, 1) Functional hip score 2) Range of motion, 3) time taken for patients to height bearing and 4) Time for bony union was also noted. Functional outcome was assessed using the HHS. The above study was based on a series of 30 patients; however we feel that a larger study (series) would provide us a more conclusive as well as better understanding of the trochanteric stabilizing plate.

### Demography

Mean age of the study group was 68.9 years with 66.7% of the cases being above 60 years of age. Female predominance was observed in the study with 70% female subjects to 30% males.

Shetty et al observed in their study observed 83.3% of the patients being over 50 years of age.<sup>3</sup> White and colleagues did a study of rate of mortality for elderly patients after fracture of the hip in the 1980's and they concluded that the average age for trochanteric fractures is 75.4 years.<sup>6</sup> Dahl and colleagues, observed in similar study that 65% of patients were females compared to 35% males.<sup>7</sup> Sinno et al in their study observed an average age at presentation was 78.6 years (range, 70 to 96 years) and there were fourteen men and thirty four women.<sup>8</sup> Sancheti et al conducted study to analyze the role of primary hemiarthroplasty in cases of unstable osteoporotic intertrochanteric femur fractures. There were 27 females and ten males with mean age of 77.1 years (range, 62 to 89 years).<sup>9</sup> Female predominance can be explained by the fact that female are more prone for the osteoporosis after menopause.

### Mode of injury

Most common mode of injury was history of fall at home (trivial fall) (73.3%) while history of road traffic accident was given by 26.7% subjects.

The study results support the view that bone stock plays an important role in the causation of fractures in the elderly, which occur after a trivial fall. Similar results were also observed by Sinno et al and Gangadharan et al.<sup>8,10</sup> Patil et al in their study also observed, mode of trauma to be significantly more due to trivial fall (61.4%) than road traffic accident (38.6%).<sup>4</sup>

### Operative parameters

The mean blood loss intraoperatively (ml) was 192.3±80.9 while mean operative time was 112.2±28.8 min. Average length of hospital stay (days) was 7.8±2.2 days.

In the study by Patil et al mean blood loss intraoperatively (ml) was 131.8 ml while mean operative time was 104.54 mins.<sup>4</sup> Average length of hospital stay (days) was 7.1 days. Ganjale et al in their study observed mean duration of surgery as 75 min (45-80 min) while mean intraoperative blood loss was 180 ml (110-220 ml).<sup>5</sup>

### Complications

There were no major complications seen except superficial surgical site infections in 2 patients which resolved after a week of IV antibiotics (6.67%). Delayed union, non-union, loosening of implants, AVN was not seen in any of the cases while malunion was encountered in 2 patient (6.67%). Complications noted in the study by Patil et al were bed sores (13.5%), superficial infection (4.5%), implant failure and non-union (4.5% each).<sup>4</sup> In a similar study by Ganjale et al four patients developed local complications including lateral migration of neck screws (7.1%), infection (7.1%), no case of nonunion or implant breakage was observed.<sup>5</sup> Two patients (14.3%) had malunion.

### Functional outcome

Mean HHS was 68.1 at 1 month which improved to 88.53 by the end of 12 months. Overall excellent to good functional outcome was seen in 46.7% and 43.3% cases respectively. A total of 3 cases (10%) reported fair outcome while none (0%) of the cases had poor outcome.

Shetty et al in their study observed that 9 of the 32 patients (28%) had excellent results.<sup>3</sup> Ten patients (31%) had good results. Nine patients had fair (28%) and four patients (13%) had poor results. Patil et al in their study observed 6 cases with excellent (27.3%), 12 cases (54.5%) with good and 4 cases (18.2%) with fair result with no case of poor result.<sup>4</sup> In study by Ganjale et al 87.5% of the cases had excellent to good results.<sup>5</sup> Our results were

also comparable to series by Gupta et al who concluded that supplementation of DHS with TSP brought about overall improvement in functional and radiological outcome of hip with unstable intertrochanteric fractures. They also reported that TSP provided a stable construct with maintenance of lever arm with adequate abductor strength.<sup>10</sup> A biomechanical study by Bong and colleagues reported that use of TSP had ability to avoid femoral medialization comparable to those of intramedullary devices.<sup>11</sup> Matre and colleagues concluded that selective use of TSP improved functional outcomes of hip.<sup>12</sup> Madsen et al in their study on comparison of DHS with TSP versus Gamma nails for management of unstable intertrochanteric fractures, concluded that use of the TSP avoided medialization of distal fracture and chances of femoral shaft fractures during gamma nail insertion was avoided. They also concluded that there was reduced lag screw sliding distance in cases operated with DHS and TSP.<sup>13</sup> Thus to summarize, TSP fixation of intertrochanteric fractures of femur is effective technique and excellent functional and radiological outcomes with minimal complication and early rehabilitation rates.

### CONCLUSION

Trochanteric buttress plate creates a biomechanically stable construct by incorporating the comminuted trochanter it restores proximal femoral anatomy, ensuring anatomical reduction hence subsequently reduces limb length discrepancy. We thus conclude that trochanteric plate fixation of intertrochanteric fractures of femur is an effective technique and has excellent functional and radiological outcomes with minimal complication and early rehabilitation rates.

As intertrochanteric fracture of hip is a common injury affecting a large number of patients of variable demographics and racial background, a more widespread study is required for a more conclusive study.

*Funding: No funding sources*

*Conflict of interest: None declared*

*Ethical approval: The study was approved by the Institutional Ethics Committee*

### REFERENCES

1. Kannus P, Parkkari J, Sievänen H, Heinonen A, Vuori I, Järvinen M. Epidemiology of hip fractures. *Bone* 1996;18:57S-63S.
2. Koval KJ, Zuckerman JD. Hip fractures are an increasingly important public health problem. *Clin Orthop Relat Res.* 1998;348:2.
3. Rockwood PR, Horne JG, Cryer C. Hip fractures: A future epidemic? *J Orthop Trauma.* 1990;4:388-93.
4. Frandsen PA, Kruse T. Hip fractures in the county of Funen, Denmark: Implications of demographic aging and changes in incidence rates. *Acta Orthop Scand.* 1983;54:681-6.
5. Hedlund R, Lindgren U. Trauma type, age, and gender

- as determinants of hip fracture. *J Orthop Res.* 1987;5:242-6.
6. Nieves JW, Bilezikian JP, Lane JM, Einhorn TA, Wang Y, Steinbuch M et al. Fragility fractures of the hip and femur: incidence and patient characteristics. *Osteoporos Int.* 2010;21(3):399-408.
  7. Dobbs RE, Parvizi J, Lewallen DG. Perioperative morbidity and 30 day mortality after intertrochanteric hip fractures treated by internal fixation or arthroplasty. *J Arthroplasty.* 2005;20(8):963-6.
  8. Palm H, Jacobsen S, Sonne-Holm S, Gebuhr P. Integrity of the lateral femoral wall in intertrochanteric hip fractures: an important predictor of a reoperation. *J Bone Joint Surg Am.* 2007;89:470-5.
  9. Boopalan PR, Oh JK, Kim TY, Oh CW, Cho JW, Shon WY. Incidence and radiologic outcome of intraoperative lateral wall fractures in OTA 31A1 and A2 fractures treated with cephalon-medullary nailing. *J Orthop Trauma.* 2012;26:638-42.
  10. Gotfried Y. The lateral trochanteric wall: a key element in the reconstruction of unstable pertrochanteric hip fractures. *Clin Orthop Relat Res.* 2004;8:2-6.
  11. Hsu CE, Shih CM, Wang CC, Huang KC. Lateral femoral wall thickness. A reliable predictor of post-operative lateral wall fracture in intertrochanteric fractures. *Bone Joint J.* 2013;95-B:1134-8.
  12. Egol KA, Kubiak EN, Fulkerson E, Kummer FJ, Koval KJ. Biomechanics of locked plates and screws. *J Orthop Trauma.* 2004;18(8):488-93.
  13. Babst R, Renner N, Biedermann M, Rosso R, Heberer M, Harder F, Regazzoni P. Clinical results using the trochanter stabilizing plate (TSP): the modular extension of the dynamic hip screw (DHS) for internal fixation of selected unstable intertrochanteric fractures. *J Orthop Trauma.* 1998;12(6):392-9.

**Cite this article as:** Shetty SH, Nagori AM, Paneliya MB, Sharma V, Patil DS, Shetty A. Functional outcome of intertrochanteric fractures treated with trochanteric stabilizing plates. *Int J Res Orthop* 2023;9:475-80.