

## Case Report

# Two rare cases of management of proximal phalanx spina ventosa

Neetin P. Mahajan, Tushar C. Patil\*, Sunny Sangma, Kartik P. Pande

Department Orthopaedics, Grant Government Medical College and Sir J. J. Group of Hospitals, Mumbai, Maharashtra, India

**Received:** 22 February 2023

**Revised:** 01 March 2023

**Accepted:** 04 March 2023

### \*Correspondence:

Dr. Tushar C. Patil,

E-mail: [tushar6919@gmail.com](mailto:tushar6919@gmail.com)

**Copyright:** © the author(s), publisher and licensee Medip Academy. This is an open-access article distributed under the terms of the Creative Commons Attribution Non-Commercial License, which permits unrestricted non-commercial use, distribution, and reproduction in any medium, provided the original work is properly cited.

### ABSTRACT

Tubercular dactylitis or spina ventosa is the tubercular infection of phalanges, metacarpals and metatarsals termed after cystic swelling of short tubular bones by tubercular infection. Here we presented two rare cases of spina ventosa in a 10 years old female and a 16 years old male patients. In both cases there was swelling of digits with stiffness. The radiographs were suggestive of chronic osteolytic infection with cortical destruction and diffuse sclerosis. We managed them with adequate surgical debridement, splintage and anti-tubercular therapy with good functional recovery. Spina ventosa or tubercular dactylitis is a rare condition and is often missed on diagnosis due to vague non-specific presentation, unavailability of rapid diagnostic tests and can be confused with other mimicking diseases. Any swelling over small tubular bones of hand or feet should raise the suspicion of spina ventosa, especially in endemic countries for tuberculosis. In neglected chronic infections, surgical debridement, curettage and splintage followed by anti-tubercular therapy based on histo-pathological reports is the treatment of choice with high protein diet and vitamin D supplementation ensures good outcome.

**Keywords:** Spina ventosa, Tubercular dactylitis, Tuberculosis, Tubular bones, Tubercular osteomyelitis

### INTRODUCTION

Tubercular dactylitis or spina ventosa is the tubercular infection of phalanges, metacarpals and metatarsals termed after cystic swelling of short tubular bones by tubercular infection.<sup>1</sup> Tuberculosis (TB) is one the most common infections of the developing countries with prevalence of extrapulmonary TB being 15-25%. Out of these skeletal TB cases accounted for 5%, of which spine TB is most common whereas tubercular dactylitis is considered of rare occurrence being upto 4%.<sup>2</sup>

There is frequent involvement of long bones with diffuse sclerosis of short tubular bones of hand and feet.<sup>3</sup> The diagnosis is often delayed owing to its insidious onset and gradual progress due to paucibacillary nature of organism. It can be often be confused with tumours which thus necessitate histopathological testing. In majority of cases, there is no evidence of any concomitant dormant or active

tubercular foci elsewhere in the body. In children, it usually occurs after an initial untreated tubercular pulmonary infection and are located in peripheral bone, in contrast to adults.<sup>2,3</sup> Initial plain radiographs are usually suggestive of simple cortical demineralization and osteoporosis with absence of periosteal reaction.<sup>2</sup> The lack of awareness among poor socio-economic strata with inadequate rapid diagnostic techniques and occasional inconclusive microbiological and histopathological reports delays the diagnosis even further. Long standing neglected cases then develop joint instability with discharging sinus formation.<sup>1</sup>

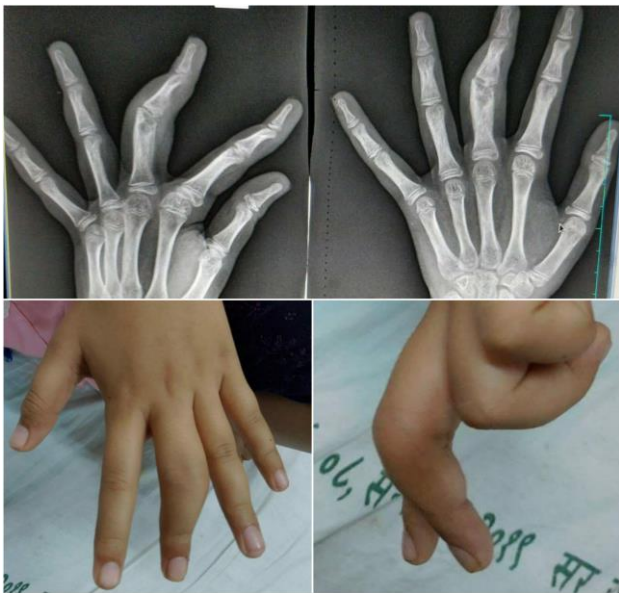### CASE REPORT

#### Case 1

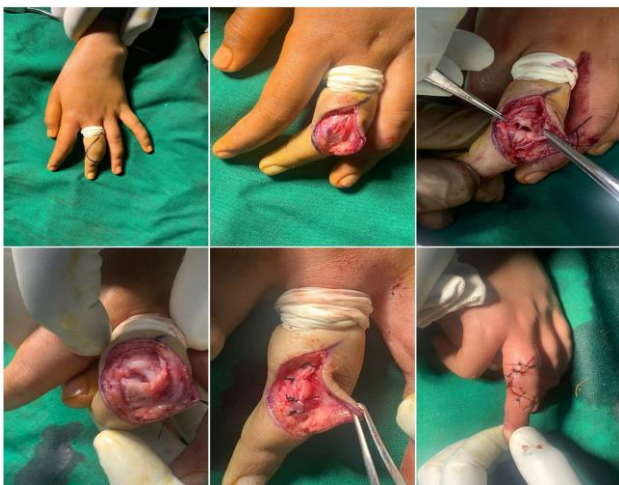A 10 years old female brought by parents to OPD with pain and swelling of left middle finger proximal phalanx since

3 months. There was no history of trauma. No history of TB or any constitutional symptoms. On examination there was diffuse swelling and tenderness over proximal phalanx of left middle finger with restricted range of motion of proximal interphalangeal joint with flexion upto 90 degrees and extension lag of 20 degrees.

On plain radiographs, a lytic lesion with corical destruction is seen in metaphysis of proximal phalanx of left middle finger with obliteration of proximal interphalangeal joint (Figure 1). Patient was operated by curved incision over dorsum of proximal interphalangeal joint. Soft tissue dissected and debridement of necrotic soft tissue with excision of sclerosed bone done. Soft tissue and skin closed in layers (Figure 2).

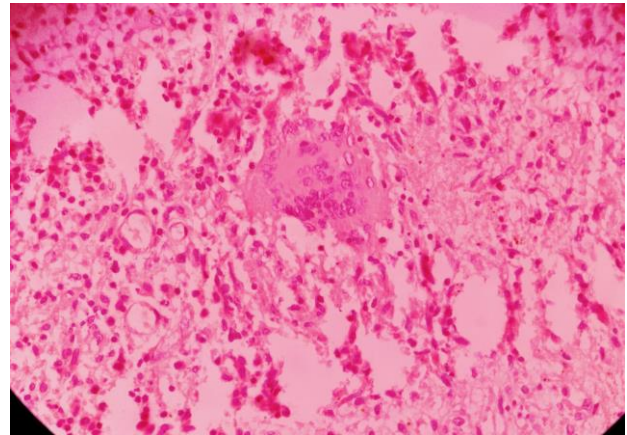


**Figure 1: Pre-operative X-rays and clinical pictures showing cystic lesion of proximal phalanx of left middle finger involving joint space.**

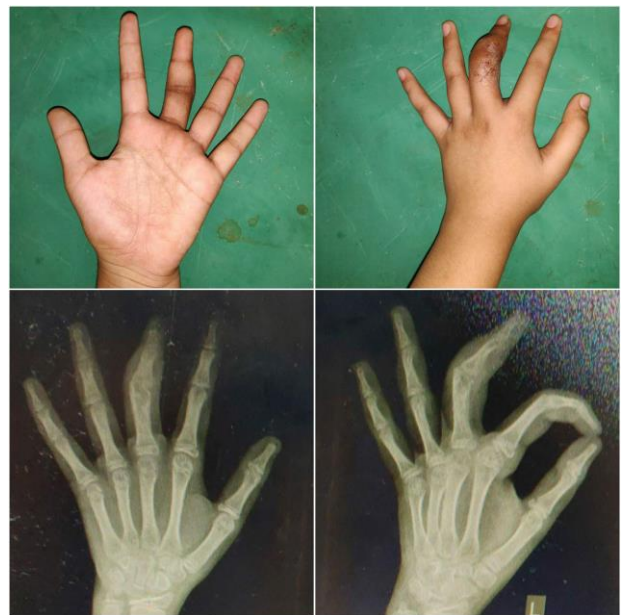

**Figure 2: Intra-operative pictures showing procedure of thorough debridement of involved bone and soft tissues.**

Intra-operative samples were sent for gram staining, tissue culture, gene xpert and histopathology. Cockup slab given postoperatively for 14 days. Anti-tubercular therapy started on basis of langerhans cells and epitheloid cells seen on histopathological reports (Figure 3). Patient started on high protein diet with vitamin-D3 supplementation. Suture removal done on post-operative day 21 which was found to be healthy (Figure 4).



**Figure 3: Histopathological slide showing caseation necrosis, epitheloid cells and Langerhan giant cells suggestive of tuberculous infection.**



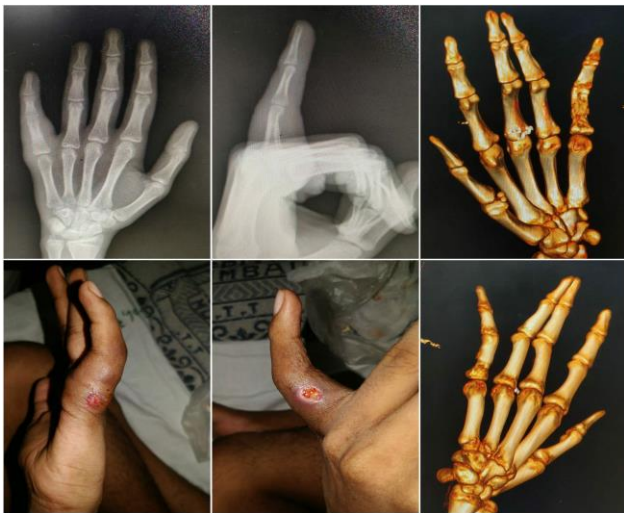**Figure 4: Clinical pictures and X-rays at 3 weeks post-operative.**

**Case 2**

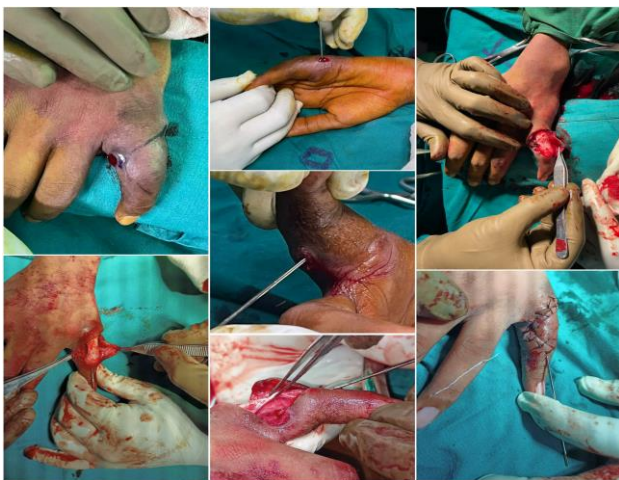
A 17 years old male brought by parents to OPD with pain and swelling of left little finger proximal phalanx since 3.5 months with pus discharging sinus since 2 weeks. There was no history of trauma. History of fever since 1 week. No history of TB contact. On examination there was diffuse swelling and tenderness over proximal phalanx of



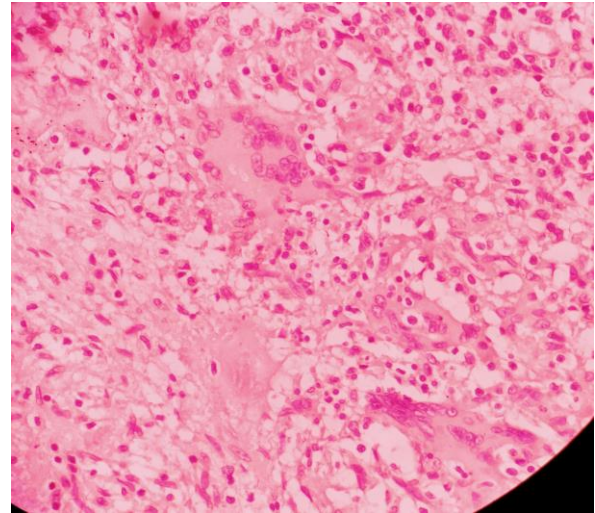
left little finger with restricted range of motion of proximal interphalangeal joint with flexion upto 100 degrees and extension lag of 30 degrees. On plain radiographs, a lytic lesion with corical destruction is seen in metaphysis of proximal phalanx of left little finger with reduction of proximal interphalangeal joint space (Figure 5). Patient was operated by curved incision over dorsum of proximal interphalangeal joint. Soft tissue dissected and debridement of necrotic soft tissue with excision of sclerosed bone done. Soft tissue and skin closed in layers (Figure 6). Intra-operative samples were sent for gram staining, tissue culture, gene xpert and histopathology. Cockup slab given postoperatively for 14 days. Anti-tubercular therapy started on basis of langerhans cells and epitheloid cells seen on histopathological reports (Figure 7). Patient started on high protein diet with vitamin-D3 supplementation. Suture removal done on postoperative day 21 which was found to be healthy (Figure 8).



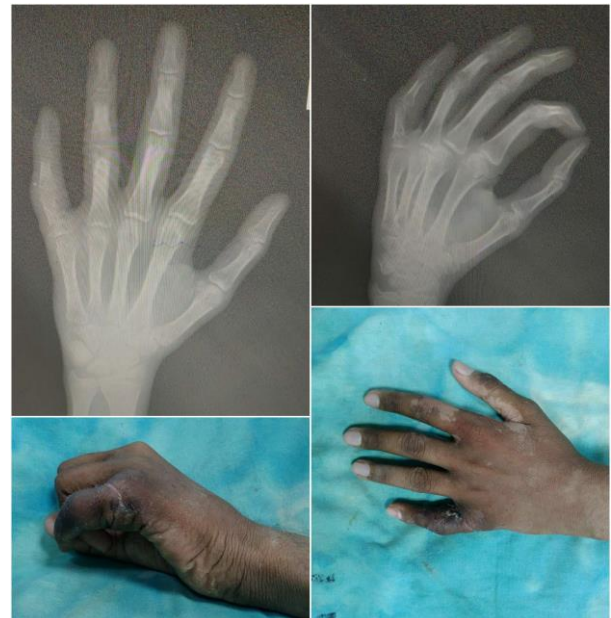**Figure 5: Pre-operative clinical pictures, X-rays and 3D CT showing sinus tract from proximal phalanx of left little finger.**



**Figure 6: Intra-operative pictures showing procedure of thorough debridement of involved bone and soft tissues.**



**Figure 7: Histopathological slide showing caseation necrosis, epitheloid cells and Langerhan giant cells suggestive of tuberculous infection.**



**Figure 8: Clinical pictures and X-rays at 3 weeks post-operative.**

## DISCUSSION

Bone infection caused by mycobacterium tuberculosis is disseminated from distant locus of infection through blood stream. Spina ventosa is most commonly seen in children less than 10 years of age due to formation of epiphyseal centres by 6 years which limits the spread of hematogenous infection from invading the immature metaphyseal bone. This leads to formation of fusiform swelling of tubular bones with thinned out cortex. The expansile granulation tissues leads to radioluscent marrow space.<sup>4,5</sup> It usually involves single tubular bones more commonly of hand. Concurrent constitutional symptoms like fever, weight loss, night sweats and loss of appetite

are seen uncommonly in less than one fifth patients. It becomes symptomatic usually by 2-3 years of initial infection.<sup>4,5</sup>

In hand, tuberculous infection is commonly seen in second metacarpal, proximal phalanx of middle, ring and index fingers and first metacarpal. There is slight male preponderance. The presenting complaint is commonly a painless swelling with restricted range of motion. Low socio-economic status, malnourishment, vitamin D deficiency, HIV infection predisposes to tubercular infection.<sup>1</sup> There are a variety of differential diagnosis which mimic tubercular dactylitis ranging from non-infectious granulomas to chronic pyogenic infections to metabolic endocrinopathies like hyperthyroidism to benign tumours like osteoid osteoma, fibrous cortical defect, giant cell tumour or aneurysmal bone cyst to malignant tumors like ewings sarcoma, osteosarcoma, eosinophilic granulomas and kaposi sarcoma. This causes further delay in diagnosis.<sup>1</sup>

In children and young adults, spina ventosa commonly spares neighbouring joints.<sup>6</sup> Erythrocyte sedimentation rate and test for C reactive proteins are adjunctive in monitoring treatment response. Clinical improvement along with repeat radiological assessment is the key.<sup>4</sup> In 1886, Rankin described histopathological findings of spina ventosa in children followed by Feilchenfeld who explained radiological findings of spina ventosa in children in 1896.<sup>7</sup>

On MRI scans, infected areas appear as hypointense on T1 weighted images and hyperintense on T2 weighted images providing good contrast between healthy and diseased marrow. Heterogenicity on T2 weighted images gives an idea about caseous liquefaction. The hyperintense ring like lesion in periphery and decreased signal intensity in the centre is the usual finding. MR imaging also provides information regarding infiltration of surrounding soft tissues like tendons and muscles which may need debridement along with bony curettage. It precisely delineates course of sinus tract. A lytic expansile lesion with cortical destruction should always raise the suspicion of tubercular infection.<sup>6</sup> The appearance of Langerhan giant cells and epitheloid cells with granulomatous inflammation and caseous necrosis on histopathological testing of bone biopsy samples is diagnostic of tuberculous infection.<sup>2</sup> Spontaneous complete healing of the bone lesions is the rule for cure. Tubercular osteomyelitis should be treated with anti-tubercular therapy for a minimum of 9 months as stated by WHO.<sup>4</sup> Anti-tubercular chemotherapy with isoniazid, rifampicin, pyrazinamide and ethambutol for 2 months followed by isoniazid and rifampicin for 10 months is the first line of management with splintage for 3-4 weeks.<sup>8</sup>

Surgical debridement and curettage plays a vital role in gross bony lesions with avascular sequestrum and discharging cloaca, where anti tubercular medications alone won't be sufficient.<sup>4</sup>

## CONCLUSION

Spina ventosa or tubercular dactylitis is a rare condition and is often missed on diagnosis due to vague non-specific presentation, unavailability of rapid diagnostic tests and can be confused with other mimicking diseases. Any swelling over small tubular bones of hand or feet should raise the suspicion of spina ventosa, especially in endemic countries for tuberculosis. In neglected chronic infections, surgical debridement, curettage and splintage followed by anti-tubercular therapy based on histopathological reports is the treatment of choice with high protein diet and vitamin D supplementation ensures good outcome.

*Funding: No funding sources*

*Conflict of interest: None declared*

*Ethical approval: Not required*

## REFERENCES

1. Ali N, Bhat A, Fatima A, Muzzafar K, Lato IA, Singh R. Tuberculous Dactylitis: A Case Series and Review of Literature. *J Pioneering Med Sci.* 2014;4(4).
2. Sbai MA, Benzarti S, Sahli H, Sbei F, Maalla R. Osteoarticular tuberculosis dactylitis: Four cases. *Int J Mycobacteriol.* 2015;4(3):250-4.
3. Nguyen Ngoc S, Nguyen Thai H, Vu Van Q, Vu Tung L, Nguyen Ngoc R, et al. Late Discovering Spina Ventosa: A Case Report. *Int Med Case Rep J.* 2021;14:449-53.
4. Ritz N, Connell TG, Tebruegge M, Johnstone BR, Curtis N. Tuberculous dactylitis--an easily missed diagnosis. *Eur J Clin Microbiol Infect Dis.* 2011;30(11):1303-10.
5. Senthil V, Acharya A. Spina Ventosa in a Young Adult: Report of Two Cases. *J Case Rep.* 2016;6(3):444-8.
6. Yoon CJ, Chung HW, Hong SH, Kim CJ, Kang HS. MR findings of tuberculous dactylitis: case report. *Eur J Radiol.* 2001;39(3):163-7.
7. Hassan FO. Tuberculous dactylitis pseudotumor of an adult thumb: a case report. *Strategies Trauma Limb Reconstr.* 2010;5(1):53-6.
8. Sahli H, Roueched L, Sbai MA, Bachali A, Tekaya R. The epidemiology of tuberculous dactylitis: A case report and review of literature. *Int J Mycobacteriol.* 2017;6(4):333-5

**Cite this article as:** Mahajan NP, Patil TC, Sangma S, Pande KP. Two rare cases of management of proximal phalanx spina ventosa. *Int J Res Orthop* 2023;9:607-10.