

Original Research Article

Titanium elastic nailing for paediatric femoral shaft fractures: a prospective descriptive study

Santosh^{1*}, Shams Gulrez²

¹Department of Orthopaedics, Shimoga Institute of Medical Sciences, Shimoga, Karnataka, India

²Department of Orthopaedics, RIMS, Imphal, Manipur, India

Received: 28 January 2017

Accepted: 24 February 2017

*Correspondence:

Dr. Santosh,

E-mail: santosh2ortho@gmail.com

Copyright: © the author(s), publisher and licensee Medip Academy. This is an open-access article distributed under the terms of the Creative Commons Attribution Non-Commercial License, which permits unrestricted non-commercial use, distribution, and reproduction in any medium, provided the original work is properly cited.

ABSTRACT

Background: Femoral shaft fracture is the most common major paediatric orthopaedic fractures. For generations traction and casting was the standard treatment for all femoral shaft fractures in children. Over the past two decades the advantages of fixation and rapid mobilisation have been increasingly recognised. Aim: To assess the functional and clinical outcome after closed reduction and internal fixation with titanium elastic nail in diaphyseal femoral fractures between 5 to 16 years.

Methods: The study was conducted in the Department of Orthopaedic Surgery, Regional Institute of Medical Sciences (RIMS), Imphal, Manipur, from September 2013 to April 2015. Thirty children (20 boys and 10 girls) in the age group of 5 to 16 years with recent femoral diaphyseal fractures were stabilised by titanium elastic nails [TENS]. Results were evaluated according to Flynn's scoring criteria.

Results: After 25 months of follow up all thirty patients were available for evaluation. Radiological union were achieved in a mean time of 11.5 weeks. Mean duration of hospital stay was 15.23 days. According to Flynn's criteria of TENS outcome score results were excellent in 66.7% patients, Satisfactory in 30% patients, Poor in 3.3% patient. All patients had early return to school. Per operative technical problems included failure of closed reduction in 2 cases.

Conclusions: Titanium elastic nailing is an effective treatment in diaphyseal fractures of femur in properly selected patients.

Keywords: TENS, Femoral fracture, Intramedullary nailing, ESIN

INTRODUCTION

Femoral fractures are among common injuries in the paediatric age group treated by an orthopaedic surgeon. These fractures typically occur either in early childhood when weak woven bone is changing to the stronger lamellar bone or during adolescence when children are subject to high-energy trauma from motor vehicle accidents or from sports.¹ Femoral shaft fractures represent approximately 1.6% of all bony injuries in children.²

Most of the femoral fractures in children less than 5 years are treated by conservative methods and children more than 16 years with intramedullary nailing. As far as the children with femoral shaft fractures in the age group of 6 to 16 years concerned there is controversy which is unsolved since several decades with several available treatment options: traction followed by hip spica, intramedullary nailing, external fixation, flexible stable intramedullary nails and plate fixation. Whatever the method of treatment, the goals should be to stabilise the fracture, to maintain length and alignment, to promote

bone healing, and to minimise the morbidity and complications for the child and his/her family.³

Metaizeau and the team from Nancy, France, developed the technique of elastic stable intramedullary nailing (ESIN) using titanium nails in 1982. Titanium elastic nails are minimally invasive, minimally traumatizing, stable under movement and partial loadbearing, biological and child friendly osteosynthesis.⁴

Titanium nails are inserted above the level of physis thereby avoiding damage to the physis avoiding growth disruption. The biomechanical principal of the titanium elastic nail (TEN) is based on the symmetrical bracing action of two elastic nails inserted into the metaphysis, each of which bears against the inner bone at three points.^{5,6} early immediate stability to the involved bone segment, early mobilization and return to the normal activities of the patients, with very low complication rate are the salient features of TENS.^{7,8}

Aim

Aim of the study was to assess the functional and clinical outcome after closed reduction and internal fixation with titanium elastic nail in diaphyseal femoral fractures between 5 to 16 years.

METHODS

This was a prospective descriptive study conducted in the Department of Orthopaedic Surgery, Regional Institute of Medical Sciences (RIMS), Imphal, Manipur. Study was done in all children between 5-16 years of age irrespective of sex with diaphyseal fractures of femur meeting the inclusion and the exclusion criteria. Only those children's were included who were between 5 – 16 years of age, had closed fracture of diaphysis of the femur and Patients where follow up of 6 months is possible. Metaphyseal fractures, open fractures, pathological fractures, fractures with head injury were excluded from the study.

Ethical approval was taken from Institution Ethical Committee, RIMS Imphal, Manipur. Informed consent was taken from all participants. Patients coming RIMS casualty with fracture shaft of femur after initial vitals stabilization fracture was immobilized with skin traction and thomas splint. plain radiographs of AP and lateral views of thigh including hip and knee joints was taken to assess the extent of fracture comminution, geometry and the dimensions of the fracture. Nail size was calculated by measuring the diameter of isthmus and it's calculated by Flynn et al's formula.⁹

Diameter of nail= width of the narrowest point of the medullary canal on Antero-posterior and lateral view X 0.4mm (Figure 1).

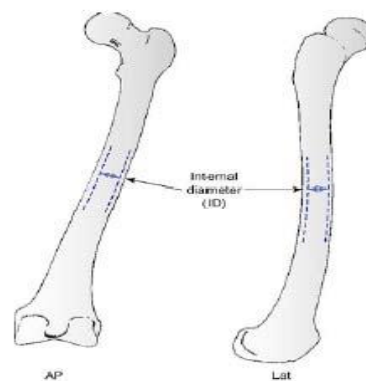


Figure 1: Measuring the size of the nail such that both the nails occupy 80 percent of the medullary cavity (as calculated by Flynn's formula).

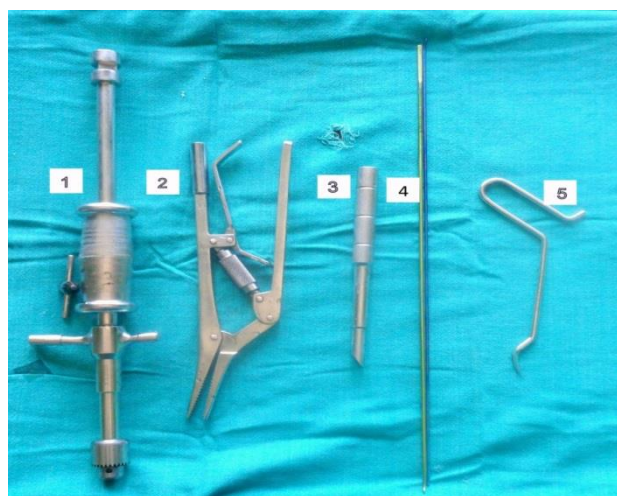

Figure 2: Instruments required.

Instruments required (Figure 2):

1. Inserter-synthes (product number:359.219) with hammer guide- synthes (product number:359.218)
2. Lock pliers-synthes (product number:359.204)
3. Bevelled tamp-synthes (product number:359.206)
4. Titanium elastic nails
5. Bone awl-synthes (product number:359.213)

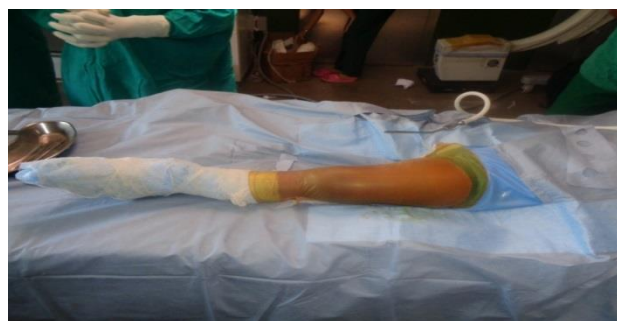

Figure 3: Completely draped after painting.

After admission to ward all routine investigations were done and patients were operated as early as possible once the patient became fit for surgery. Preoperative sliding skin traction applied to fractures more than one week to avoid intraoperative difficulty in reduction. Operation was carried out in general/spinal anaesthesia. A systemic antibiotic, usually a 3rd generation cephalosporin was administered just before induction of patients by anaesthetists. After placing the patient supine on a radiolucent table, thigh is painted and draped (Figure 3). Traction table was used in older children. Preliminary reduction was done and checked under IITV. Femoral reduction instrument (F tool) was used in older children or in an old fracture. Physis of the femur was identified by fluoroscopy and the location was marked on the skin. A 2 to 2.5 cm longitudinal skin incision was made over the medial and lateral surface of the distal femur, starting 2 cm proximal to the distal femoral epiphyseal plate. Using a bone awl small hole is made which is entered at an acute angle into medullary cavity (Figure 4). Then propersize nail is selected which is pre bent 3 times of the required curvature with maximum convexity at the fracture site. Nail was loaded on the T handle and advanced through the entry point by twisting movements until it reaches the fracture site (Figure 5). Then second nail introduced from the other side and passed through the fracture site simultaneously. Proximal extent of the nail is confirmed by IITV (Figure 6). The tips of the nail that entered the lateral femoral cortex were made to come to rest just distal to the trochanteric epiphysis. The opposite nail was also made to lie at the same level towards the calcar region; too short nails were avoided. Distally nails were cut so that 1cm of nail remains outside the cortex. In all cases same sized nail was used and maximum possible diameter of the nail was used.

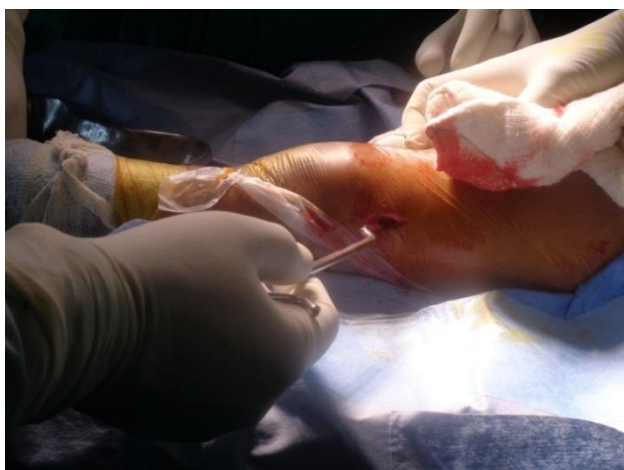

Figure 4: Entry point being made with bone awl.

Postoperatively patients were encouraged quadriceps strengthening exercises as soon as the pain subsides and partial weight bearing allowed depending on the stability of fracture and callus formation. Assessments were done at 2, 6, 12 and 24 week. The final outcome based on the

above observations was done as per Flynn's criteria (Table 1).¹⁰

Table 1: Flynn's criteria: TENS outcome score.

Results	Excellent	Satisfactory	Poor
Variables at 24 weeks			
Limb-length inequality	< 1.0 cm	< 2.0 cm	>2.0 cm
Malalignment	5 degrees	10 degrees	>10 degrees
Unresolved pain	Absent	Absent	Present
Other complications	None	Minor and resolved	Major and lasting

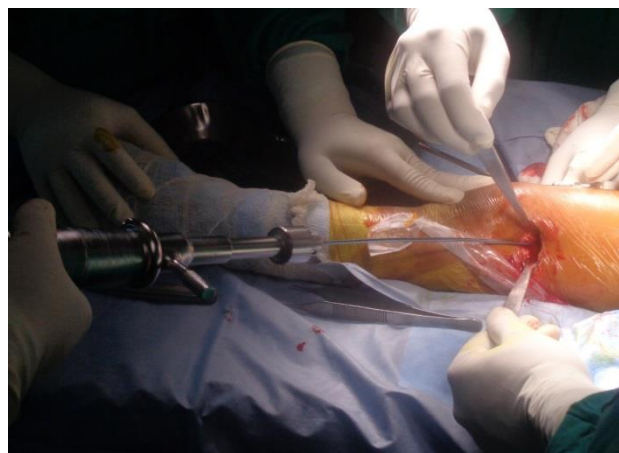

Figure 5: Entering the nail in the hole made by bone awl.

Excellent: When there was anatomical or near anatomical alignment, no leg length discrepancy with no preoperative problems.

Satisfactory: When there was acceptable alignment and leg length with resolution of preoperative problems.

Poor: In the presence of unacceptable alignment or leg length with unresolved preoperative problems.

RESULTS

The study was done in the Department of Orthopaedics, Regional Institute of Medical Sciences, Imphal, during the period from September 2013 to August 2015. A total of 30 patients were randomly selected. No patients were lost to follow-up. In the present study 15 (50%) of the patients were 5-8 years, 13 (43.3%) were 9 to 12 years and 2(6.7%) were 13 to 16 years age group with the average age being 9 years. There were 10 (33.3%) girls and 20 (66.7%) boys in the present study. In the present study RTA was the most common mode of injury (40%).

Self-fall accounted for 36.7% and fall from height for 23.3%. In 60% of the patients right side was affected. In our study, transverse fractures accounted for 16 (53.3%) cases, communitated fractures- 2 (6.7%), oblique fractures – 9 (30%), spiral fractures – 3 (10%) and there were no segmental fractures. Fractures involving the middle 1/3rd accounted for 18 (60%) cases, proximal 1/3rd – 7 (23.3%) and distal 1/3rd – 5 (16.7%) of cases in our study. In the present series, 4 (13.3%) patients underwent surgery within 2 days after trauma, 9 (30%) in 3 – 4 days and 17 (56.7%) after 5 days. Duration of surgery was < 30 mins in 1(3.3%) case, 30- 60 mins in 10 (33.3%) cases, 61-90 mins in another 14 (46.7%) cases and 91-120 mins in 5 (20%) of the cases (Table 2).

Table 2: The demographic and clinical characteristics of subjects (n=30).

Clinical variables	Total number of patients (n=30)
Age in years	
5-8	15(50%)
9-12	13(43.3%)
13-16	2(6.7%)
Gender	
Male	20(66.7%)
Female	10(33.3%)
Mode of Injury	
RTA	12(40%)
Fall	11(36.7%)
Fall from height	7(23.3%)
Pattern of fracture	
• Transverse	16(53.3%)
• Oblique	9(30%)
• Spiral	3(10%)
• Segmental	0(0%)
• Communitated	2(6.7%)
Time interval between trauma & surgery	
• < 2days	4(13.3%)
• 3-4 days	9(30%)
• 5-7 days	17(56.7%)

In our study union was achieved in <3 months in 23 (76.7%) of the patients and 3 – 4.5 months in 6 (20%). Average time to union was 11.5 weeks. Unsupported full weight bearing walking was started in <12 weeks for 24 (80%) of the patients, between 12 and 18 weeks in 5 (16.7%) and at 20 weeks in 1 (3.3%) patient. The average time of full weight bearing was 11.5 weeks. One patient had major complication required second operation and 10 patients had minor complication (Table 3).

Results were excellent in 66.7% patients, Satisfactory in 30% patients, Poor in 3.3% patient (Figure 6).

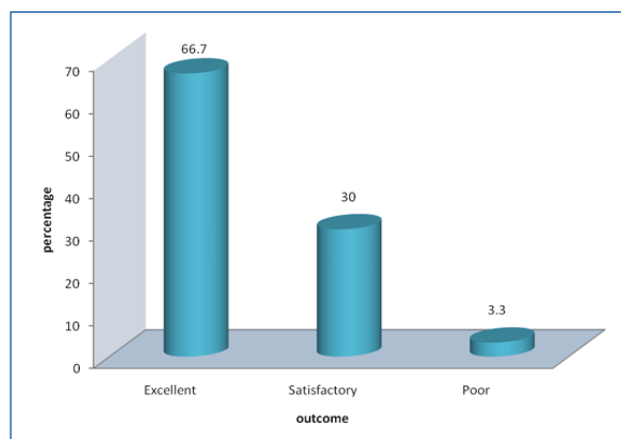


Figure 6: Outcome of the study.

Table 3: The clinical outcome: post-operative minor complications (n=30).

Complications	No. of cases (percentage)
Pain	6(20%)
Infection	
• Superficial	0(0%)
• deep	
Inflammatory reaction	0(0%)
Delayed union and non-union	0(0%)
Limb lengthening	
• < 2 cm	1(3.3%)
• >2 cm	
Limb shortening	
• < 2 cm	1(3.3%)
• >2 cm	
Sinking of the nail into the medullary cavity	1(3.3%)
Mal alignment	
• Varus angulation	1(3.3%)
• Valgus angulation	
• Anterior angulation	
• Posterior angulation	
• Rotational malalignment	
Loss of reduction requiring new reduction or surgery	1(3.3%)

DISCUSSION

In the present study average age being 9 years. Flynn JM et al in their study assessing 49 cases of children ranged from 6-16 years with a mean age of 10.2 years.¹¹ Ramachandra et al studied children ranged from 9-12 years with a mean of 10.2 years.¹² Saikia et al studied children from 6-16 years with a mean of 10.8 years.² There were 10 (33.3%) girls and 20 (66.7%) boys in the present study.

The sex incidence is comparable to other studies in the literature. Moroz et al in their study there were 171(74.7%) males and 58(25.3%) females.¹³ Bhaskar et al in their study out of 60 patients there were 38 (63.4) boys and 22 (36.6) girls.¹⁴ In the present study RTA was the most common mode of injury accounting for 11 (40%) cases, self-fall accounted for 11 (36.7%) cases and fall from height accounted for 7 (23.3%) of the cases. Flynn et al in their study assessing 234 cases, 136(58.1%) were following RTAs, 46 (19.6%) were following self-fall and remaining 43 (28.8%) were as a result of fall from height.⁹ Bandyopadhyay et al in their study of 70 patients 42 patients (60%) the mechanism of injury was due to motor vehicle accident, 22 (31.42%) were due to fall from height while remaining 4 (8.58%) were due to sports injury.¹⁵ The average duration of surgery in our study was 69.6 minutes. In Singh et al study, the average duration of surgery was 63 minutes.¹⁶ In a study by Saikia et al the duration of surgery ranged from 50 – 120 minutes with a median of 70 minutes.²

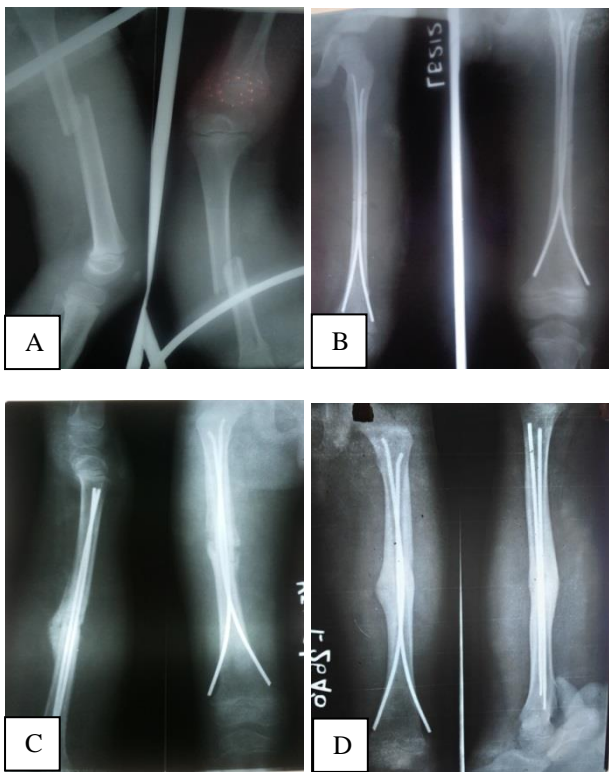


Figure 7: A-Preoperatively, B- Postoperatively, C- Postoperatively 6 weeks, D- Postoperatively 12 weeks.

The duration of stay in the hospital ≤ 7 days for 1 (3.3%) patients, 8-10 days for 6 (20%), 11-15 days for 11 (36.7%) and 12 (40%) patients stayed for more than 15 days. One patient was operated 1 month after injury (admission) that stayed for 60 days because she required a reoperation due to implant failure. The average duration of hospital stay in the present study is 15.23 days. Average hospitalization time was 12.5 days in the study conducted by Singh et al.¹⁶ The mean hospital stay was

10 days in Singh et al study.¹⁷ Gross et al conducted a study on cast brace management of the femoral shaft fractures in children and young adults.¹⁸ The average length of hospitalization in their study was 18.7 days. Compared to the above studies conducted on conservative methods and cast bracing, the average duration of hospital stay was less in our study i.e. 13.69 days. The reduced hospital stay in our series is because of proper selection of Patients, stable fixation and fewer incidences of complications.

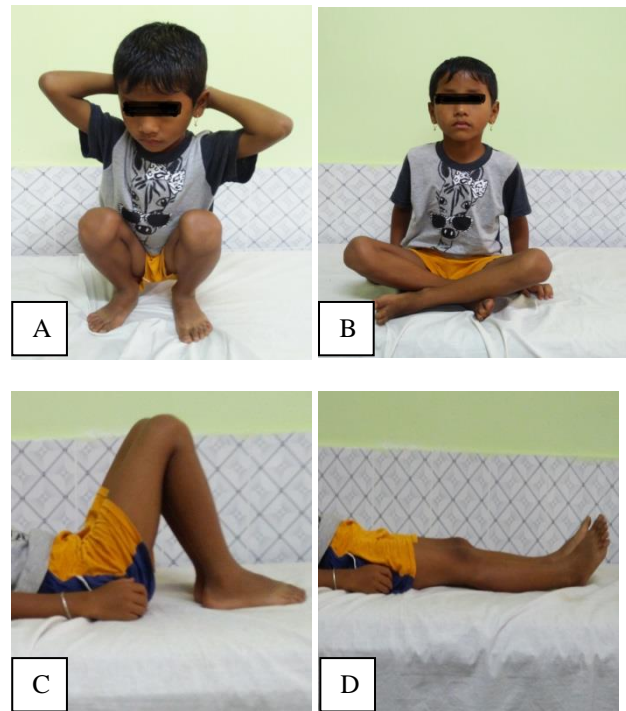


Figure 8: A- Squatting, B- Sitting cross legged, C- Flexion, D- Extension.

Average time to union was 11.5 weeks. Saikia et al reported average time for union as 8.7 weeks.² Bhaskar et al in their study average time to union was 12 weeks femur.¹⁴ In our study, closed reduction of the fracture, leading to preservation of fracture hematoma, improved biomechanical stability and minimal soft tissue dissection led to rapid union of the fracture compared to compression plate fixation. The average time of full weight bearing was 11.5 weeks. Saikia et al in their study allowed full weight bearing was at average of 8.8 weeks.² Singh et al in their study allowed full weight bearing depending on the clinical and roentgenographic progress of fracture union with an average time of 8.3 weeks.¹⁶

In the present study, 6 (20%) patients had developed pain at site of nail insertion during initial follow up evaluation which resolved completely in all of them by the end of 16 weeks. Flynn et al reported 38 (16.2%) cases of pain at site of nail insertion out of 234 fractures treated with titanium elastic nails.⁹ This is the most common sequel after femoral shaft fractures in children and adolescents. One (3.33%) patient had shortening (1 cm) and one

(3.33%) had lengthening (1.2 cm). No patient in our study had major limb length discrepancy (i.e. $> \pm 2$ cm). Khazzam et al reported, three patients had overgrowth of more than 2 cm.¹⁹ Ferguson et al noted more than 2 cm shortening in 4 children after spica treatment of pediatric femoral shaft fracture.²⁰ In the present study, limb length discrepancy of more than 10mm was present in 2 (10%) cases. Comparing to limb length discrepancy in conservative methods, limb length discrepancy in our study was within the acceptable limits. One (3.33%) patient presented with varus (4°) angulation. Flynn et al reported 10 (4.3%) cases of minor angulation out of 234 fractures treated with titanium elastic nails.⁹ Singh et al reported angulation in both anteroposterior and varus/valgus planes was seen in two cases and one case, in which two different diameter nails had to be used, had posterior bowing of 10° and 10° of varus tilt.¹⁶ Herndon et al compared the results of femoral shaft fractures by spica casting and intramedullary nailing in adolescents.²¹ They noticed varus angulation ranging from 7 to 25° in 4 patients treated with spica casting and no varus angulation in surgical group. A difference of more than 10° has been the criterion of significant deformity. No patient in our study had significant rotational deformity.

In the present study, the final outcome was excellent in 20 (66.7%) cases, satisfactory in 9 (30%) cases and there was one patient had poor outcome (Table 5). Flynn et al treated 234 femoral shaft fractures and the outcome was excellent in 150 (65%) cases, satisfactory in 57 (25%) cases and poor in 23 (10%) of the cases.⁹ Singh et al treated 112 patients of femoral fractures, 86 had excellent results, 24 had satisfactory results, and 2 had poor results.¹⁷ Saikia et al in their study of 22 children with femoral diaphyseal fractures reported 13 (59%) excellent, 6 (27.2%) satisfactory and 3(13.6%) poor results.² Singh et al treated 35 fractures and outcome was excellent in 25 (71.4), satisfactory in 8 (22.8) and poor in 2 (5.8) patients.¹⁶

CONCLUSION

Based on our research findings and results, we conclude that elastic stable intramedullary nailing (ESIN) technique is an ideal method for treatment of femoral diaphyseal fractures in the children in the age group of 5 to 16 years. It is a simple, easy, rapid and effective method for management of paediatric femoral fractures with reasonable time to bone healing. Use of ESINs for definitive stabilization of femoral shaft fractures in children is a reliable, minimally invasive, and physal-protective treatment method.

Funding: No funding sources

Conflict of interest: None declared

Ethical approval: The study was approved by the institutional ethics committee

REFERENCES

- Viljanto J, Linna MI, Kiviluoto H, Paananen M. Indications and results of operative treatment of femoral shaft fractures in children. *Acta Chir Scand.* 1975;141(5):366-9.
- Saikia KC, Bhuyan SK, Bhattacharya TD, Saikia SP. Titanium elastic nailing in femoral diaphyseal fractures of children in 6-16 years of age. *Indian J Orthop.* 2007;41(4):381-5.
- El-Adl G, Mostafa MF, Khalil MA, Enan A. Titanium elastic nail fixation for paediatric femoral and tibial fractures. *Acta Orthop Belg.* 2009;75(4):512-20.
- Ligier JN, Metaizeau JP, Prevot J. Closed flexible medullary nailing in paediatric traumatology. *Chir Pediatr.* 1983;24:383-5.
- Li Y, Stabile KJ, Shilt JS. Biomechanical analysis of titanium elastic Nail fixation in a pediatric femur fracture model. *J Pediatr Orthop.* 2008;28(8):874-8.
- Mahar A, Sink E, Faro F, Oka R, Newton PO. Differences in biomechanical stability of femur fracture fixation when using titanium nails of increasing diameter. *J Child Orthop.* 2007;1(3):211-5.
- Pogorelic Z, Furlan D, Biocic M, Juric I, Budimir D, Todoric J, et al. Titanium intramedullary nailing for treatment of simple bone cysts of the long bones in children. *Scott Med J.* 2010;55(3):35-8.
- Wall EJ, Jain V, Vora V, Mehlman CT, Crawford AH. Complications of titanium and stainless steel elastic nail fixation of pediatric femoral fractures. *J Bone Joint Surg Am.* 2008;90(6):1305-13.
- Flynn JM, Skaggs DL, Sponseller PD, Ganely TJ, Kay RM, Kellie Leitch KK. The operative management of pediatric fractures of lower extremity. *J Bone Joint Surg Am.* 2002;84:2288-300.
- Flynn JM, Hresko T, Reynolds RA, Blaiser RD, Davidson R, Kasser J. Titanium elastic nails for pediatric femur fractures: a multicenter study of early results with analysis of complications. *J Pediatr Orthop.* 2001;21(1):4-8.
- Flynn JM, Luedtke LM, Ganly TJ, Dawson J, Davidson R, Dormans JP, et al. Comparison of Titanium Elastic Nails with Traction and a Spica Cast to Treat Femoral Fractures in Children. *J Bone Joint Surg Am.* 2004;86(4):770-8.
- Ramachandra K, Virupaksha Reddy SP, Gahlowt A, Akshay SD, Javali V, et al. A prospective study of management of pediatric femoral diaphyseal fractures using intramedullary titanium elastic nails. *Int J Res Health Sci.* 2015;3(1):11-7.
- Moroz L, Launay F, Kocher MS, Newton PO, Frick SL, Sponseller PD, et al. Titanium elastic nailing of fractures of the femur in children: predictors of complications and poor outcome. *J Bone Joint Surg Br.* 2006;88(10):1361-6.

14. Bhasker A. Mumbai treatment of long bone fractures in childrens by titanium elastic nailing. *Ind J Orthop.* 2005;39(3):166-8.
15. Bandyopadhyay R, Mukherjee A. Short Term Complications of Titanium Elastic Nail in the Treatment of Diaphyseal Fracture of the Femur in Children. *Open Orthop J.* 2013;7:12-7.
16. Singh R, Sharma SC, Magu NK, Singla A. Titanium elastic nailing in pediatric femoral diaphyseal fractures. *Ind J Orthop.* 2006;40(1):29-34.
17. Singh P, Kumar R. Pediatric femoral shaft fracture management by titanium elastic nailing; a prospective study of 112 patients. *The Internet J of Ortho Sur.* 2012;19(3):1-7.
18. Gross RH, Davidson R, Sullivan JA, Peeples RE, Hufft R. Cast brace management of the femoral shaft fracture in children and young adults. *J Pediatr Orthop.* 1983;3(5):572-82.
19. Khazzam M, Tassone C, Liu XC, Lyon R, Freeto B, Schwab J, et al. Use of Flexible Intramedullary Nail Fixation in Treating Femur Fractures in Children. *Am J Orthop.* 2009;38(3):49-55.
20. Ferguson J, Nicol RO. Early spica treatment of pediatric femoral shaft fractures. *J Pediatr Orthop.* 2000;20(2):189-92.
21. Herndon WA, Mahnken RF, Yngve DA, Sullivan JA. Management of femoral shaft fractures in the adolescent. *J Pediatr Orthop.* 1989;9(1):29-32.

Cite this article as: Santosha, Gulrez S. Titanium elastic nailing for paediatric femoral shaft fractures: a prospective descriptive study. *Int J Res Orthop* 2017;3:501-7.