

## Case Report

# Modified dual osteotomy for Madelung's deformity

Aditya Agarwal<sup>1</sup>, Rahul Patel<sup>1\*</sup>, Mohit Jain<sup>1</sup>, Shubham Arora<sup>1</sup>, Paresh Golwala<sup>1</sup>,  
Srishty Agarwal<sup>2</sup>

<sup>1</sup>Department of Orthopedics, Sumandeep Vidhyapeeth, Vadodara, Gujarat, India

<sup>2</sup>New civil hospital, Surat, Gujarat, India

**Received:** 27 October 2022

**Revised:** 19 December 2022

**Accepted:** 17 January 2023

**\*Correspondence:**

Dr. Rahul Patel,

E-mail: [drnrportho@gmail.com](mailto:drnrportho@gmail.com)

**Copyright:** © the author(s), publisher and licensee Medip Academy. This is an open-access article distributed under the terms of the Creative Commons Attribution Non-Commercial License, which permits unrestricted non-commercial use, distribution, and reproduction in any medium, provided the original work is properly cited.

### ABSTRACT

Madelung's deformity is one of the rare congenital deformities of the forearm and wrist, typically seen as positive ulnar variance and increased volar tilt due to the "Vickers" ligament. Different corrective surgical methods for this have been done in the literature. In this case of a 9-year-old Madelung's like deformity, we have performed a modified dual osteotomy with periosteal preservation allowing natural articulation and bone to be modified, especially in a younger child. This article gives the surgical option to orthopedics for the future, especially in a younger child with severe deformity. This is a level V evidence-based therapeutic study.

**Keywords:** Madelung's deformity, Congenital hand deformity, Osteotomy, Newer modality

### INTRODUCTION

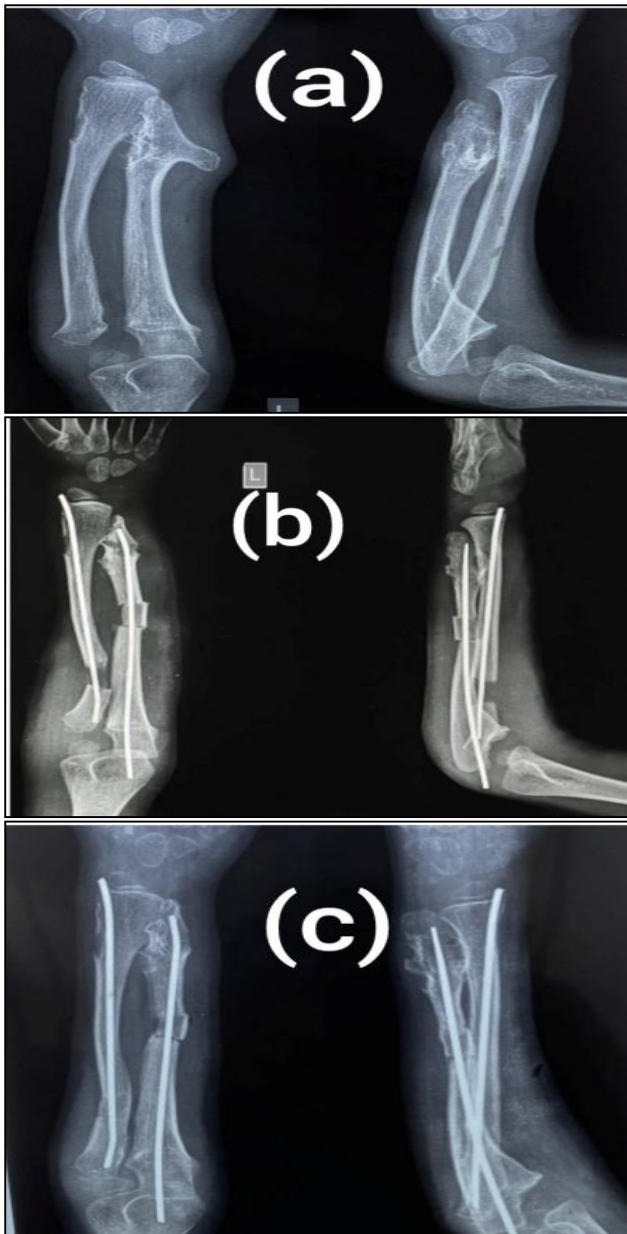
Madelung's deformity of the wrist was first described by Otto Madelung in 1878 and includes a spectrum of deformities causing the shortening of one or both bones of the forearm. It is seen mainly in the age group of 8 to 14 years, more common in females (4:1), and is often bilateral. The exact etiology of this deformity is not known. However, Herry and Thorburn have divided it into four different groups: 1) Idiopathic or primary 2) secondary to trauma, infection or tumor 3) dysplastic conditions like Ollier's disease 4) genetic conditions like Turner syndrome.<sup>1</sup>

Furthermore, typical Madelung's deformity can be identified from others by the presence of the "Vickers" ligament, an abnormally short, volar, radioulnar ligament, which interferes with distal radioulnar growth leading to increased volar tilt and increased inclination of radial articulation surface. This positive ulnar variance makes painful wrist joint movement, which is the major cause of presentation.

Many cases have been published of typical Madelung's deformities, but very few have been published on Madelung's like deformities. We have performed a dual osteotomy of the radius and ulna with periosteal preservation and fixation subsequently in a 9-year-old male child in a case of Madelung's type of deformity, who presented to us with a complaint of pain and deformity in the left forearm.

### CASE REPORT

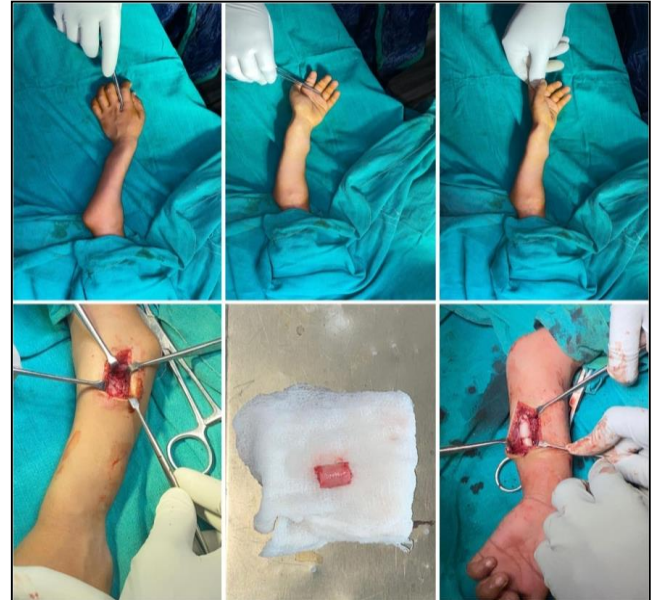A 9-year-old male child presented to our department with complaints of chronic pain and deformity of the left wrist and forearm, aggravated during activity. On further evaluation, the patient also had bony swelling on the ulnar aspect of his left wrist. He also had similar bony swelling arising on the medial aspect of the proximal tibia. There is no history of trauma or any relevant family history noted. Physical examination revealed ulnar deviation of the left hand with reduced grip strength. Extension/flexion of both wrists was about 65/80 degrees. Pronation and supination were 80/80 degrees.



**Figure 1 (A-C): Radiological evaluation: preoperatively radiological evaluation done and modified dual osteotomy of both bone done correcting deformity. Excellent outcome achieved at a follow-up of 18 months.**

Preoperative planning was done to find out the CORA (centre of the rotation axis) of the deformed forearm on radiographs. The patient subsequently underwent an operation after proper counselling with his parents regarding revision surgeries in the future if required. Dual osteotomy of both the radius and ulna was performed followed by fixation. Kocher's approach was taken to expose the proximal radius at the maximum angulations and about 2 cm of the radius was osteotomized while preserving the periosteum. After this, ulnar osteotomy was performed and this osteotomized fragment was fixed at the ulnar side under traction and manipulation for the correction of the deformity. Fixation of both bones was

done using intramedullary titanium elastic nails. The exostosis on the distal ulna was curetted and sent for biopsy. Postoperatively the patient was kept immobilized for 6 weeks under the above elbow slab. Subsequent x-rays were done at 1, 6, and 18 months of follow-ups.



**Figure 2: Intra-operative procedure: After calculating CORA, via Kocher's approach radius osteotomy done and about 2 cm of bone piece removed which was placed at ulna osteotomy site, periosteum was preserved to achieve adequate union at osteotomy site. Fixation was done using titanium intramedullary nail.**

## DISCUSSION

Madelung's deformity is one of the rare congenital abnormalities involving the forearm and wrist. In a larger study of congenital hand deformity done at the University of Iowa, out of 1,476 patients only 37 cases of Madelung's deformity have been noted.<sup>2</sup> Due to its low prevalence and case-to-case variability, no exact modality has been defined for all the patients. Different modalities have been used among which radial biplane osteotomy with or without ulna shortening is commonly performed. Other procedures include radial lengthening with the help of Ilizarov or external fixators resection of physeal bar and Sauve-Kapandji procedure.

Usually, younger children with mild deformity are treated non-operatively, with an expectation of possibilities of deformity reoccurrence and physical preservation for further bone lengthening with remodification. Early operated younger patients may require revision correction surgery. Adolescence is considered a good time for intervention, once adequate skeletal maturity is achieved.

Ilizarov is a widely used modality for deformity correction, and Madelung's deformity is also not spared. It provides an opportunity for biplanar correction and is

especially useful where shortening and angulations are more. Houshain et al have performed Madelung's deformity correction using a modified Ilizarov frame, where 8 patients were treated with an aim of simultaneous angle and length correction.<sup>3</sup> Two out of 8 patients (25%) developed pin site infection, and another 2 patient (25%) required to re-operate. Ilizarov is also known for its prolonged duration of treatment, inconveniencies due to large ring frame, and joint stiffness associated with it.

Radial osteotomy with or without ulna shortening is considered the gold standard treatment for Madelung's deformity. Loffosse et al performed closed wedge osteotomy and ulna shortening procedures on 14 adolescent patients and with an average follow-up of 5 years, an excellent result was found.<sup>4</sup> Sauve-Kapandji is a procedure that includes ulna osteotomy proximal to the ulna head and distal radioulnar joint arthrodesis. Angelini et al reported minimum complication with the good result by this procedure in 15 adolescent patients with a mean follow-up of 5.6 years.<sup>5</sup> Aharoni et al and Glard et al have performed ulna-shortening procedures.<sup>6,7</sup> Sometimes radial osteotomy was not found enough and ulnar shortening was performed to maintain distal radioulnar joint function and wrist stability. However, it is not desirable to shorten the forearm, especially where it is already shortened.

Many forearm osteotomy studies have been performed in adolescent children. On the other hand, the Selection of modality, especially in younger individuals where the deformity is severe and daily activity is impaired; in addition, possibility of bone modification cannot be assessed at this age. It is found that a poorer prognosis is associated with more severe and whole bone involving cases of this disease.<sup>8,9</sup> To overcome this complication in younger individuals, we have performed a diaphyseal dual corrective osteotomy. Special care has been taken to preserve the periosteum while operating.

A major advantage of this procedure is all the joint and periarticular ligaments, as well as the periosteum, is preserved; it is useful in increasing the possibility of bone and joint remodelling since it is done in a younger child. Supporting to this result, Salon et al also performed radio-ulnar osteotomy with preservation of the distal radioulnar joint and found excellent results at long-term follow-up.<sup>10</sup> However, the effectiveness of this method in typical Madelung's deformity and long-term follow-up needs to be evaluated.

## CONCLUSION

In the current study, via this new method for Madelung's like deformity we found excellent results at short-term follow-up. Maintaining natural articulation with periarticular soft tissue and periosteum has played a major role in that. For the future, we would advise this method evaluating functional outcomes in typical Madelung's deformity.

*Funding: No funding sources*

*Conflict of interest: None declared*

*Ethical approval: Not required*

## REFERENCES

1. Henry A, Thorburn MJ. Madelung's deformity: a clinical and cytogenetic study. *J Bone Joint Surg.* 1967;49(1):66-73.
2. Wood VE, Flatt AE. Congenital triangular bones in the hand. *J Hand Surg.* 1977;2(3):179-93.
3. Houshian S, Schröder H, Weeth R. Correction of Madelung's deformity by the Ilizarov technique. *J Bone Joint Surg.* 2004;86(4):536-40.
4. Laffosse JM, Abid A, Accadbled F, Knör G, Sales de Gauzy J, Cahuzac JP. Surgical correction of Madelung's deformity by combined corrective radioulnar osteotomy: 14 cases with four-year minimum follow-up. *Int Orthop.* 2009;33(6):1655-61.
5. Angelini LC, Leite VM, Faloppa F. Surgical treatment of Madelung disease by the Sauvé-Kapandji technique. In *Annales de Chirurgie de la Main et du Membre Supérieur.* 1996;15(4):257-64.
6. Aharoni C, Glard Y, Launay F, Gay A, Legré R. Maladie de Madelung: ostéotomie isolée de l'ulna. *Chirurgie de la main.* 2006;25(6):309-14.
7. Glard Y, Gay A, Launay F, Guinard D, Legré R. Isolated wedge osteotomy of the ulna for mild Madelung's deformity. *Journal of hand surgery,* 2007;32(7):1037-42.
8. Zebala LP, Manske PR, Goldfarb CA. Madelung's deformity: a spectrum of presentation. *J Hand Surg.* 2007;32(9):1393-401.
9. Steinman S, Oishi S, Mills J, Bush P, Wheeler L, Ezaki M. Volar ligament release and distal radial dome osteotomy for the correction of Madelung deformity: long-term follow-up. *JBJS.* 2013;95(13):1198-204.
10. Salon A, Serra M, Pouliquen JC. Long-term follow-up of surgical correction of Madelung's deformity with conservation of the distal radioulnar joint in teenagers. *J Hand Surg Bri Euro.* 2000;25(1):22-5.

**Cite this article as:** Agarwal A, Patel R, Jain M, Arora S, Golwala P, Agarwal S. Modified dual osteotomy for Madelung's deformity. *Int J Res Orthop* 2023;9:432-4.