

Original Research Article

Clinical outcomes of the intramedullary femoral nailing system in the treatment of femoral fractures

Akash Sharma^{1*}, Arpit Jain², Gaurav Luthra¹

¹Department of Regulatory, ²Department of Clinical Research, Kaulmed Private Limited, Sonipat, Haryana, India

Received: 13 November 2021

Revised: 27 November 2021

Accepted: 28 November 2021

*Correspondence:

Dr. Akash Sharma,

E-mail: ra2@kaulmed.com

Copyright: © the author(s), publisher and licensee Medip Academy. This is an open-access article distributed under the terms of the Creative Commons Attribution Non-Commercial License, which permits unrestricted non-commercial use, distribution, and reproduction in any medium, provided the original work is properly cited.

ABSTRACT

Background: Femoral fractures are a common type of fracture brought on by large force impaction. This study's objective was to clinically assess the results of using an intramedullary femoral nailing system to treat femoral fractures.

Methods: 32 patients with femoral fractures are included in this retrospective clinical trial. They are all treated with an intramedullary femoral nailing system made by Kaulmed private limited in Sonipat, Haryana, India. This system includes KN-1 advance nails (PFNA), KN-6 femur nails (retrograde Nails), KN-3 nails type II (gamma nails), KN-2F femur nails (expert femoral nails), and KN-5F universal intramedullary cannulated femoral nails. There were 32 patients, with 15 from one hospital and 17 from the other. The first hospital group consisted of 8 men and 7 women, with an average age of 32 years and the second hospital group consisted of 9 male and 8 female with mean age of 40.5 years. The fractures were categorized based on AO classification and pre-operative fitness was assessed using American society of anaesthesiologist (ASA Grade). The clinical effectiveness was evaluated using the VAS score and anatomical results.

Results: Surgery was performed on 32 patients with at-least three post-operative follow-up visits in 180 days. No patient in any group complained after the final follow up about complications or hardware problems, and every patient's bone union was achieved successfully. Radiological outcomes also showed proper union at 6 months.

Conclusions: In femoral fractures, the intramedullary femoral nail provides better results with a high rate of union and postoperative composure.

Keywords: Intramedullary femoral nailing system, Femoral fracture, Proper union, VAS score

INTRODUCTION

The femur bone is the largest, heaviest, and strongest of all the bones in the human body, measuring 48 cm long and 2.34 cm in diameter for an average adult male. The femur's forward-bowed shaft is almost cylindrical in shape.¹ The three sections of the femur bone are the proximal, diaphyseal, and distal. One of the fractures that orthopaedic surgeons treat the most commonly is a fracture of the femoral shaft. These fractures can be fatal and are frequently linked to severe traumas. Accidents and falls with heavy impact are two of the causes of femoral fractures. A femur fracture can happen in a number of ways, including fractures in the diaphysis, head, and neck.

In this study, the categorization of bone fracture was done using the Muller AO system.

Internal fixation and open or closed reduction have both been recommended as successful treatments for this injury. Femoral fractures can be treated using a variety of techniques. For its treatment, which leads to significant skin incisions, further soft tissue dissection, and increased blood loss, bone plates are frequently employed. Given the aforementioned issues, an intramedullary device that is simple to handle would be the perfect implant for the treatment of femoral fractures.² Therefore, the adoption of an intramedullary femur nailing technique has become more popular. Parker-Palmer mobility score is used to

quantify clinical outcomes; however, this clinical study will concentrate on utilising VAS (visual analogue scale) score instead. In order to examine the clinical results and side effects of treating femoral fractures with the femur nailing system made by Kaulmed private limited, a retrospective clinical investigation was conducted.

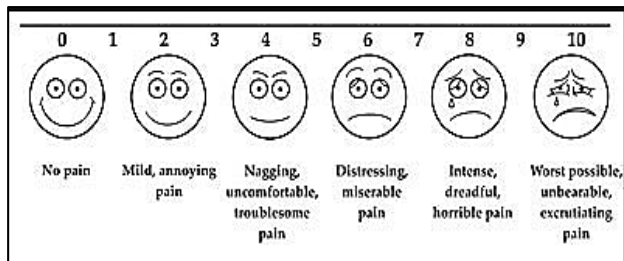


Figure 1: VAS score.




Figure 2 (A-I): KN-1 advance nailing system; 130° KN-1 advance nail, short 130° KN-1 advance nail, long, KN-1 blade, KN-1 cephalic screw, KN-1 nail end cap (For KN-1 Blade), KN-1 nail end cap (For cephalic screw), end cap for KN-1 cephalic screw, inner screw for KN-1 cephalic screw, 4.9 mm KN-1 locking bolt, self-tapping.




Figure 3 (A-D): KN-2F femur nailing system; KN-2F femur nail, 4.8 mm locking bolt, self tapping, end cap for KN-2F femur nail, 6.4 mm cannulated anti-rotation screw, self-tapping.




Figure 4 (A-G): KN-5F femur nailing system; KN-5F universal intramedullary cannulated femur nail, 4.5 mm locking bolt, self tapping, 6.5 mm locking bolt, full thread, 6.5 mm cannulated reconstruction screw, 6.5 mm blocking set, compression screw, end cap for KN-5F universal intramedullary cannulated femur nail.

The intramedullary femur nailing system manufactured by Kaulmed private limited are available in different design and materials catering to the specific requirement of the individual patient. The following figures show the various femur nailing systems manufactured by Kaulmed private limited and implanted in the patient.




Figure 5 (A-J): KN-3 femur nailing system; 125° and 130° KN-3 nail type-II, short 125° and 130° KN-3 nail type-II, long, 125° and 130° anti-rotation KN-3 nail, short 125° and 130° anti-rotation KN-3 nail, long Ø10.5 mm cephalic screw, for KN-3 nails, inner screw for KN-3 nails (Short and long), end cap for KN-3 nails, end cap for Ø10.5 mm cephalic screw for KN-3 nail and 4.8 mm locking bolt, self-tapping and 6.4 mm cannulated anti-rotation screw.



Figure 6 (A-C): KN-6 femur nailing system; KN-6 femur nail, 5.0 mm locking screw for KN-6 femur nail and end cap for KN-6 femur nail.

METHODS

Data were gathered for patients who were treated with an intramedullary femoral nailing system during this retrospective study, which took place at Jawahar Lal Nehru hospital in the Mauritius from September 2021 to July 2022 and at Victoria hospital in the Mauritius from October 2021 to August 2022. Ethical approval from institutional ethics committee was obtained prior to data collection from patient files. Age, gender, height, weight, body mass index (BMI), fracture type and side, American society of anaesthesiologist (ASA) score, and operation date and time were all obtained. According to the AO classification of fractures, as indicated in Table 2, there were 10 patients with a 31 A1-C3 fracture, 18 patients with a 32 A1-C3 type of fracture, and 4 patients with a 31-A3 kind of fracture. The skilled orthopaedic surgeons used the intramedullary femoral nailing technique to treat 32 patients. The patients were split into two groups: group I (Jawahar Lal Nehru hospital) and group II (Victoria Hospital). There were a total of 15 patients in group I, with an average age of 32 years, and 17 patients in group II, with an average age of 40.5 years. For this study, there were no control groups created. The surgical technique was defined by the manufacturer was adopted as the surgical process used for the treatment.

The American society of anaesthesiologist (ASA grade) classified the patient's clinical state into two groups: 6 (4 M and 2 F) were classified under grade 2, which denotes patients with moderate systemic illness, and rest were classified under grade 1, which indicates a normal healthy patient. Patients classified as grade 3 or above by ASA were not included in the research.

The procedure was carried out utilising an intramedullary femoral nailing system made of titanium alloy (Ti- 6Al-4V) and stainless steel (316LRM), produced by Kaulmed private limited in Sonapat, Haryana, India. The VAS score was utilised as a standard for measuring pain. The patients with post operative visit in 180 days included in the study. Every patient who received intramedullary nails demonstrated proper union. After six months, an X-ray revealed that fusion had begun. The same surgeon who performed the operation also analysed all of the radiological readings. At last visit, there were no problems with any patient.

Inclusion criteria

Male or female participants who were at least 18 years old and had recently suffered a femoral fracture with an injury time of between 12 and 72 hours were included in the research.

Exclusion criteria

Patient age greater than 65, mortality before to surgery, and non-surgical therapy were exclusion criteria. Subjects who had problems with alcohol abuse, those who were detained or were in the process of being detained, those who had an infection at the site of the operation, patients who had any active local infections, those who had an allergy to the metal used in the nailing system, and patients who had problems with neuromuscular diseases were also excluded from this study.

Treatment

When the patient were presented in the emergency closed reduction and splinting were performed. Based on the radiographs, for unstable fractures indications, open surgery and intramedullary nail fixation were planned and operation was performed to stabilize the fracture. Static locking is performed distally and proximal screws used in the proximal section. Dynamic locking is performed in the presence of displacement fracture. A short splint was applied after the surgery to prevent the motion and any load at the surgical site. It was taken off after four weeks and after the confirmation of bone union initiation, the exercises started to increase the wrist ROM and weight bearing.

Statistical analysis

All statistical analyses will be performed using Minitab. Results are reported as means ± standard deviations for

continuous variables and as number (%) for nominal variables. The endpoints are summarized using descriptive statistics (Mean, median standard deviation, minimum, maximum). For a normal distribution, parametric tests will be applied; otherwise equivalent non-parametric tests will be applied for analysis. For normally distributed data, intra group at various follow-up using Paired-t-test using the statistical software. P<0.05 to be considered as statistically significant.

RESULTS

There were 32 patients overall. According to Table 1, there were 17 men (53.13%) and 15 women (46.87%) enrolled in the research. The typical surgical session lasted 62 minutes, while the typical fluoroscopy session lasted 14 seconds. Patients experienced swelling, redness, and excruciating pain at the time of the fracture and hospitalisation. There were 28 fractures brought on by auto-mobile collisions, two by sports-related injuries, and two by falls from great heights (Table 2). The fracture patterns recorded in the patient data were categorized as per AO classification based on the X-Ray radiographs (Table 3).

All patients had anaesthesia before surgery, and all wound dressings were also removed. Following femur surgery, patients received physical rehabilitation from physiotherapists, and they participated in a variety of activities at the physiotherapists' advice. Different post-operative treatments were carried out to for the early activation of mobilization after the surgery.

Table 1: Demographic data.

Demographics, (n=32 patients)	Value	
	Group 1	Group 2
Mean age (years)	32	40.5
Male, N (%)	8 (53.33)	9 (52.94)
Female, N (%)	7 (46.67)	8 (47.06)

Table 2: Aetiology.

Fracture cause	Percentage (%)
Motor vehicle accidents	28 (87.5)
Slip and fall	2 (6.25)
Other (sports, etc.)	2 (6.25)

Table 3: AO fracture classification.

AO fracture type	No. of patients
31 A1-C3	10
31 A3	04
32 A1-C3	18

At the final follow-up, patients evaluated the clinical evaluation for pain, cosmetic appearance (Table 4), and treatment satisfaction using a VAS score (the most extreme score, 10 focuses). The early activation of treated femur fractures was made possible by a variety of

painkiller approaches. According to VAS average score decrease as the time elapsed, on average after one month the VAS score was 4.5 which reduced to 2.1 after three months and further decreased to 1.2 after six months later (Table 4). At the initial check-up, 2 patients complained of

irritation and infection, but at the future check-ups, no patient complained of any health-related issues. At the final check-up, there were no complications to be found, and the bones had properly united in each case.

Table 4: Result of VAS score.

Visit time	Pain scale					
	No pain	Mild pain	Nagging	Distress	Intense	Worst possible
Pre-surgery	-	-	-	-	-	9.8
Post-surgery (After anaesthesia effect wear off)	-	-	-	7.2	-	-
30±15 days	-	-	4.5	-	-	-
90±30 days	-	2.1	-	-	-	-
180±30 days	1.2	-	-	-	-	-

Table 5: Anatomical result.

Anatomical result	N	Percentage (%)
Restriction of hip ROM	2	6.25
Restriction of knee ROM	1	3.12

Table 6: Patient satisfaction.

Evaluation parameter	Satisfied (%)	Un-satisfied (%)
Permanent pain reduction	31 (96.87)	1 (3.12)
Full weight bearing	30 (93.75)	2 (6.25)
Aesthetics	31 (96.87)	1 (3.12)

The recovery of movement was assessed after the physiotherapy session of one month. The patient ROM data of hip motion and knee motion was collected on each postoperative visit. At last visit only two patients were observed with the restricted hip motion and one for knee motion (Table 5). The patient satisfaction based on pain, weight bearing and aesthetics was also collected at their last visit (Table 6).

DISCUSSION

Obstacles involving femoral fractures are frequent in orthopaedic trauma. Proximal, diaphyseal, and distal area fractures are only a few of the several types of fractures that can occur. Femoral fractures can be treated using a variety of techniques, including skeletal traction, bone plates, intramedullary nailing, and rehabilitation. However, intramedullary nails, such as KN-1 advance nails (PFNA), KN-6 femur nails (retrograde nails), KN-3 nails type II (gamma nails), KN-2F femur nails (expert femoral nails), and KN-5F universal intramedullary cannulated femoral nails, are more often used to treat femoral fractures (Figure 2-5).

Previous studies with the use of intramedullary nails have found serious issues such infection, irritability, and implant failure. In our study, 32 patients received an

intramedullary nail, and at the time of the final follow-up, none of them had complained of discomfort, infection, or irritation. No complications were discovered at last visit. The VAS scores of the two groups had a little variation. The VAS score has produced positive acceptance results. Therefore, intramedullary nail is the gold standard for treating femoral fractures. It has been indicated that intramedullary nail fixation is the preferred choice for treating femur fractures if complete weight bearing is a consideration.³⁻¹⁰

The present study shows the treatment of Femoral fracture using an intramedullary nailing device which was designed and manufactured by Kaulmed private limited, India.

In research by Huang et al 23 patients were enrolled, but none of them experienced implant failure, and the problem was also not discovered at the end of the study.¹¹

This is comparable to how you found us. Our study's primary limitations were its small sample size and retrospective design. Despite these restrictions, the outcomes met our expectations, which were established before the clinical research ever began.

Although in the present study, pain was observed as major clinical outcome for which data shows good result in pain reduction in less duration. No major complication non-union, mal-unions and deep infection were observed, although some cases were reported with infections which was managed through medication and delayed bone union no major complication that may required re-surgery.

Limitation of present study is sample size, retrospective design and no statistical significance considered data analysis. Only descriptive data with mean, range and frequency is shown. These limitations can be avoided using different study design with large sample size.

CONCLUSION

Femoral fractures are common fractures that orthopaedic surgeons repair. They happen when an enormous amount

of force impinges on the femur. Utilizing intramedullary nails is the most effective approach for treating femoral fractures, and it produces positive clinical results. Most femoral nailing issues are caused by doctors, patients, and equipment, and they may be avoided with appropriate surgery and post-op care. The majority of surgeons favour this minimally intrusive approach since it is effective.

ACKNOWLEDGEMENTS

Author would like to thanks to the clinicians, doctors and hospital staff for supporting and allowing us to conduct the study. The author(s) also thankful to Kaulmed private limited for providing the opportunity to participate in the study.

Funding: No funding sources

Conflict of interest: None declared

Ethical approval: The study was approved by the Institutional Ethics Committee

REFERENCES

1. Khaleel N. Morphometric study of human femur. Int J Cur Shaik Hussain Saheb. 2013;5:6.
2. Simmermacher RKJ, Ljungqvist J, Bail H, Hockertz T, Vochteloo AJH, Ochs U et al. The new proximal femoral nail antirotation (PFNA) in daily practice: results of a multicentre clinical study. Injury. 2008;39(8):932-9.
3. Yang YH, Wang YR, Jiang SD, Jiang LS. Proximal femoral nail antirotation and third-generation Gamma nail: which is a better device for the treatment of intertrochanteric fractures? Singapore Med J. 2013;54(8):446-50.
4. Sahin EK, Imerci A, Kınık H, Karapınar L, Canbek U, Savran A. Comparison of proximal femoral nail antirotation (PFNA) with AO dynamic condylar screws (DCS) for the treatment for unstable peritrochanteric femoral fractures. Eur J Orthop Surg Traumatol. 2014;24(3):347-52.
5. Dougherty PJ, Gherebeh P, Zekaj M, Sethi S, Oliphant B, Vaidya R. Retrograde Versus Antegrade Intramedullary Nailing of Gunshot Diaphyseal Femur Fractures. Clin Orthop Related Res. 2013;471(12):3974-80.
6. Xiong R, Mai QG, Yang CL, Ye SX, Zhang X, Fan SC. Intramedullary nailing for femoral shaft fractures in adults. Cochrane Database Systematic Rev. 2018;2018(2):CD010524.
7. Sharma A, Mahajan A, John B. A Comparison of the Clinico-Radiological Outcomes with Proximal Femoral Nail (PFN) and Proximal Femoral Nail Antirotation (PFNA) in Fixation of Unstable Intertrochanteric Fractures. J Clin Diagn Res. 2017;11(7):RC05-9.
8. Gardenbroek TJ, Segers MJM, Simmermacher RKJ, Hammacher ER. The proximal femur nail antirotation: an identifiable improvement in the treatment of unstable peritrochanteric fractures? J Trauma. 2011;71(1):169-74.
9. Zehir S, Şahin E, Zehir R. Comparison of clinical outcomes with three different intramedullary nailing devices in the treatment of unstable trochanteric fractures. Ulus Travma Acil Cerrahi Derg. 2015;21(6):469-76.
10. Li YH, Zhu D, Li Y, Zhao T, Cao Z, Tan L. Comparison of internal fixation with Gamma3 Long nails and INTERTAN nails in the treatment of Seinsheimer type V subtrochanteric femoral fractures in elderly patients. Med (Baltimore). 2019;98(25):e16140.
11. Huang FT, Lin KC, Yang SW, Renn JH. Comparative study of the proximal femoral nail antirotation versus the reconstruction nail in the treatment of comminuted proximal femoral fracture. Orthopaedics. 2012;35(1):e41-7.

Cite this article as: Sharma A, Jain A, Luthra G. Clinical outcomes of the intramedullary femoral nailing system in the treatment of femoral fractures. Int J Res Orthop 2023;9:11-5.