

## Original Research Article

# Clinical and radiological outcome of 3- and 4-part proximal humerus fracture managed with J nails in elderly osteoporotic individuals

R. M. Chandak<sup>1</sup>, Mohit Sharma<sup>2\*</sup>, Amrit Jha<sup>2</sup>

<sup>1</sup>Department of Orthopaedics, Chandak Orthopaedic Hospital, Nagpur, Maharashtra, India

<sup>2</sup>Department of Orthopaedics, Dr. Baba Saheb Ambedkar Hospital and Medical College, Rohini, New Delhi, India

**Received:** 15 July 2021

**Revised:** 16 August 2021

**Accepted:** 17 August 2021

### \*Correspondence:

Dr. Mohit Sharma,

E-mail: [drmohitsharma1989@gmail.com](mailto:drmohitsharma1989@gmail.com)

**Copyright:** © the author(s), publisher and licensee Medip Academy. This is an open-access article distributed under the terms of the Creative Commons Attribution Non-Commercial License, which permits unrestricted non-commercial use, distribution, and reproduction in any medium, provided the original work is properly cited.

## ABSTRACT

**Background:** Proximal humeral fracture is 3rd most common fracture in elderly population. Selection of appropriate implant is always challenging to get optimum results in these osteoporotic bones. Though locking plates are gold standard, major complications range from 9% to 36%. To study clinical and radiological outcome of J nail technique for Neer's three or four part proximal humeral fractures in patients more than 60 years age.

**Methods:** We retrospectively studied 60 patients of 3 or 4 part proximal humeral fractures, >60 years of age treated with J nail technique from the period of 2015 to 2017. J nails were made using 2 mm 12 inches blunt tip Lambriunidi wires. At final follow-up, clinical outcome was assessed using constant score and radiological evaluation was done according to the Bahr criteria.

**Results:** The mean constant score at final follow-up was 90. The postoperative reduction was excellent in 98% of patients and remained excellent in 90%. The mean postoperative neck shaft angle was 135.0° and final neck shaft angle was 131.4°. No deep infection was seen. No avascular necrosis of humeral head was found till follow up to 2 years.

**Conclusions:** Our study suggests that the functional and radiological outcomes obtained with J nailing are excellent and similar to locking plates and percutaneous Kirschner wire fixation with many other advantages of being simple, minimally invasive, avoiding muscle transfixation and no pin site infections.

**Keywords:** J nail, Locking plates, Neer's 3 or 4 part

## INTRODUCTION

Proximal humeral fracture is 3rd most common fracture in elderly population. More than 70% of patients with proximal humeral fractures are in age of 60 years and above.<sup>1</sup> Minimally displaced or impacted fractures do well with conservative therapy. The incidence of three and four part fracture is 21% to 23% of all proximal humerus fractures.<sup>2</sup> Closed reduction with non-operative management is an option in such cases also, but the functional results tend to be poor with Constant scores ranging from 47 to 62.<sup>3</sup>

Selection of appropriate implant is always challenging to get optimum results in these osteoporotic bones. Though locking plates are gold standard, major complications such as deep infection, screw cutout, avascular necrosis range from 9% to 36%.<sup>3</sup>

Many percutaneous fixation techniques have been described in the literature. But these are associated with 10 to 21 % complication rates, which include pin site infections, pin backout and loss of reduction.<sup>4</sup>

A surgical procedure using three intramedullary nails (J-nails) to fix unstable proximal humeral fractures had been

described by Takeuchi et al to minimize the disadvantages of operative treatment.<sup>5</sup>

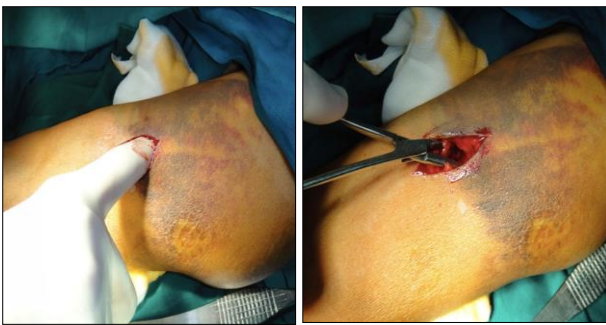Our objective of this study is to evaluate clinical and radiological outcome of J nail technique for Neer's three or four part proximal humeral fractures in patients more than 60 years age.

## METHODS

Retrospectively we studied patient of 3 or 4 part unstable displaced fracture of proximal humerus as per Neer's classification. Neer defined an unstable fracture as a fracture that is displaced by more than one centimeter and/or angulated more than 45 degrees. 69 patients were operated in between January 2015 to December 2017. Patients with atleast two year of follow up were included in the study. 8 patients lost follow up, while one case went in non-union, so excluded from study. So we studied 60 patients from age 61 to 82 years, with 32 female and 28 male. Patients with associated shaft fracture, fracture dislocation, fracture with split of head, pathological fracture, non-union or neglected fractures were excluded.

### Surgical technique

All patients were taken under regional block anesthesia, in supine on radiolucent table. J nails were made up of 2 mm and 12 inches Lambrinudi wires (blunt tip Kirschner wires). 2.5 to 3 cm incision at mid arm anterolateral aspect were taken just distal to deltoid insertion. 3 or 4 J nails were used in each case (Figure 1).

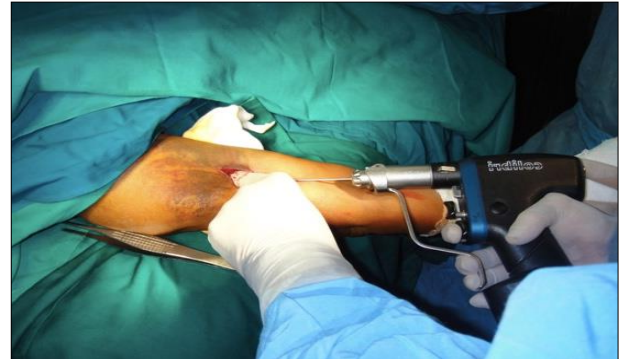


**Figure 1: Incision and entry point 1 inch on lateral side of upper arm, just below distal end of deltoid muscle insertion approximately 1.5 cm long incision.**

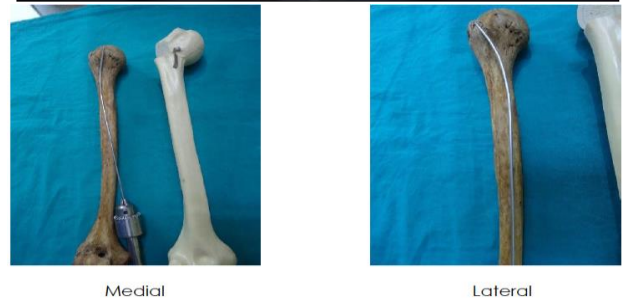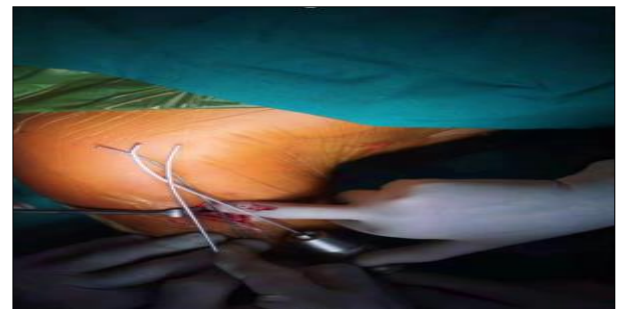Placement of J nail was planned as per varus or valgus fracture pattern (Figure 2 and 3).

All fractures were reduced with standard reduction maneuver. If greater tuberosity found displaced, was reduced percutaneously and fixed separately with one or two 2 mm Kirschner wires. All patients were discharged next day with arm sling. Passive exercises started immediately post op. Stitches removal was done on 10th day. If greater tuberosity was fixed, its Kirschner wires were removed under local anaesthesia at six weeks. Active

range of motion exercises and strengthening exercises started at 6 weeks. Anteroposterior and axial radiographs were taken at day 1, 6 weeks, 3 months, 6 months, 1 year and at latest follow up. All hardware were removed by 9 to 12 months.



**Figure 2: Keeping k wire as parallel to the shaft as possible and trying to negotiate medullary cavity.**



**Figure 3: Trajectory mapping of J nail.**

At final follow up, all patients were evaluated clinically with constant score, which includes pain (0-15), activity of daily living (0-20), range of motion (0-40), strength (0-25).<sup>6</sup> The shoulder function was tested with a goniometer and the muscle power with a spring balance as described by Constant et al.<sup>6</sup>

Also patients were evaluated radiologically with the Bahrs' criteria, which includes greater tuberosity with displacement <5 mm, No increased varus or valgus ( $\pm 15^\circ$ ) of the head fragment in the anteroposterior view, no increased retro or antetorsion ( $\pm 15^\circ$ ) of the head fragment in the axillary view.<sup>2</sup> We compared it with average normal value in population, humeral neck shaft angle is  $135^\circ$  and retroversion is  $21^\circ$ .<sup>2</sup> If all three criteria were met, it

considered excellent; if two were met, it considered good; if one was met, it considered fair and if none was met, it considered poor result.<sup>2</sup>

### Statistical analysis

Comparative statistical analyses between genders were made using the paired t-test for parametric continuous data. Linear regression analysis was performed to determine correlation of age, gender and clinical outcome. A p value of <0.05 was considered as statistically significant. All analysis was performed using statistical package for social sciences (SPSS) 20.0 software.

## RESULTS

Out of 60 patients, 32 were female with mean age 70.75 years and 28 were male with mean age 69.32 years (Table 1). Mean follow up of patients was 30 months with minimum 24 months and maximum 44 months. 40 patients had 3 parts fracture and 20 had 4 parts fracture (Table 2).

### Clinical evaluation

Mean constant score was found to be 84.5 with 79.12 in female and 89.57 in male ( $p < 0.05$ ) (Table 3).

Mean constant score was 84.8 in 3 part fractures and 84.1 in four part fracture with  $p > 0.05$  (Table 4).

Constant score had shown negative correlation with the age of patient (Figure 3). None of the patient developed superficial or deep infection.

### Radiological evaluation

All fractures healed uneventfully. None of the case developed avascular necrosis of humeral head. Average humeral neck shaft angle was  $135^\circ$  at immediate post op and  $131.4^\circ$  at last follow up. As per Bahr's criteria 54 had excellent outcome, 4 had good outcome and 2 had fair outcome (Table 5).

**Table 1: Mean age of patients in the study.**

Parameters	Total	Female	Male
<b>Number</b>	60	32	28
<b>Age: mean<math>\pm</math>SD (range)</b>	70.23 $\pm$ 5.22 (61-82)	70.75 $\pm$ 5.81 (61-82)	69.32 $\pm$ 4.65 (62-80)

**Table 2: Fracture pattern among male and female.**

Parameters	3 part #	4 part #
<b>Total</b>	40	20
<b>Female</b>	22	10
<b>Male</b>	20	8

**Table 3: Mean constant score among male and female.**

Parameters	Total	Female	Male
<b>Score: mean<math>\pm</math>SD (range)</b>	84.5 $\pm$ 5.99 (74-93)	79.12 $\pm$ 3.45 (74-86)	89.57 $\pm$ 2.11 (84-93)

**Table 4: Mean constant score among fracture pattern.**

Parameters	Total (60)	3 part # (40)	4 part # (20)
<b>Score: mean<math>\pm</math>SD</b>	84.5 $\pm$ 5.99 (74-93)	84.8 $\pm$ 5.67 (75-93)	84.1 $\pm$ 5.34 (74-92)

**Table 5: Radiological outcome among male and female.**

Bahr's criteria	Total	Female	Male
<b>Excellent</b>	54	28	26
<b>Good</b>	4	2	2
<b>Fair</b>	2	1	1
<b>Poor</b>	0	0	0

## DISCUSSION

The incidence of displaced 3 part and 4 part proximal humeral fractures is growing, particularly in the elderly population.<sup>3</sup> Treatment options ranges from conservative

treatment, fixation with percutaneous techniques, intramedullary nails, locking plates and arthroplasty.<sup>14</sup>

All methods are having their advantages and disadvantages. There is no clear evidence-based treatment of choice. The surgeon needs to consider their experience

and expertise with various procedures during the decision-making process.

In young patients with good bone quality, locking plates allow early and more aggressive rehabilitation.<sup>10</sup> However in the elderly, they may fail due to an insufficiency of the bone-metal-interface during cyclic loading. On other hand, elastic implants may reduce the strain on the interface by absorbing part of the energy.<sup>11</sup> Locking plates are also associated with 9-16% major complications including deep infections, avascular necrosis, screw cut out, non-union.<sup>3</sup>

Various percutaneous pinning techniques described in literature have the advantage of being less invasive and a simple procedure, but are associated with pin site infections, pin back out, pin cut out, loss of reduction, muscle trans-fixation, pin migration and the possibility of neurovascular injury.<sup>4,7,13</sup>

In our study, we fixed all fractures with J nail technique, described by Takeuchi et al with some modifications.<sup>5</sup> We did not encounter any superficial or deep infection. There was no backing out of J nail. No avascular necrosis was seen. Locking plate fixation is thought to have a higher risk of avascular necrosis secondary to periosteal stripping.<sup>14</sup> Even after traditional pinning incidence of avascular necrosis of the humeral head ranges from 4% to 14%.<sup>7,8</sup>

Migration of Kirschner wires is a major complication with percutaneous pinning, but we could avoid that complication by making oblique entry holes in humerus shaft as described by Takeuchi et al.<sup>5,13</sup>

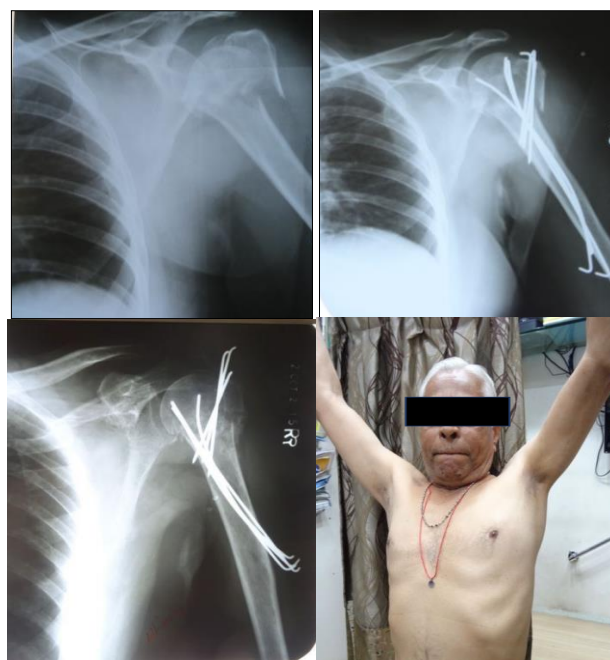
Early callus formation was seen in almost all cases, as early as 6 weeks. One case of 3 parts fracture went into non-union, which healed with open reduction internal fixation and bone grafting. Around 6% non-union rate is described with proximal humerus locking plate.<sup>12</sup>

Our clinical and radiological results are comparable to other case series described in literature for fixation of proximal humeral fractures. In accordance with the literature, we also found an association between age and functional outcome.<sup>9</sup> Constant scores were declining significantly with age (Figure 4).

Mean constant score was 90 in male and 80 in female. Radiologically 90% patient had excellent outcome in follow up.

#### Limitations

There are few limitations in our study. We did not perform comparative study of our method with locking plate or other percutaneous techniques. It was single centric, retrospective study. To generalize the results, further prospective multicentric study with large number of cases is advisable.



**Figure 4: Case 1 pre-op and post op and follow up radiograph with clinical picture at 6 months.**

#### CONCLUSION

J nailing for a proximal humeral osteoporotic 3 and 4 part fracture is a promising technique. Outcome is comparable with locking plates and other percutaneous pinning methods. Percentage of complication rate is quite lower.

*Funding: No funding sources*

*Conflict of interest: None declared*

*Ethical approval: The study was approved by the institutional ethics committee*

#### REFERENCES

1. Lauritzen JB, Schwarz P, Lund B, McNair P, Transbol I. Changing incidence and residual lifetime risk of common osteoporosis-related fractures. *Osteoporos Int.* 1993;3:127-32.
2. Bahrs C, Rolaufts B, Dietz K, Eingartner C, Weise K. Clinical and radiological evaluation of minimally displaced proximal humeral fractures. *Arch Orthop Trauma Surg.* 2010;130:673-9.
3. Olerud P, Ahrengart L, Ponzer S, Saving J, Tidermark J. Internal fixation versus nonoperative treatment of displaced 3-part proximal humeral fractures in elderly patients: a randomized controlled trial. *J Shoulder Elbow Surg.* 2011;20(5):747-55.
4. Carbone S, Tangari M, Gumina S, Postacchini R, Campi A, Postacchini F. Percutaneous pinning of three- or four-part fractures of the proximal humerus in elderly patients in poor general condition: MIROS® versus traditional pinning. *Int Orthop.* 2012;36:1267-73.
5. Takeuchi R, Koshino T, Nakazawa A, Numazaki S, Sato R, Saito T. Minimally Invasive Fixation for

- Unstable Two-Part Proximal Humeral Fractures: Surgical Techniques and Clinical Results Using J-Nails. *J Orthop Trauma.* 2002;16.
6. Constant CR, Murley AH. A clinical method of functional assessment of the shoulder. *Clin Orthop Relat Res.* 1987;214:160-4.
  7. Jaberg H, Warner JP, Jacob RP. Percutaneous stabilization of unstable fractures of the humerus. *J Bone Joint Surg Am.* 1992;74:508-14.
  8. Soete PJ, Clayson PE, Costenoble H. Transitory percutaneous pinning in fractures of the proximal humerus. *J Shoulder Elbow Surg.* 1999;8:569-73.
  9. Gaebler C, McQueen MM, Court-Brown CM. Minimally displaced proximal humeral fractures: epidemiology and outcome in 507 cases. *Acta Orthop Scand.* 2003;74:580-5.
  10. Kralinger F, Gschwentner M, Wambacher M. Proximal humeral fractures: what is semi-rigid? Biomechanical properties of semi-rigid implants, a biomechanical cadaver based evaluation. *Arch Orthop Trauma Surg.* 2008;128:205-10.
  11. Lill H, Hepp P, Korner J. Proximal humeral fractures: how stiff should an implant be? A comparative mechanical study with new implants in human specimens. *Arch Orthop Trauma Surg.* 2003;123:74-81.
  12. Majed A, Macleod I, Bull AM, Zyto K, Resch H, Hertel R, et al. Proximal humeral fracture classification systems revisited. *J Shoulder Elbow Surg.* 2011;20:1125-32.
  13. Resch H, Hübner C, Schwaiger R. Minimally invasive reduction and osteosynthesis of articular fractures of the humeral head. *Injury.* 2001;32:25-32.
  14. Schumaier and Grawe. Proximal Humerus Fractures: Evaluation and Management in the Elderly Patient. *Geriatric Orthop Surg Rehabil.* 2018;9:1-11.

**Cite this article as:** Chandak RM, Sharma M, Jha A. Clinical and radiological outcome of 3- and 4-part proximal humerus fracture managed with J nails in elderly osteoporotic individuals. *Int J Res Orthop* 2021;7:1122-6.