

Case Report

Accessory medial cuneiform bone in a child: unreported site and review of literature

Waleed Saqr¹, Atul Bandi¹, Salman Hasan¹, Maged Mostafa^{1*},
Ahmed Refaat Khamis²

¹Department of Orthopedic Surgery, King Hamad University Hospital, Bahrain

²Department of Orthopedic Surgery, Benha University Hospital, Egypt

Received: 15 June 2021

Accepted: 26 July 2021

*Correspondence:

Dr. Maged Mostafa,

E-mail: maged.mostafa58@gmail.com

Copyright: © the author(s), publisher and licensee Medip Academy. This is an open-access article distributed under the terms of the Creative Commons Attribution Non-Commercial License, which permits unrestricted non-commercial use, distribution, and reproduction in any medium, provided the original work is properly cited.

ABSTRACT

Accessory ossicles of the foot are not uncommon finding in foot radiographs which has confused radiologists and orthopedic surgeons from time immemorial. Occasionally these bones are symptomatic, hindering daily activities of patients. We present a case report of an eleven years old girl with a symptomatic accessory medial cuneiform on the dorsal aspect of left foot. The child was evaluated radiologically and after a trial of failed conservative treatment, she was operated upon. Intraoperatively a superficial nerve on dorsum of this accessory ossicle was found, and the extra bone was excised. This accessory bone was found to be related to medial cuneiform bone at its dorsal and distal surface making to suggest its name as "Os cuneo-I metatarsale-I dorsale". Detailed radiological evaluation is mandatory for identification and exact anatomical localization of the extra bone before proceeding to excision, when non operative treatment fails to relieve the symptoms.

Keywords: Accessory ossicle, Digital nerve, Os cuneo-I metatarsale- I dorsale

INTRODUCTION

Supplementary bones of the foot are common findings on plain radiographs. These bones can be in the form of supernumerary bones, sesamoid bones and accessory ossicles. These bones along with ossification centers in pediatric patients may be a reason for confusion in interpretation of radiographs for radiologists and orthopods. They conventionally originate from unfused accessory ossification centers in the foot.¹

The supplementary bones in the foot often become symptomatic and may affect daily activities of the individual. Diagnosing an accessory bone is a bit of a challenge solely with plain radiographs in pediatric population. Each case should be reviewed individually and planned according to the size and site of ossicle.

CASE REPORT

Eleven years old female child presented, to orthopedic outpatient clinic of King Hamad university hospital (KHUH), with left foot pain for several months that increased over the past 2 weeks before presentation. This pain was of mild to moderate intensity and got worse with activities. No significant history of injury, trauma due to footwear or other precise reason was present at the onset of symptoms. A tender bony hard mass on the dorsum of left foot distal to navicular bone with a pointed sharp end was palpated subcutaneously (Figure 1). Patient had an antalgic gait on presentation. Range of motion of the foot and ankle joints was normal with intact vascularity and there was no distal neurological deficit. No other apparent deformity was noted in her feet or body. Radiographs of the left foot showed a bony shadow on dorsum of distal aspect of medial cuneiform bone. Computed tomography (CT) Scan of the left foot further confirmed the findings

and suggested an accessory bone fused with the mother bone (Figure 2).

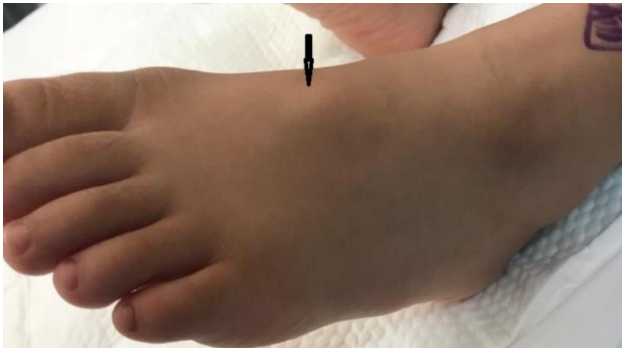

Figure 1: A pre-operative photo of the foot of a bony prominence at the site of pain.

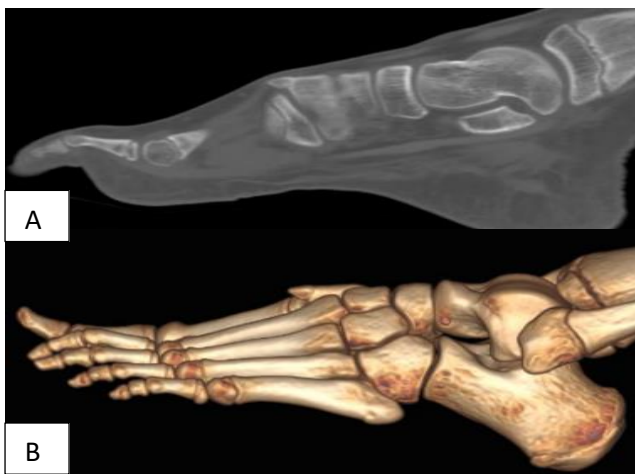


Figure 2: Sagittal CT (A) and sagittal 3D (B) of the extra bone attached to the distal end of medial Cuneiform bone.

A trial of conservative management in the form of analgesics and soft footwear was advised for 3 weeks. As the symptoms did not improve, surgical excision of the accessory ossicle was planned. Surgery was performed under general anesthesia with child in supine position and a pneumatic tourniquet was applied. A longitudinal incision of around 3 cm overlying the swelling was made and the underlying soft tissues were gently separated. A subcutaneous nerve (Figure 3) was identified at dorsum of this ossicle, and was dissected free before the excision of the accessory bone (Figure 4) from the superior surface of medial cuneiform bone. The wound was closed, compression dressing was applied and the patient was advised gradual-weight bearing for 2 weeks following surgery. Histopathological examination of accessory ossicle further verified the diagnosis of accessory bone. Post-operative recovery was uneventful and the patient symptoms gradually subsided and she was completely asymptomatic 3 weeks following surgery and recovered her normal gait.

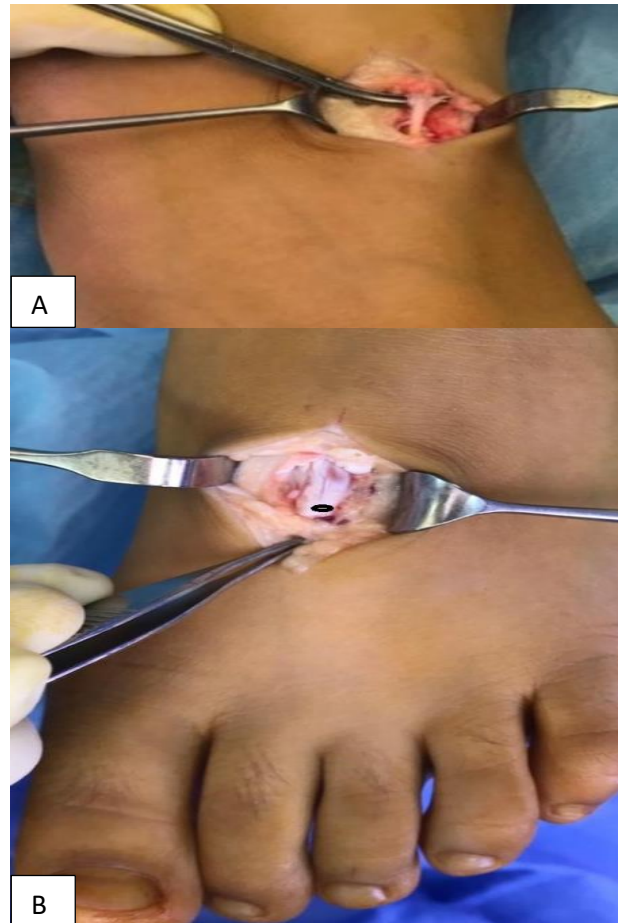


Figure 3 (A and B): Intra-operative photo of the superficial nerve running over the extra bone. The accessory bone before excision.

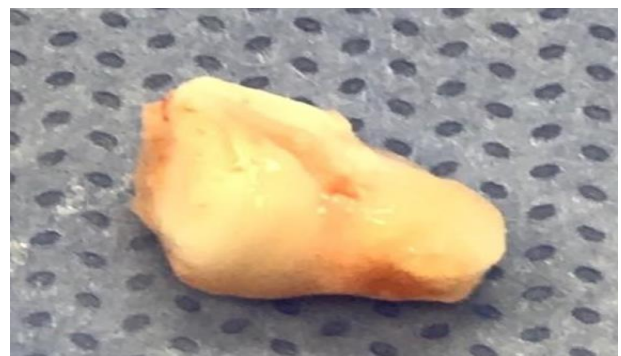

Figure 4: Excised, triangular in shape, accessory medial cuneiform bone.

DISCUSSION

Accessory ossicles of the foot have intrigued orthopedic since time immemorial and have been described in literature before the advent of radiographs.^{2,3} The majority of them remain asymptomatic in general population and is only an incidental finding in radiographs. Lee et al, in 896 healthy feet found a prevalence rate of as high as 49.2% of accessory ossicle bones.⁴ Multiple sites of accessory

ossicle have been described in literature. In 1981 Tsuruta et al studied 3460 radiographs of patients over 7 years of age and described 15 accessory ossicles around foot and ankle region.⁵ In 2017, Keles et al described around 24 types of accessory ossicles of the foot in his review article. Of all the accessory ossicles in the foot, 5 types have been reported around the cuneiform bone namely-os para cuneiforme, os intercuneiforme, os cuneometatarsale-I tibiale, os cuneo-I metatarsale-I plantare and os cuneo-I metatarsale-II dorsale.⁶

Tonogai et al described a case of accessory bone in the distal portion of the navicular and the proximal portion of the intermediate cuneiform.⁷ They presented a 23-year-old female with pain, swelling and tenderness on dorsal aspect of the foot. Intraoperatively, the extra-bone was found to be connected to the navicular and middle cuneiform by synfibrosis and was called os intercuneiform. Kurashige described removal of a painful os paracuneiform.⁸ This was an accessory bone located medial to the medial cuneiform bone where also the distal end of the navicular was found enlarged and with fibrous connections to the extra bone. The patient was 15-year-old boy with hard eminence on the medial side of the foot and was surgically excised. Symptomatic bipartite medial cuneiform was reported in a 32 years old athlete by Chiodo et al.⁹ Surgical exploration revealed a non-cartilaginous articulation between the two osseous segments where the smaller medial one was excised. Our case was distinctive in operative findings compared to the above cases as it showed the presence of triangular piece of accessory bone solely fixed to dorsal distal end of the medial cuneiform without connections or articulation to any adjacent bone.

Our case presented here is also unique in presentation, as the patient is an eleven years-old girl with localized tenderness over a bony prominence located on dorsum of the foot, in the region the medial cuneiform bone. This “point” tenderness can be a result of irritation of the superficial nerve which was found in close proximity and adherent to this bony prominence. It is one of the terminal cutaneous branches of the superficial peroneal nerve. Accessory bone causing neurological symptoms in the foot is quite rare. However, an os intermetatarsium causing compression of the deep peroneal nerve and giving rise to foot paresthesia and pain felt on the dorsum of the foot and the first web space, has been described by Nakasa et al that was also relieved by surgical excision of os intermetatarsium.¹⁰

Although very few case reports have been published regarding accessory bones around the medial cuneiform, no case report is published in English literature describing an accessory ossicle bone attached to the dorsal distal surface of the medial cuneiform bone lying near first metatarsal articular surface. The nomenclature for this

bone thus can be suggested to be: Os cuneo -I metatarsale-I dorsal.

CONCLUSION

In this case study we present the first reported case of Os cuneo -I metatarsale-I dorsale, irritating a cutaneous branch of superficial peroneal nerve. The extra ossicle is directly related to the medial cuneiform without any connection to the adjoining bones. CT of the foot is mandatory for identification and exact anatomical localization of the extra bone before proceeding to excision, when non-operative treatment fails to relieve the symptoms.

Funding: No funding sources

Conflict of interest: None declared

Ethical approval: Not required

REFERENCES

1. Coskun N, Yuksel M, Cevener M, Arican RY, Ozdemir H, Bircan O et al. Incidence of accessory ossicles and sesamoid bones in the feet: a radiographic study of the Turkish subjects. *Surg Radiol Anat.* 2009;31:19-24.
2. Jones S. Right foot showing two internal cuneiform bones. *Trans Pathol Soc.* 1864;15:189-190.
3. Smith T. A foot having four cuneiform bones. *Trans Pathol Soc.* 1865;17:222-3.
4. Lee JH, Kyung MG, Cho YJ, Go TW, Lee DY. Prevalence of Accessory Bones and Tarsal Coalitions Based on Radiographic Findings in a Healthy, Asymptomatic Population. *Clin Orthop Surg.* 2020;12(2):245.
5. Tsuruta T, Shiokawa Y, Kato A, Matsumoto T, Yamazoe Y, Oike T et al. Radiological study of the accessory skeletal elements in the foot and ankle (author's transl). *Nihon Seikeigeka Gakkai Zasshi.* 1981;55(4):357-70.
6. Keles-Celik N, Kose O, Sekerci R, Aytac G, Turan A, Güler F. Accessory ossicles of the foot and ankle: disorders and a review of the literature. *Cureus.* 2017;9(11).
7. Tonogai I, Nishisho T, Takao S, Miyagi R, Yokoyama K, Toki S et al. Symptomatic Os Intercunei form: A Case Report. *J Foot Ankle Surg.* 2018;57(5):997-9.
8. Kurashige T. Removal of Painful Os Paracuneiforme: A Case Report. *Foot Ankle Specialist.* 2020;13(3):236-41.
9. Chiodo CP, Parentis MA, Myerson MS. Symptomatic bipartite medial cuneiform in an adult athlete: a case report. *Foot ankle int.* 2002;23(4):348-51.
10. Nakasa T, Fukuhara K, Adachi N, Ochi M. Painful os intermetatarsium in athletes: report of four cases and review of the literature. *Arch orthop trauma surg.* 2007;127(4):261-4.

Cite this article as: Saqer W, Bandi A, Hasan S, Mostafa M, Khamis AR. Accessory medial cuneiform bone in a child: unreported site and review of literature. *Int J Res Orthop* 2021;7:1032-4.