

Original Research Article

Comparison of functional outcome of extra-articular distal radius fractures treated by volar locking plate versus percutaneous pinning in adults-a retrospective study

Shushrut B. Bhavi, Amith Shanmugouda Kallanagoudar*, Deepak Kaladagi, N. B. Sanakal

Department of Orthopedics, S Nijalingappa Medical College, Bagalkot, Karnataka, India

Received: 03 February 2021

Accepted: 11 March 2021

*Correspondence:

Dr. Amith Shanmugouda Kallanagoudar,
E-mail: amithsk07@gmail.com

Copyright: © the author(s), publisher and licensee Medip Academy. This is an open-access article distributed under the terms of the Creative Commons Attribution Non-Commercial License, which permits unrestricted non-commercial use, distribution, and reproduction in any medium, provided the original work is properly cited.

ABSTRACT

Background: Distal radius fractures are one of the most common fractures in an adult population and accounts for 17.5% of all the fractures. The management of distal radius fractures remains debatable despite the availability of different methods of treatment. The aim of this study is to assess the functional outcomes of extra-articular distal radius fractures treated with percutaneous pinning or internal fixation with volar locking plate in adults.

Methods: A retrospective study of 40 patients diagnosed with distal radius fracture with AO classification were treated either with percutaneous pinning (n=20) or open reduction and internal fixation with volar locking plate (n=20) were included in study. DASH score and radiographs at 6th month was assessed for functional outcome and radiological union.

Results: Mean age in plate group was 40 and 45 years in K wire group. The mean passive wrist ROM at the final follow-up evaluation in plate group was 63.8° extension and 70.5° flexion, 81.7° supination and 79° pronation, compared with 56.75° extension and 65.25° flexion, 74.7° supination and 85.5° pronation in patients treated with K wire group. Patients with plate group and K wire group had DASH score of 19.85 and 18.49 respectively (p=0.07) at 6 months follow-up.

Conclusions: The use of ORIF with plate resulted in stable fixation of the unstable extraarticular fractures, allowing early post-surgical wrist motion and has good radiological outcome whereas K wire also has advantages of being minimal invasive, reduced hospital stay and minimal cost.

Keywords: Distal radius, Volar locking plate, K wire, DASH score

INTRODUCTION

Distal radius fractures are one of the most common fractures of the upper extremity. They account for 17.5% of all the fractures and 75% of forearm fractures.¹ The age distribution for distal radius fractures is typically in elderly females; with a male to female ratio of 1:4.

In 1814, Colles described an extra-articular, dorsally displaced, metaphyseal fracture with radial shortening.² Barton, in 1838, described intra articular fractures with

either volar or dorsal displacement of the distal radius.³ Smith, in 1847, classified volar displaced fractures into three types, based on anatomical description.⁴ However, eponyms provide limited information regarding fracture stability, treatment and prognosis.

Various options of treatment have emerged over the years and these include closed reduction and casting, external fixation, percutaneous pinning and open reduction and internal fixation with plating.⁵ The primary goal of treatment of these fractures is restoration of wrist function.

Good functional outcome requires restoration of the disrupted radial anatomy, maintenance of accurate and stable reduction. There is no standard treatment algorithm for these fractures. Conservative treatment is generally reserved for un-displaced and minimally displaced fracture.

The American academy of orthopedic surgeons (AAOS) clinical practice guideline only suggests surgical treatment when the articular step, after reduction, exceeds 2 mm.

Percutaneous wire fixation is being relatively quick and minimally invasive procedure that could be carried out in limited operative environment. Since the fixation is not rigid, the patients are often having to be immobilized in plaster cast for around 6 weeks and chances of collapse of fracture in osteoporotic bone is higher⁶. This technique can provide adequate fracture stability, and soft-tissue and vascular preservation, in addition to minimal patient morbidity, which may facilitate a more rapid return to function compared with more invasive methods of treatment. Closed reduction and percutaneous pinning are a valuable method in treatment of distal radius fractures.^{6,7}

The locking plate fixation by open reduction helps in better manipulation of the fragments and restoration of the normal anatomy of distal radius. The volar locking plate with screws provides a rigid construct and provides better fixation and accentuates bone healing mechanism. There is a reduced chance of loss of reduction by locking plate mechanism⁶. The patients can be mobilized very early and thereby reduce the incidence of post-operative stiffness and weakness. The visualization of the fracture aids in reduction and maintains the congruity for fracture healing and reduces the chances of malunion, non-union, post-traumatic arthritis. However, this technique requires increased operative time and surgical expertise.

The aim of this study was to compare functional outcomes of extra-articular distal radius fractures which were treated with percutaneous pinning or volar locking plate.

METHODS

The study is a retrospective study conducted at tertiary care center and data was collected from the period of January 2018 to December 2019. Patients details and radiological images obtained from the Operative registry and backup of digital imaging in radiology department. Patients with distal radius fractures operated with either volar plate or K wire who met with inclusion criteria were included in this study. Total of 40 (plate-20 and K wire-20) were included in the study after applying the inclusion/exclusion criteria. Fractures were classified based on AO classification. Patients with closed, unilateral, displaced, extra articular distal radius fractures (AO classification type 2R3A2.2, 2R3A2.3, 2R3A3.1, 2R3A3.2) were included in the study. Patients with open fractures, AO type B and C fractures, bilateral wrist fractures, pathological fractures, and with preexisting wrist arthritis, were excluded.

All procedures were performed in operation theatre using regional anesthesia and were covered with prophylactic intravenous antibiotics. Fixation using percutaneous wires was performed after indirect reduction with traction and manipulation under the guidance of image intensifier. The wires were not buried. All fractures fixed by wiring were given a below elbow cast for 4 weeks. The plaster and K wires were then removed in the outpatient department and all patients were started with wrist mobilization after the removal.

Locking plate fixation was achieved through Henry's volar approach under tourniquet application. The fracture was reduced under direct vision. The fracture was maintained with help of locking plates, these patients were treated with 2 weeks of cock-up splint followed by early mobilization. This group was also started with the rehabilitation of a wrist mobilization.

All patients had regular follow-up. For this retrospective study, the final follow up data (6th month) was used. Functional outcomes were assessed by DASH questionnaire and wrist range of motion was compared between the two groups.

Statistical analysis

The statistical analysis was performed by a medical statistician. Data was summarized as mean, median and SD was calculated. Groups were compared using the student's t test. The $p < 0.05$ was considered as significant. The data was assessed using the statistically by using SPSS version 19.

RESULTS

A total of 40 who met inclusion criteria were included in the study with 20 in plate group and 20 in the K wire group. In our study, average age in plate group was 40 years (20-78 years) and where as in K wire group 45 years (20-76 years) and age distribution is shown in Table 1. Female predominated the male in our study in K wire group than plate group (Table 2). Right sided fracture was seen large in number in plate group (13 out of 20) whereas left sided fracture was large in K wire group (12 out of 20). 40% of the fractures occurred due to road traffic accidents (10 in K wire and 6 in plate), 45 % fractures due to simple fall (7 in K wire and 11 in plate) and 15% due to fall from height (Figure 1). The mean range of motion assessed post operatively in both groups are shown in Table 3.

The outcome result of DASH score at 6 weeks, 3 months and 6 months post-operative follow-up found to be statistically not significant ($p=0.07$) between plate and K wire group (Table 4 and Figure 2). The radiological assessment of the fracture reduction immediate postoperative showed a better result in plate group than K wire, loss of reduction with dorsal angulation in 2 patients treated with K wire and none in plate group which was

statistically significant, but was not statistically significant with rest of the parameters.

Complication was seen though both in plate and K wire group, clinical outcome was comparable among the groups, superficial infection was found with 3 patients in K wire and 2 in plate group, one patient had tendon irritation in plate and 3 patients in K wire had pin loosening with loss of reduction.

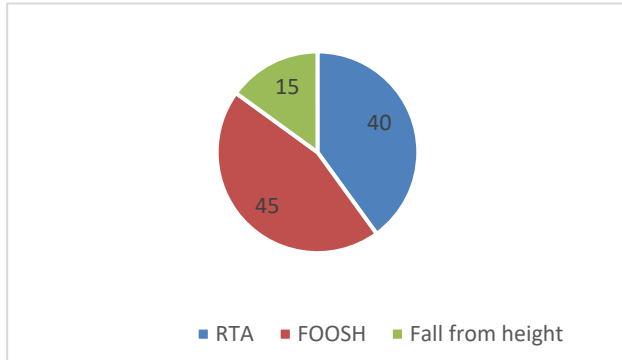


Figure 1 : Percentage of various mode of injury

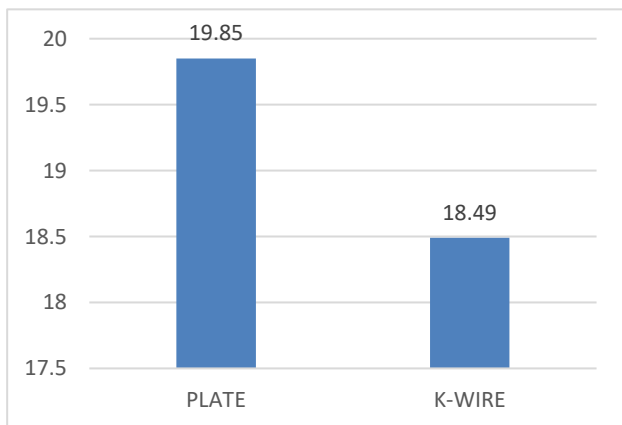


Figure 2 : Bar graph of the average DASH score at the end of 6 months post-operative.

Table 1: Age distribution among the groups.

Age group (years)	Frequency		Percentage (%)	
	Plate	K wire	Plate	K wire
20-30	5	6	25	30
31-40	8	2	40	10
41-50	2	2	10	10
51-60	4	7	20	35
61-70	0	2	0	10
71-80	1	1	5	5

Table 2: Gender distribution among the groups.

Gender	Frequency		Percentage (%)	
	Plate	K wire	Plate	K wire
Female	5	14	25	70
Male	15	06	75	30

Table 3: Average range of motion in both plate and K wire groups.

Type of fixation	Plate	K wire
Mean range of movements		
Mean flexion	70.5	65.25
Mean extension	63.8	56.75
Mean radial deviation	11.0	12.25
Mean ulnar deviation	20.75	22.5
Mean pronation	79	85.5
Mean supination	81.75	74.75

Table 4: Average DASH score at 6 months duration.

DASH score	Plate	K wire
At 6 months	19.85	18.49

Table 5: Frequency of AO type classification of distal radius included among the groups.

AO types	Frequency	
	Plate	K wire
2R3A2.2	4	3
2R3A2.3	8	3
2R3A3.1	6	9
2R3A3.2	2	5

DISCUSSION

Distal radius fracture is a common injury. The importance of anatomic reduction has been demonstrated by clinical studies as well as by laboratory assessment of force and stress studies. Accurate reduction of the fracture is the first step in treatment. Many options are available to maintain this initial reduction. The most common being closed reduction and cast application, but this is often associated with failure and complications.⁶

In a prospective study of 581 patients conducted by Abramo et al, distal radius fractures outcomes protocol treated by various methods, 77% patients were female and 23% were males, 60% were left sided and 40% were right sided, whereas in our study 52.5% were male and 47.5% were females, 52.5% were right sided and 47.5% were left sided patients.²

In a retrospective study conducted by Glickel et al, distal radius fractures with closed reduction and pinning out of 55 patients 33 patients injured their dominant hand and 22 in the non-dominant as compared to our study. Range of motion in their post-operative follow up showed wrist flexion 69, wrist extension 65, wrist radial deviation 22, wrist ulnar deviation 34, forearm pronation 82, forearm supination 81, with mild difference in flexion and supination as of normal limb which was not clinically significant and outcome was measured with DASH score recorded in their final follow-up with average score of 9.7 whereas in our study K wire group shows a DASH score of 19 at 6 months follow up.⁷

In our study, 3 patients had pin loosening at 2 weeks post operatively of which 2 patients had loss of reduction (dorsal angulation), 3 patients had superficial infection at pin site which was treated with antibiotics and wires removed at 6 weeks and 3 patients had residual pain at final follow up in the K wire group whereas prospective study by Das et al, of 32 patients with extra articular distal radius fracture treated by percutaneous pinning 13 patients had pin loosening, 2 had infection, 2 had malunion, 2 had joint stiffness, still author conclude with percutaneous pinning is the good option for distal radius fracture treatment in view of mini procedure, minimal cost, in younger patients and in extra articular fractures.⁸

In a prospective comparison study of 45 patients with extra articular distal radius fractures treated with plate and K wire had a statistically significant ($p < 0.04$) DASH score at 6 months follow-up between the groups, and conclude that plates have a superior and better functional and radiological outcome when compared to K wire group in short term follow up.⁹

Limitations

The sample was small enough to represent the whole population, lack of randomization in the study, retrospective study bias, so there is a need of large study involving the various treatment options for distal radius fractures and the functional outcomes of them.

CONCLUSION

According to our observations in the study, though there was no statistically significant outcome in DASH score between the groups at our final follow up clinically both had pros and cons. In plate group, fixation is stable and post-surgical early mobilization is enabled and loss of reduction is minimal whereas K wire group also has advantages of being minimal invasive, minimal cost and reduced hospital stay and also is a good option when selected in appropriate fracture pattern.

Funding: No funding sources

Conflict of interest: None declared

Ethical approval: The study was approved by the institutional ethics committee

REFERENCES

1. Diaz-Garcia RJ, Chung KC. The evolution of distal radius fracture management: a historical treatise. *Hand Clin.* 2012;28(2):105-11.
2. Colles A. On the Fracture of the Carpal Extremity of the Radius. *Edinb Med Surg J.* 1814;10(38):182-6.
3. Peltier LF. Eponymic fractures: John Rhea Barton and Barton's fractures. *Surgery.* 1953;34:960.
4. Ellis J. Smith's and Barton's fractures: a method of treatment. *J Bone Joint Surg Br.* 1965;47:724-7.
5. Abramo A, Kopylov P, Tagil M. Evaluation of a treatment protocol in distal radius fractures: a prospective study in 581 patients using DASH as outcome. *Acta Orthop.* 2008;79(3):376-85.
6. Gofton W, Liew A. distal radius fractures: nonoperative and percutaneous pinning treatment options. *Orthop Clin North Am.* 2007;38(2):175-85.
7. Glickel SZ, Catalano LW, Raia FJ, Barron OA, Grabow R, Chia B. Long-term outcomes of closed reduction and percutaneous pinning for the treatment of distal radius fractures. *J Hand Surg Am.* 2008;33(10):1700-5.
8. Das AK, Sundaram N, Prasad TG, Thanavelu SK. Percutaneous pinning for non-comminuted extra-articular fractures of distal radius. *Indian J Orthop.* 2011;45(5):422-6.
9. Jagdev, Singh S, Kedia R, Pathak S, Salunke A. Comparison of outcome of extra articular lower end radius fracture with percutaneous pinning and volar locking plate. *Int J Res Orthop.* 2017;3:651-5.

Cite this article as: Bhavi SB, Kallanagoudar AS, Kaladagi D, Sanakal NB. Comparison of functional outcome of extra-articular distal radius fractures treated by volar locking plate versus percutaneous pinning in adults-a retrospective study. *Int J Res Orthop* 2021;7:611-4.