

Original Research Article

Radiological outcome of hamstring graft after anterior cruciate ligament reconstruction with augmentation of bone marrow aspirate concentrate

D. S. Bhamare, Girish Nathani*, Ishan Shevate, Clevio Desouza, Amol Patil

Department of Orthopaedics, Dr. D. Y. Patil Medical College, Hospital and Research Centre, Pune, Maharashtra, India

Received: 29 December 2020

Revised: 02 February 2021

Accepted: 03 February 2021

*Correspondence:

Dr. Girish Nathani,

E-mail: girishnathani786@gmail.com

Copyright: © the author(s), publisher and licensee Medip Academy. This is an open-access article distributed under the terms of the Creative Commons Attribution Non-Commercial License, which permits unrestricted non-commercial use, distribution, and reproduction in any medium, provided the original work is properly cited.

ABSTRACT

Background: Anterior cruciate ligament (ACL) tears are common injuries in the athletic population. Surgical intervention is required for ACL tears as it restores the knee function and it prevents early osteoarthritis. In the recent research there is increasing use of bone marrow aspirate concentrate in orthopaedics. Bone marrow aspirate concentrate (BMAC) provides mesenchymal stem cells progenitor cells and growth factors which has potential benefits in hamstring graft healing after ACL reconstruction.

Methods: This was a prospective randomized case control study carried out between May 2017 and June 2020. 30 patients between age group of 18 to 40 years with complete ACL tear were divided into two groups which consisted of the control group in which only ACL reconstruction was done and second group in which ACL reconstruction was done augmenting it with bone marrow aspirate concentrate. For the BMAC group, 3 ml of BMAC was obtained in the operation theatre itself and was injected into femoral tunnel and the tibia tunnel just before portal suturing. MRI was obtained post operatively at 6 months and at 1 year. Graft healing was seen as the time taken for the graft to reach ligamentization phase when the graft became hyper intense or was visualized similar to PCL or the remnant which was preserved during reconstruction in all cases.

Results: Most of the patients in which augmentation (86%) was done healed at 6 month as compared to those who were not augmented (13%).

Conclusions: BMAC showed faster and better healing of the graft in ACL reconstruction.

Keywords: Anterior cruciate ligament reconstruction, Biological augmentation, Bone marrow aspirate concentrate, Hamstring graft, Ligamentization, Progenitor cells

INTRODUCTION

Anterior cruciate ligament (ACL) tear is one of the most common sports injuries usually occurring in sports like football and basketball.^{1,2} Incidence rate of ACL tear in general population is 60.9 per population.³ Patients with ACL tear if left untreated have increased rate of meniscal injury and early onset of osteoarthritis.⁴⁻⁶ If graft failure occurs after an ACL reconstruction (ACLR), revision ACLR surgery has an inferior outcome.^{1,2,7,8} Therefore

primary ACL reconstruction surgery is very important for maintaining the knee functions.

Allografts have an inferior rate of biological integration rate as compared to autografts.⁹ Therefore, biological augmentation plays an important role to improve ACL reconstructions outcome. In the past few years, bone marrow aspirate concentrate (BMAC), which is high in mesenchymal stem cells (MSCs), progenitor cells and growth factors is used in treatment of osteoarthritis and chondral defects.¹⁰⁻¹²

The purpose of this study was to show the outcome of using BMAC as augmentation in ACL reconstruction and measure the time taken by the graft to heal radiologically.

METHODS

Place of study

This study was conducted at Dr. D. Y. Patil Medical College, Hospital and Research Centre, Pimpri, Pune.

Type of study

It was a prospective randomized case control study.

Period of study

The study took place from May 2017 to June 2020.

Sample size

A total of 30 patients were involved in the study.

Inclusion criteria

Age group between 18 to 40 years. ACL injury with or without meniscal tear. Duration of injury less than 6 months. Full range of movement before surgery.

Exclusion criteria

Previous knee surgery/injury. Joint Infection. Skin lesion in and around knee joints like psoriasis, eczema etc. Metabolic bone disease or on drugs affecting bone turn over like eptoin etc. Patient not willing to sign consent form for this study. Surgery within 3 weeks of injury.

30 patients with isolated ACL tear were selected of both sex with age group between 18 to 40 years and were randomly divided into two group, group A with only ACL reconstruction being performed and group B with augmentation of BMAC along with ACL reconstruction.

Procedure

In both the groups, the patients underwent standard ACL reconstruction under spinal anaesthesia. A tourniquet was applied to keep the arthroscopic view blood free and give better visualization. However in group B 30 ml of bone marrow was aspirated from the ipsilateral iliac crest (Figure 1) after appropriate aseptic measures with the help of an 11 Gauze \times 10 cm bone marrow aspirate needle and a 50 cc syringe pre filled with 5 ml of acid-citrate-dextrose, this aspirate is then centrifuged at 3200 rpm for 15 minutes in a special tube with separate compartments to separate the concentrate (Figure 2). The operative leg was then painted with standard antiseptic solution and then draped from mid-thigh to foot. A standard anterolateral portal was created using a number 11 blade just adjacent to the lateral

border of the patellar tendon at the level of the joint line. The portal was then dilated with the help of a trocar and sheath. The trocar was then removed, and a 30 degree 4.0-mm arthroscope was inserted through the anterolateral portal to perform an arthroscopy. An anteromedial portal was then created just medial to the patellar tendon at the joint line. Standard ACL reconstruction was done after performing a proper diagnostic arthroscopy and debridement of the fat and fibrous tissues. ACL reconstruction was done using a standard quadrupled graft of length 8 cm and width of 9 mm fixed with a femoral suspension with a titanium button and a tibia bio-absorbable screw. 3ml of BMAC was then injected into the femoral tunnel with the help of an 18 G needle through the anteromedial portal and also into the tibia tunnel (Figure 3). The incision was then irrigated and sutured back in the standard fashion. No drain was used.




Figure 1: Aspiration of bone marrow from iliac crest.




Figure 2: Preparation of bone marrow concentrate.

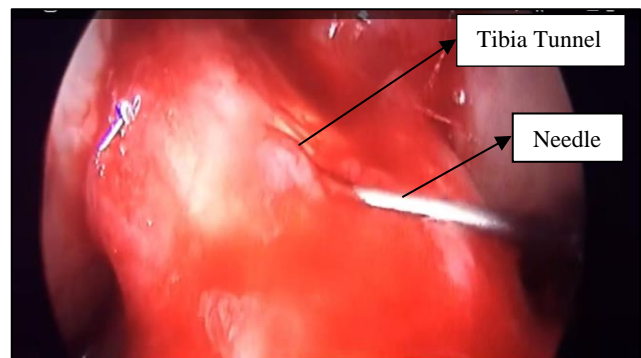


Figure 3: Injection of BMAC into the tibia tunnel.

The leg was kept in functional ROM brace locked in extension for the first 24 hours. Later on the knee was kept in extension only while sleeping and walking full weight bearing with the support of a walker. The patients were encouraged to achieve progressive range of movements up to 90 degrees by 14th day post operatively when sutures were removed. Patients were allowed to walk without walker at 1 month but with a knee brace till 3 months and jogging was started at 4 months postoperatively and sport-specific drills were allowed at 6 months postoperatively. A full return to sports was allowed at 9 months postoperatively.

An MRI scan was done at 6 months and 9 months post operatively for both the groups to see for ligamentization of the graft, tunnel widening, and tunnel position and also to see for any complication.

RESULTS

Both the groups did not differ significantly in terms of age, sex, graft width, graft length, tunnel diameters, fixation devices, and post-operative protocol (Table 1).

Table 1: Mean values of variables in study.

Variables	Min.	Max.	Mean±SD
Age (years)	18	40	30.28±7.576
Time of injury to surgery (months)	1	6	4.08±1.394
Graft length (mm)	115	140	125.95±9.149
Graft width (mm)	6	9	6.93±1.133

The mean age of our study population was 30.28±7.5 years. Mean time of injury to surgery was 4.08±1.3 months. Mean graft length was 125.9±9.1 mm. Mean graft width was 6.9±1.1 mm.

Mean time for graft healing in control group was 8.6 months as compared to 5 months in BMAC augmented groups. Most of the patients in the BMAC augmented group attained ligamentization at 6 months MRI (86.66%) as compared to the control group which was not augmented (13.33%) (Table 2).

Table 2: Results of bone marrow aspirate concentrate.

Groups	Control	BMAC augmentation
Number of patients	15	15
Minimum time for graft healing	6 months	4 months
Maximum time for graft healing	11 months	8 months
Mean time for healing	8.66 months	5.06 months
Percentage of grafts which healed by 6 months	13.33%	86.66%

DISCUSSION

ACL reconstruction is usually done in the younger population with ACL tear using a autograft because it has less re-tear rate as per the old-standard treatment for ACL tears.^{2,13} Proper Graft integration was important for good outcome of the surgery and decreasing the revision rates.^{9,14} In older patient populations in whom the use of an allograft may be preferred because of decreased donor-site morbidity and also less difference in clinical outcome between allografts and autografts in old age.⁹

Osti et al observed that allografts heal and incorporate slowly as compared to autografts.¹³ BMAC can be used for faster incorporation and healing of the graft. US Food and Drug Administration have approved the use of BMAC for stem cell delivery.¹¹ Chahla et al showed positive outcomes when BMAC was used in various places like chondral lesions and early arthritis.¹¹ BMAC provides with MSCs, progenitor cells and various growth factors which have their beneficial effect on tissue healing.¹⁰ Mesenchymal stem cells have been found to provide an environment that fastens regeneration and stimulates angiogenesis.^{15,16} MSC’s have the ability to differentiate into various cells like bone, cartilage, and ligament tissues which fastens the healing process.^{9,16,17}

Significant improvement in function and pain was found in patients of osteoarthritis after injecting BMAC was observed by Kim et al.¹⁰ Oladeji et al noted that use of BMAC in articular cartilage damage show better graft integration when treated with osteochondral allograft along with BMAC.¹⁸ BMAC has shown to improve ACL healing in rat model with partial tears was found by Kenaya et al.¹⁹ Centeno et al also observed the same in a clinical study with partial tears using BMAC improved the function and decreased pain.²⁰

To diagnose the ACL injury and to evaluate reconstruction MRI plays a very important role as it is an accurate and non-invasive tool.^{21,22} MRI can also be used to evaluate the stage of graft healing been used to evaluate stages of ACL graft healing.²³

Youn et al obtained bone marrow from intercondylar notch but it had less mesenchymal cells as compared to bone marrow obtained from iliac crest which was used by Girolamo et al.^{24,25} Therefore we obtained bone marrow from iliac crest. Thus we did a study to see the radiological outcome of the ACL reconstruction with a hamstring graft augmenting it with BMAC, and measuring the time taken by graft to heal by demonstrating ligamentization phase on MRI.

CONCLUSION

Thus by assessing our results in both the groups in our study population we could conclude that BMAC showed faster and better healing of the graft in ACL reconstruction.

Funding: No funding sources

Conflict of interest: None declared

Ethical approval: The study was approved by the institutional ethics committee

REFERENCES

- Borchers JR, Pedroza A, Kaeding C. Activity level and graft type as risk factors for anterior cruciate ligament graft failure. *Am J Sports Med.* 2009;37:2362-7.
- Kaeding CC, Pedroza AD, Reinke EK, Huston LJ, Consortium M, Spindler KP. Risk factors and predictors of subsequent ACL injury in either knee after ACL reconstruction: prospective analysis of 2488 primary ACL reconstructions from the MOON cohort. *Am J Sports Med.* 2015;43(7):1583-90.
- Parkkari J, Pasanen K, Mattila VM, Kannus P, Rimpela A. The risk for a cruciate ligament injury of the knee in adolescents and young adults: A population-based cohort study of 46500 people with a 9 year follow-up. *Br J Sports Med.* 2008;42:422-6.
- Ardern CL, Sonesson S, Forssblad M, Kvist J. Comparison of patient-reported outcomes among those who chose ACL reconstruction or non-surgical treatment. *Scand J Med Sci Sports.* 2016;27:535-44.
- Negahban H, Mazaheri M, Kingma I, van Dieën JH. A systematic review of postural control during single-leg stance in patients with untreated anterior cruciate ligament injury. *Knee Surg Sports Traumatol Arthrosc.* 2014;22:1491-504.
- Chalmers PN, Mall NA, Moric M, Sherman SL, Paletta GP, Cole BJ, et al. Does ACL reconstruction alter natural history? A systematic literature review of long-term outcomes. *JBJS.* 2014;96(4):292-300.
- Chen JL, Allen CR, Stephens TE, Haas AK, Huston LJ, Wright RW, et al. Differences in mechanisms of failure, intraoperative findings, and surgical characteristics between single-and multiple-revision ACL reconstructions: a MARS cohort study. *Am J Sports Med.* 2013;41(7):1571-8.
- Condello V, Zdanowicz U, Di Matteo B, Spalding T, Gelber PE, Adravanti P, et al. Allograft tendons are a safe and effective option for revision ACL reconstruction: a clinical review. *Knee Surg Sports Traumatol Arthrosc.* 2019;27(6):1771-81.
- Desouza C, Nathani G, Bhamare DS, Shevate I. Functional results after anterior cruciate ligament reconstruction using the bone-patella tendon bone method. *Int J Orthop Sci.* 2019;5(4):483-5.
- Kim JD, Lee GW, Jung GH, Kim CK, Kim T, Park JH, et al. Clinical outcome of autologous bone marrow aspirates concentrate (BMAC) injection in degenerative arthritis of the knee. *Eur J Orthop Surg Traumatol.* 2014; 24:1505-11.
- Chahla J, Dean CS, Moatshe G, Pascual-Garrido C, Serra Cruz R, LaPrade RF. Concentrated bone marrow aspirate for the treatment of chondral injuries and osteoarthritis of the knee. *Orthop J Sports Med.* 2016;4:232596711562548.
- Youn GM, Woodall BM, Elena N, Shin EC, Pathare N, McGahan PJ, et al. Arthroscopic bone marrow aspirate concentrate harvesting from the intercondylar notch of the knee. *Arthrosc Tech.* 2018;7:e1173-6.
- Osti L, Buda M, Osti R, Massari L, Maffulli N. Preoperative planning for ACL revision surgery. *Sports Med Arthrosc Rev.* 2017;25:19-29.
- Mall NA, Chalmers PN, Moric M, Tanaka MJ, Cole BJ, Bach Jr BR, et al. Incidence and trends of anterior cruciate ligament reconstruction in the United States. *Am J Sports Med.* 2014;42:2363-70.
- Murrell WD, Anz AW, Badsha H, Bennett WF, Boykin RE, Caplan AI. Regenerative treatments to enhance orthopaedic surgical outcome. *PM R* 2015; 7:S41-S52.
- Desouza C, Nair V, Chaudhary A, Wadhwa N, Gupta S. Arthroscopic staple fixation in the management of displaced anterior cruciate ligament avulsion fractures. *Indian J Orthopaed.* 2018;4(2):121-5.
- Moatshe G, Morris ER, Cinque ME, Pascual-Garrido C, Chahla J, Engebretsen L, et al. Biological treatment of the knee with platelet rich plasma or bonemarrow aspirate concentrates. *Acta Orthop.* 2017;88:670-4.
- Oladeji LO, Stannard JP, Cook CR, Kfuri M, Crist BD, Smith MJ, et al. Effects of autogenous bone marrow aspirate concentrate on radiographic integration of femoral condylar osteochondral allografts. *Am J Sports Med.* 2017;45(12):2797-803.
- Kanaya A, Deie M, Adachi N, Nishimori M, Yanada S, Ochi M. Intra-articular injection of mesenchymal stromal cells in partially torn anterior cruciate ligaments in a rat model. *Arthroscopy.* 2007;35:962-79.
- Centeno C, Pitts J, Al-Sayegh H, Freeman M. Anterior cruciate ligament tears treated with percutaneous injection of autologous bone marrow nucleated cells: a case series. *J Pain Res.* 2015;8:437-47.
- Rak RM, Gillogly SD, Schaefer RA, Yakes WF, Liljedahl RR. Anterior cruciate ligament reconstruction: evaluation with MR imaging. *Radiology.* 1991;178:553-6.
- Maywood RM, Murphy BJ, Uribe JW, Hechtman KS. Evaluation of arthroscopic anterior cruciate ligament reconstruction using magnetic resonance imaging. *Am J Sports Med.* 1993; 21:523-7.
- Anderson K, Seneviratne AM, Izawa K, Atkinson BL, Potter HG, Rodeo SA. Augmentation of tendon healing in an intraarticular bone tunnel with use of a bone growth factor. *Am J Sports Med.* 2001;29:689-98.
- Youn GM, Van Gogh AM, Alvarez A, Yin SS, Chakrabarti MO, McGahan PJ, et al. Stem cell-infused anterior cruciate ligament reconstruction. *Arthrosc Tech.* 2019;8(11):e1313-7.

25. de Girolamo L, Bertolini G, Cervellin M, Sozzi G, Volpi P. Treatment of chondral defects of the knee with one step matrix-assisted technique enhanced by autologous concentrated bone marrow: In vitro characterisation of mesenchymal stem cells from iliac crest and subchondral bone. *Injury.* 2010;41:1172-7.

Cite this article as: Bhamare DS, Nathani G, Shevate I, Desouza C, Patil A. Radiological outcome of hamstring graft after anterior cruciate ligament reconstruction with augmentation of bone marrow aspirate concentrate. *Int J Res Orthop* 2021;7:376-80.