

Original Research Article

Outcome of trapeziectomy with ligament reconstruction tendon interposition for the treatment of advanced thumb carpometacarpal arthritis: a prospective study

Eknoor Kaur*, Narender Saini, Shashank Sharma, Devi Sahai Meena

Department of Orthopedics, SMS medical college and attached Hospitals, Jaipur, Rajasthan, India

Received: 14 December 2020

Accepted: 18 January 2021

***Correspondence:**

Dr. Eknoor Kaur,

E-mail: dr.eknoor@gmail.com

Copyright: © the author(s), publisher and licensee Medip Academy. This is an open-access article distributed under the terms of the Creative Commons Attribution Non-Commercial License, which permits unrestricted non-commercial use, distribution, and reproduction in any medium, provided the original work is properly cited.

ABSTRACT

Background: The purpose of this study is to assess the functional outcome of the cases with advanced thumb carpometacarpal (CMC) arthritis treated with trapeziectomy and ligament reconstruction tendon interposition (LRTI) in terms of visual analogue scale (VAS), disabilities of the arm, shoulder and hand (DASH) score, Kapandji score, range of motion (ROM) of radial and volar abduction of the thumb, grip power, key pinch and the height of the trapezoidal space.

Methods: In a prospective before and after interventional study of 30 patients with the advanced thumb CMC joint arthritis underwent the procedure. An average follow up period was 17.9 months.

Results: The mean VAS decreased from 8.17 to 2.70. The mean Kapandji score and DASH score improved from 3.47 and 71.62 preoperative to 8.23 and 14.46 postoperative. Mean ROM for radial and volar abduction increased from 42.57° and 48° to 61° and 64.73° respectively. Mean key pinch power and grip power increased from 2.80 kg and 3.47 kg to 4.70 kg and 9.01 kg respectively. There was a significant decrease in height of the trapezoidal space. Three patient complaint of the persistent pain at the surgical site and not much improvement in the DASH score.

Conclusions: Trapeziectomy with LRTI using flexor carpi radialis (FCR) transfer is an effective treatment for the advanced thumb CMC arthritis. This procedure stabilizes thumb metacarpal and provide enough support which prevents the collapse of metacarpal into dead space.

Keywords: Thumb carpometacarpal arthritis, Trapeziectomy, CMC arthritis, Flexor carpi radialis, LRTI

INTRODUCTION

Thumb carpometacarpal (CMC) osteoarthritis (OA) is a common degenerative joint disease of the hand. The prevalence of symptomatic thumb CMC OA is 3 to 4 times more common in women as compared to men and presents for clinical care earlier in life than men do.¹ This is perhaps due to differences in reproductive hormones and their effect on the stabilizing ligaments of the joint, or biomechanical differences in joint loading.² The CMC joint of the first ray is a synovial saddle joint which comprises of two major articulations, the trapezio-metacarpal articulation to the thumb and the scapho-

trapezoidal articulation. The CMC joint can be stressed repeatedly in its three main planes of movement: abduction-adduction, flexion-extension, and pronation-supination. As the ligamentous stabilizers of the CMC joint, namely the anterior oblique (volar beak) ligament and the dorsoradial ligament develops laxity, the CMC joint can develop synovitis and wear off the cartilage and eventually degenerative changes appear like joint space narrowing, osteophyte formation, ligament attenuation, and eventual dorsal radial subluxation of the joint.^{3,4} The goal of the treatment for CMC arthritis are to reduce pain and the disability of the patient in carrying out the activities of daily living. The surgical option that is chosen should address the pain generated by bone-on-bone

contact and also restore the normal tension of the volar beak ligament. This restoration helps to reposition the thumb metacarpal in its anatomic position, yielding increased mechanics of the thumb. Operative techniques that address these criteria include the LRTI. In our study we assessed the clinical and radio graphic outcomes of trapeziectomy with LRTI for the treatment of advanced thumb CMC.

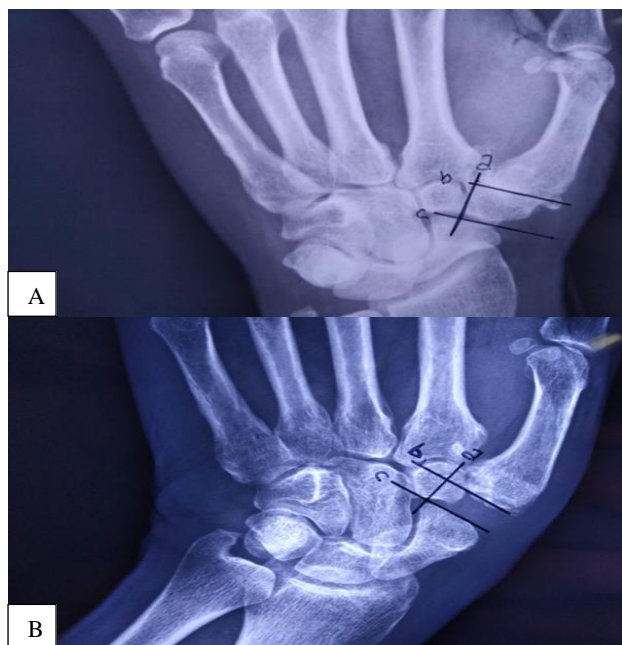


Figure 1: Radiograph of a 60 years old male with bilateral thumb CMC arthritis. (A) depicts preoperative radiograph of left side. (B) depicts the one year follow up of the same patient of decrease in the CMC space. Patient had improved VAS and DASH scores. He had Kapandji score of 9. The patient was motivated then to get his right side operated.

METHODS

This is a prospective before and after interventional study of 30 patients with the advanced thumb CMC joint arthritis who underwent the procedure from October 2017 to November 2019 in the department of orthopaedics, Sawai Man Singh Medical college and Hospital, Jaipur. The inclusion criteria for the study were 1) Patient belonging to Eaton stage III or IV. 2) Patient age was more than 18 years. 3) Failure of the conservative therapy. The exclusion criteria were 1) Patient with rheumatoid arthritis. 2) Patient having history of hand surgery. 3) Patients with wrist arthritis, carpal fractures, non-unions and avascular necrosis. The mean follow up time was 17.9 months (range 6- 26 months). Visual analogue scale (VAS), disabilities of the arm, shoulder and hand (DASH), Kapandji score, grip power, pinch power, radial and volar abduction angle were assessed for each patient preoperatively and at the subsequent follow-ups. Grip strength was determined using a hand dynamometer and

pinch power was determined using hydraulic pinch gauge. The radial and volar abduction angle were measured using a goniometer was assessed. Radiologically, the height of the trapezial space preoperative and at post-surgical follow ups. The height of CMC space was measured as the distance between the distal scaphoid and the base of first metacarpal. Line (a) is the line drawn through the radial articular surface of the index metacarpal and the trapezium. Line (b) is the line tangent to the first metacarpal base and perpendicular to the line (a). Line (c) is the line tangent to the distal most part of the scaphoid and perpendicular to the line (a). The distance between line (b) and (c) is the height of the CMC space (Figure 1). In surgery a regional block was given. The arm was prepared and draped in a routine sterile fashion. A tourniquet was inflated to 250 mmHg. The trapezio-metacarpal joint was approached through a curvilinear incision in the anatomical snuffbox. Care was taken not to injure superficial branch of the radial nerve and the radial artery (Figure 2 A and B). The first extensor compartment was identified. The abductor pollicis longus was retracted volarly and the extensor pollicis longus was retracted dorsally (Figure 2 C). The CMC capsule was capsulotomies and dissected off volarly and dorsally for later repair (Figure 2 D). The trapezium was identified. An osteotome was used to osteotomized the trapezium. The trapezium was removed in piecemeal fashion. Traction was given to the thumb and scaphotrapezoidal joint was evaluated for degenerative changes (Figure 2 E and F). It becomes necessary to reconstruct the beak ligament by FCR transfer and to restore the suspension of metacarpal base. A small incised was given about 10 cm proximally to the palmer wrist crease over the FCR tendon. The proximal tendon was cut halfway across its width. Half of the tendon was stripped free of the remaining portion of the FCR and brought out through the distal incision, maintaining its insertion site at the index metacarpal base (Figure 2 G). A hole was drilled through the thumb metacarpal base. The free FCR tendon retrieved distally was passed through the shaft and out the dorsal aspect of the first metacarpal, utilizing the previously drilled passage. The tendon was tensioned, allowing the metacarpal to assume an abducted and slightly flexed position and secured in place with prolene 3-0 (Figure 2 H). The rest of the tendon was tied and rolled up like a ball and put into the space where trapezium was previously located. The capsule and subcutaneous tissue was closed with vicryl 3-0. Skin closure was done, and a thumb spica splint was applied. A post-operative dressing was done usually within 2 weeks of surgery. A cast was then placed with first metacarpal in palmar abduction, metacarpophalangeal joint in ~10-20 degrees flexion, wrist neutral, interphalangeal joint free for next 4 weeks. Functional exercises were started after 6 weeks postoperative. All the measurement data were presented as the mean \pm standard deviation when data satisfied criteria for normality with $p < 0.05$. The statistical analysis between preoperative and final follow up data was performed using student's paired t-test. A p value of 0.05 was statistically significant. Approval from ethical committee was taken.

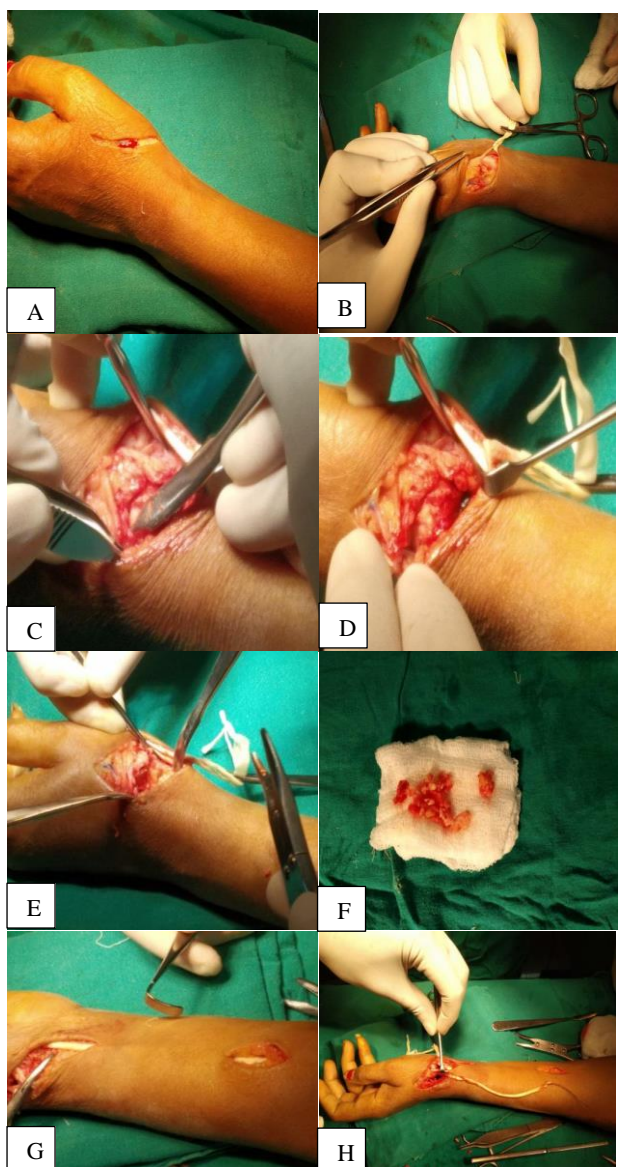


Figure 2:(A) A curvilinear incision is given in the anatomical snuffbox. (B) The superficial branch of the radial nerve is isolated. (C) The abductor pollicis longus is retracted volarly and the extensor pollicis longus was retracted dorsally. (D) Capsulotomy is done. (E) Trapezium is removed in piecemeal fashion. (F) Osteophytes removed. (G) Incisions given over the forearm to harvest FCR. (H) The free FCR tendon is retrieved distally and passed through the hole drilled in the base of first metacarpal.

RESULTS

Results were obtained of 30 patients out of which 23 females and 7 males were studied. Their mean age was 54.43 years old. The mean value of VAS, DASH, Kapandji, ROM of radial abduction, ROM of volar Abduction, grip power, key pinch and height of the trapezial space were evaluated pre-operatively and post-operatively and follow-up. The average VAS and DASH score decreased from 8.17 to 2.70 and 71.62 to 14.46

respectively, while Kapandji score increased from 3.47 to 8.23. The ROM of Radial abduction and Volar abduction increased from 42.57% to 61.00% and 48.00% to 64.73% respectively (Table 1) The grip power and key pinch also increased while height of the trapezial space decreased.

Table 1: Preoperative and follow up variables between 2 groups.

Variables	Preoperative	Follow up	P
Age (year)	54.43±8.60	54.43±8.60	
Gender	23/7	23/7	
VAS	8.17±1.12	2.70±1.47	<0.001
DASH	71.62±7.61	14.46±10.78	<0.001
Kapandji	3.47±0.86	8.23±1.41	<0.001
ROM of radial abduction	42.57±5.64	61.00±7.32	<0.001
ROM of volar abduction	48.00±6.68	64.73±7.73	<0.001
Grip power	3.47±0.99	9.01±3.22	<0.001
Key pinch	2.80±0.73	4.70±1.09	<0.001
Height of the trapezial space	10.32±0.72	9.40±0.91	<0.001

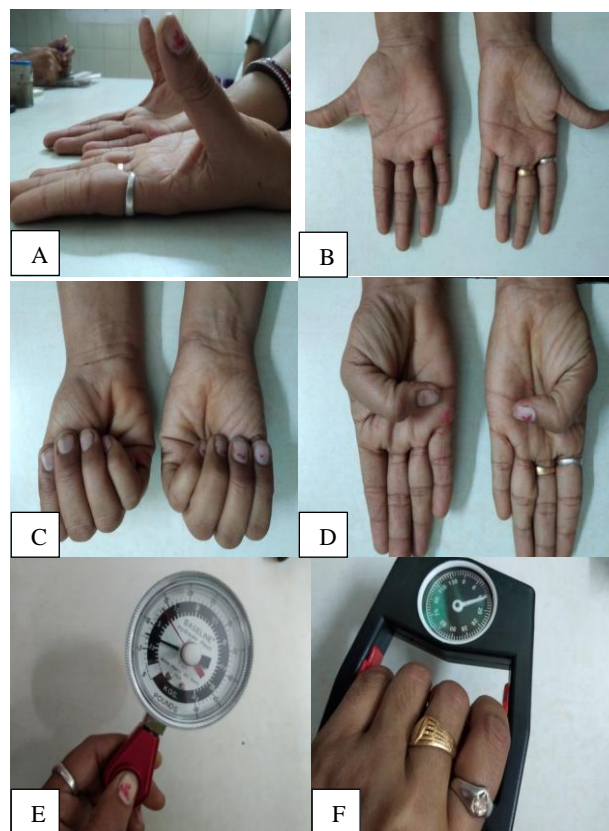


Figure 3: 12 months post-surgical follow up. (A) ROM of volar abduction=56°, (B) ROM of radial abduction=55°, (C) Painless grip, (D) Kapandji score=9, (E) Pinch grip 3.5 kg, (F) grip power 13 kg.

DISCUSSION

Thumb carpometacarpal (CMC) arthritis is becoming a highly prevalent chronic problem among the ageing population. According to ring and colleagues the prevalence of thumb CMC arthritis is 91% in the patients over the age of 80 years, with complete destruction of the joint and the problem is three times more prevalent among the females as compared to males.⁵ In a study by Armstrong and colleagues where 143 postmenopausal women were studied, the prevalence of thumb CMC OA was 25%.⁶ It has become one of the leading conditions for which surgery of the hand is done. A number of surgical procedures are employed for the reconstruction of the arthritic thumb CMC joint. Earlier reconstruction primarily involved arthrodesis. But now a day's arthroplasty is becoming a popular procedure.

We compared our studies with other studies (Table 2). In our study we used the method similar to procedure described by Burton and Pellegrini in 1984.⁷ A part of this procedure was described by Eaton and Littler for reconstruction of the deep anterior oblique ligament. The procedure consists of resection of the trapezium and a portion of the flexor carpi radialis (FCR) is used to reconstruct the deep anterior oblique ligament similar to described by Eaton and Littler and the remaining tendon is used to fill the void left by the resection of the trapezium, also known as interposition arthroplasty.⁸ This procedure provides support and resists subsidence of the thumb metacarpal. We studied 30 thumbs with advanced thumb carpometacarpal arthritis belonging to Eaton stage III and IV. In our study the youngest patient was 30 years old and the oldest patient was 68 years old. The mean age of presentation was 54.43. In a study by Wang et al 20 patients were included in their study.⁹ The mean age in their study was 54.1 years old. In our study out of 30 patients 7 were males (23.33%) and 23 were females (76.67%). In a study by Wolf et al out of 20 patients, 13 were women (65%) and 7 were men (35%). Possible explanations for the greater susceptibility to the development of first CMC joint arthritis in women is perhaps due to differences in reproductive hormones and their effect on the stabilizing ligaments of the joint, or biomechanical differences in joint loading. In our study the mean VAS score declined from 8.17 before surgery to 2.70 on an average 17.9 months follow up. Out of 30 patients three patient was not very satisfied at follow up. In a study by De Smet et al who studied 31 thumbs treated with trapeziectomy and LRTI with a mean follow-up of 24 months (range: 8-46 months) twenty-six (84%) of patients were satisfied or very satisfied and 5 (16%) were not.¹⁰ Pain was reduced on average of 75%. In our study the mean DASH score improved from 71.62 preoperatively to 14.46 on an average 17.9 months follow up. Wang et al studies showed that mean DASH score improved from 52.2 preoperatively to 21.6 at 2 years follow up. In a study by De Smet et al the average DASH score was 28.7 at mean 24 months follow up. After the surgical intervention and proper rehabilitation most of the patients in our study

were able to carry out the activities of daily living without any pain after 6 months. Most of the women in our study were able to carry out their daily household activities like kneading dough, cutting vegetables, opening and closing the lid of a jar, carrying moderately heavy objects, combing hair, etc except milking the cow and almost all women in our study complained of the same problem. In our study the mean Kapandji score improved from 3.47 preoperatively to 8.23 on an average 17.9 months follow up. The mean Kapandji score improved from 6.4 to 7.4 at 2 years follow up in a study done by Wang et al. In a study by Li et al where 17 patients were operated upon with the same procedure the mean score increased from 6.9 preoperative to 7.5 postoperative.¹¹ Improvement in Kapandji score indicates good thumb opposition function hence patients were able to hold the pen to write, open and close the lid of a jar, turn a doorknob, tie a knot, turning the key etc, after the surgical intervention. Therapy putty and opening the clothespin were included in the rehabilitation phase to improve the thumb opposition. In our study the mean ROM of radial and volar abduction improved from 42.57° and 48.00° preoperatively to 61.00° and 64.73° on an average 17.9 months follow up. The mean ROM for radial and volar abduction improved from 61.2° to 80.1° and from 60.6° to 78.3° respectively after the surgical intervention in a study by Wang et al. Improved ROM of volar and radial abduction leads to a good thumb-index web angle which is necessary for grasping all types of objects, in particular for spherical and pinching grips. Any loss of amplitude affects these grips. One of the patients in our study had overall improved DASH and Kapandji score, decrease in the VAS score, improved strength in grip power and key pinch, improved ROM in volar abduction but her radial abduction was restricted. This could be explained by over tensioning of the FCR tendon while reconstructing the volar apical ligament which inhibited the radial abduction of the thumb. This thumb behaved like an arthrodesis thumb. In our study the mean grip power improved from 3.47 kg preoperative to 9.01 kg on an average 17.9 months follow up. The mean grip power improved from 15.9 kg preoperatively to 21.7 kg at 2 years follows up in the study by Wang et al. In our study the mean key pinch strength improved from 2.8 kg preoperatively to 4.70 kg at follow up. The mean key pinch strength improved from 1.9 to 3.5 kg in the study by Wang et al. Although there was an improvement in key pinch strength as compared to the preoperative stage, but the strength could not be attained as the normal contralateral side. This can be explained by post-operative thumb shortening and instability which affects the pinch strength. Hyperextension of the metacarpophalangeal joint of the thumb is also responsible for the lax thumb column which makes it difficult to perform various grip like key pinch and spherical grip. The mean height of the trapezium space preoperatively and at follow up was 10.30 and 9.40 mm respectively in our study. There was no significant sinking in height of the trapezium space from 10.0 mm preoperatively to 9.6 mm at follow up in the study done by Wang et al. The mean difference in the trapezium height was 1.2 mm at one year

follow up in the study by Bhat et al.¹² In our study the decrease in the trapezial height was constant and was found in all patients. The reduction in the trapezial space can lead to hyperextension of metacarpophalangeal joint and reduced first web space which contributes to the reduction in grip strength. In our study three patients complained of persistent pain at the surgical site. This is attributed to the formation of painful neuroma in the superficial branch of radial nerve. Viny comb and Crock found the most common symptom at follow up to be

weakness with 9 of 15 patients (60%) reporting weakness.¹³ De Smet et al mentioned 3 complications in their study of 31 thumbs. One patient developed a radial nerve neuroma, one developed severe rotator cuff tendonitis and a third patient developed a Dupuytren's contracture. Other potential complications reported in the literature include dysfunction of the superficial radial nerve and palmar cutaneous branch of the median nerve, FCR pulling sensation, and complex regional pain syndrome.¹⁴

Table 2: Comparison between our studies and previous various studies.

Studies and mean follow up period	Mean (age year)	Gender (f/m)	Mean VAS	Mean DASH	Mean Kapandji	Mean ROM radial ab (in ^o)	Mean ROM volar ab (in ^o)	Mean key pinch (kg)	Mean grip power (kg)	Mean height of CMC space (mm)
Our study, 17.9 months	54.43 (29-68)	23/7	8.17 → -2.7	71.62 → 14.46	3.47 → 8.23	42.57 → 61	48 → 64.73	2.8 → 4.70	3.47 → 9.01	10.32 → 9.40
Wang et al⁹, 2 years	54.1	13/7	6.8 → 1.4	52.2 → 21.6	6.4 → 7.4	61.2 → 80.1	60.6 → 78.3	1.9 → 3.5	15.9 → 21.7	10 → 9.6
Trumble et al¹⁵, 56 months	64 (40-88)	48/10	Post op= 4.8	Post op=11	--	48 → 50	44 → 51	3.2 → 5.2	15.6 → 22.9	12 → 9.5
De Smet et al¹⁰, 25 months (8-52)	57 (46-69)	28/2	Post op= 2.5	Post op= 28.7	Post op=9.3	Web angle=84 → 87°		4.6 (2 to 8.5) → 5 (2 to 8)	15 (4 to 32) → 26 (4 to 55)	10 (8 to 12) → 6 (3 to 10)
Li et al¹¹, 2.5 years (12 months to 4 years)			5.2 → 0.4	39.8 → 4.3	6.9 → 7.5	46.6 → 52.6	54.8 → 58.9	5.6 → 7.2	14.8 → 24.6	

CONCLUSION

LRTI is a reliable and effective procedure for treating carpometacarpal osteoarthritis of the thumb in the aged patients who faces difficulty in carrying out activities of daily living. The procedure has high patient satisfaction rate and there is objective improvement in the grip and pinch strength and thumb abduction and opposition. Although the preoperative trapezial height is not maintained at follow up but the procedure provides stable thumb with little subluxation with good clinical outcome. Proper physical therapy is needed post operatively to achieve good thumb range of motion and strength. LRTI is a good procedure in the terms of pain and functional outcomes.

ACKNOWLEDGEMENTS

Author would like to thank friend Dr. Agrima Bansal who is a resident in radiology department who helped me out in

getting radiographs of the patients. Also like to thanks senior Dr. Vikrant Shekhawat who guided me throughout the paper writing.

Funding: No funding sources

Conflict of interest: None declared

Ethical approval: The study was approved by the institutional ethics committee

REFERENCES

1. Wolf J, Turkiewicz A, Atroshi I, Englund M. Prevalence of doctor-diagnosed thumb carpometacarpal joint osteoarthritis: An analysis of Swedish health care. Arthritis Care research. 2014;66:961-7.
2. Cooney WP III, Chao EY. Biomechanical analysis of static forces in the thumb during hand function. J Bone Joint Surg Am. 1977;59:27-36.

3. Barron OA, Glickel SZ, Eaton RG. Basal joint arthritis of the thumb. *JAAOS.* 2000;8(5):314-23.
4. Berger B, Linscheid RL. Arthroplasty in the Hand and Wrist. In: Green DP, Hotchkiss RN, Pederson WC, Wolfe SW editors. *Green's operative hand surgery.* 5th ed. Amsterdam: Elsevier. 2007.
5. Sodha S, Ring D, Zurakowski D, Jupiter JB. Prevalence of osteoarthritis of the trapeziometacarpal joint. *J Bone Joint Surg Am.* 2005;87(12):2614-8.
6. Armstrong AL, Hunter JB, Davis TR. The prevalence of degenerative arthritis of the base the thumb in post-menopausal women. *J Hand Surg.* 1994;19(3):340-1.
7. Burton RI, Pellegrini VD. Surgical management of basal joint arthritis of the thumb. Part II: Ligament reconstruction with tendon interposition arthroplasty. *J Hand Surg Am.* 1986;11(3):324-32.
8. Eaton RG, Glickel SZ, Littler JW. Tendon interposition arthroplasty for degenerative arthritis of the trapeziometacarpal joint of the thumb. *J Hand Surg.* 1985;10:645-54.
9. Wang T, Zhao G, Yong-Jun R, Mi J. Outcomes of modified trapeziectomy with ligament reconstruction tendon interposition for the treatment of advanced thumb carpometacarpal arthritis Two-years follow up. *Wolters Kluwer Health. Inc Medicine* 2018;97:13(e0235).
10. De Smet L, Vanfleteren L, Sioen W, Spaepen D, Ransbeeck HV et al. Ligament reconstruction/tendon interposition arthroplasty for thumb basal joint osteoarthritis preliminary results of a prospective outcome study. *Acta Orthop Belg.* 2002;68:20-3.
11. Li J, Li D, Tian G, Zhang W. Comparison of arthrodesis and arthroplasty of Chinese thumb carpometacarpal osteoarthritis. *J Orthop Surg Res.* 2014;14:404.
12. Bhat M, Davis T, Bannerjee A. Trapezial space height measurement after trapeziectomy: A comparison of the use of standard and stress radiographs. *J Hand Surg.* 2003;28A:390-96.
13. Vinycomb T, Crock J. Trapeziectomy with ligament reconstruction and tendon interposition: a minimum 10-year follow-up. *Hand Surg.* 2013;18:365-8.
14. Tomaino MM, Coleman K. Use of the entire width of the flexor carpi radialis tendon for the ligament reconstruction tendon interposition arthroplasty does not impair wrist function. *Am J Orthop.* 2000;29:283-4.
15. Trumble T, Rafijah G, Heaton D. Thumb carpometacarpal arthroplasty with ligament reconstruction and interposition costochondral arthroplasty. *J Wrist Surg.* 2013;2(3):220-7.

Cite this article as: Kaur E, Saini N, Sharma S, Meena DS. Outcome of trapeziectomy with ligament reconstruction tendon interposition for the treatment of advanced thumb carpometacarpal arthritis: a prospective study. *Int J Res Orthop* 2021;7:252-7.