

Case Report

A rare case of patellar fracture with quadriceps tendon rupture

K. N. Subramanian, Ganesan G. Ram, Muthukumar S., Mathiyazhagan Babu*

Velammal Medical College, Madurai, Tamil Nadu, India

Received: 02 November 2020

Revised: 15 December 2020

Accepted: 16 December 2020

***Correspondence:**

Dr. Mathiyazhagan Babu,

E-mail: doc.mathi99@gmail.com

Copyright: © the author(s), publisher and licensee Medip Academy. This is an open-access article distributed under the terms of the Creative Commons Attribution Non-Commercial License, which permits unrestricted non-commercial use, distribution, and reproduction in any medium, provided the original work is properly cited.

ABSTRACT

Quadriceps tendon rupture is the rarest injury with an incidence of 1.37/1,00,000/year. A patellar fracture is the most common injury associated with extensor mechanism lag, but it is rarely found to have quadriceps rupture rather than patellar tendon rupture. Normally when patella fracture occurs the force is disseminated at the bone level rather than at the muscular level. In this case, the force has disseminated at both muscle and bone leading to fracture of patella and quadriceps tendon rupture. Here we report a case of patellar fracture along with quadriceps tendon rupture.

Keywords: Quadriceps tendon rupture, Patellar fracture, Suture anchor, Extensor lag, Patella tendon

INTRODUCTION

A 22-year-old male patient came to the outpatient department with a history of not able to extend the knee and difficulty in walking for the past 6 months. The patient gives a history of a road traffic accident (skid and fall) while riding a two-wheeler 6 months ago and sustained injury to the left knee. Since then he was not able to extend his knee. He was diagnosed to have left patellar fracture (transverse) for which he had treated with tension band wiring and cerclage of the patella. Even after fixation, he found difficulty in extending the leg. Patient had undergone a course of physiotherapy exercise but could not achieve the expected result. On examination of the left knee, a gross quadriceps wasting was observed. The patient could actively flex his knee up to 120 degrees but cannot actively extend the knee. Passive extension was pain-free.

CASE REPORT

Patient was investigated with MRI and diagnosed to have quadriceps tendon rupture near its patellar attachment. Patient was planned for quadriceps repair with implant exit. Intraoperatively the quadriceps tendon attachment in

the superior border of the patella was found to be degenerated and had a palpable gap (Figure 1). The unhealthy tendon is excised and using suture anchors, the tendon is attached to the posterior surface of the patella and the extensor mechanism was restored (Figure 2-3).^{1,2} Patient was immobilized using a knee brace and patient was able to do straight leg raising with knee brace in the immediate postoperative period. Patient was immobilized during the postoperative period. Later physiotherapy was initiated and patient was able to extend the knee fully now.

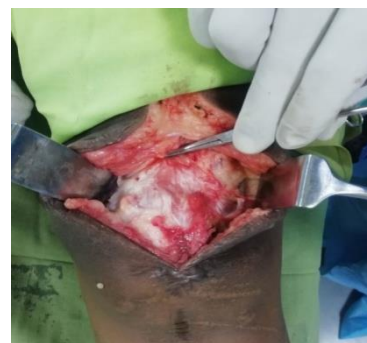

Figure1: Ruptured quadriceps tendon.

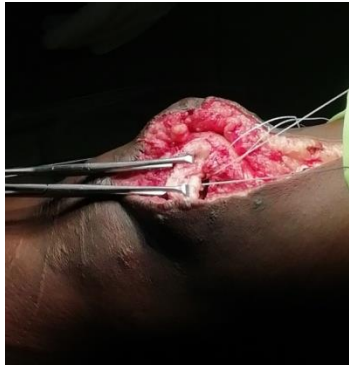


Figure 2: Quadriceps repair with the suture anchor.

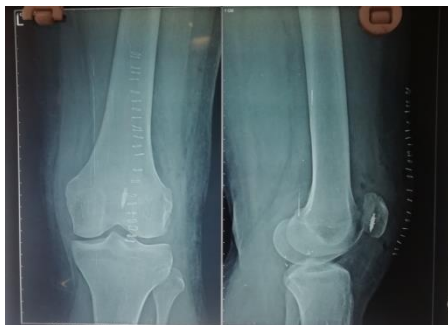

Figure 3: Post operative X-ray with suture anchor.

DISCUSSION

The knee extensor mechanism comprises the quadriceps tendon, patella, and patellar tendon.³ Patellar fractures are the most common cause of disruption to the knee and extensor mechanism followed by quadriceps and patellar tendon ruptures. But it is rare that the same individual is having both patella fracture and quadriceps rupture. Patellar fractures can occur as a result of a direct blow to the knee or as a result of a tension load when the musculotendinous forces across the knee exceed the strength of the bone. But it is rare to have a tension load of quadriceps exceeds the patella strength when an individual has a direct blow to the patella. The quadriceps tendon is a coalescence of the tendinous portions of the rectus femoris, vastus intermedius, vastus lateralis, and vastus medialis muscles (the quadriceps). The muscle fibers from the quadriceps blend with its tendinous portion approximately 3 cm proximal to the superior border of the patella. The tendinous portion is hypovascular which makes it vulnerable to poor healing. The rupture runs through the rectus muscle. The mechanism of quadriceps tendon tear is a deceleration event with the knee in partial flexion and a strong concentric quadriceps contraction against a planted lower extremity.⁴ Tendon rupture usually is the result of underlying tendinitis or a weakened tendon. Certain medical conditions can predispose an individual to tendon rupture as well. There is usually the diagnostic triad of pain, inability to actively extend the knee, and a suprapatellar gap. Despite these relatively apparent signs and symptoms, the diagnosis of quadriceps tendon

rupture may sometimes initially be missed. Delay in diagnosis and treatment has been shown to cause significant morbidity. Conservative management somehow helps in partial tears but the surgical repair has been proven with better outcomes when compared with non-surgical management. Loss of knee motion is one of the most common complications after quadriceps tendon repair. Another complication associated with the repair of the quadriceps tendon is extensor weakness, in which the quadriceps muscle undergoes atrophy, leading to an extensor lag. Using functional surveys and objective testing, Konrath et al studied 51 quadriceps tendon ruptures in 39 patients.⁵ They reported that 92% were satisfied and that 84% returned to their previous occupations. However, 51% were unable to return to the same presurgery level of recreational activity. There was a 12% strength loss in the quadriceps tendon and 14% in the hamstrings, as well as an 8° loss of range of motion. Siwek and Rao reported that 75% of their patients who underwent acute repair of ruptured quadriceps tendons had persistent quadriceps atrophy of 2 to 4 cm.⁶

CONCLUSION

The knee extensor mechanism can be disrupted as a result of either a patellar fracture or a rupture of the patellar or quadriceps tendon. The complete disruption that doesn't allow achievement of straight leg raise or active knee extension requires surgical intervention to restore mobility and function. Early diagnosis and prompt repair are inevitable to obtain better outcomes. But in this above-mentioned case, it was quite rare to have both patellar fracture and quadriceps rupture. So clinicians should think in the back of their mind regarding concomitant quadriceps rupture while dealing with patella fracture.

Funding: No funding sources

Conflict of interest: None declared

Ethical approval: Not required

REFERENCES

1. Clayton RA, Court-Brown CM. The epidemiology of musculoskeletal tendinous and ligamentous injuries. *Injury*. 2008;39(12):1338-44.
2. Richards DP, Barber FA. Repair of quadriceps tendon ruptures using suture anchors. *Arthroscopy*. 2002;18(5):556-9.
3. Bui CN, Learned JR, Scolaro JA. Treatment of patellar fractures and injuries to the extensor mechanism of the knee: a critical analysis review. *JBJS Rev*. 2018;6(10):e1.
4. Nielson J, Gerbino P. *Shoulder Injuries. Clinical Sports Medicine: Medical Management and Rehabilitation*. 1st ed. Netherlands: Elsevier; 2007: 343.
5. Konrath GA, Chen D, Lock T, Goitz HT, Watson JT, Moed BR, D'Ambrosio G. Outcomes following

- repair of quadriceps tendon ruptures. *J Orthop Trauma*. 1998;12(4):273-9.
6. Siwek CW, Rao JP. Ruptures of the extensor mechanism of the knee joint. *J Bone Joint Surg Am*. 1981;63(6):932-7.

Cite this article as: Subramanian KN, Ram GG, Muthukumar S, Babu M. A rare case of patellar fracture with quadriceps tendon rupture. *Int J Res Orthop* 2021;7:406-8.