

## Case Report

# Ulnar longitudinal deficiency: a rare case report and review

Akshay Lamba<sup>1\*</sup>, Naresh Kumar<sup>1</sup>, Chaitanya Krishna<sup>2</sup>, Sargam Chhabra<sup>3</sup>

<sup>1</sup>Department of Orthopaedics, B. P. S. Government Medical College, Haryana, India

<sup>2</sup>Consultant, Healthworld Hospital, Durgapur, West Bengal, India

<sup>3</sup>Department of Ophthalmology, Pt. B. D. S. PGIMS, Rohtak, Haryana, India

**Received:** 22 September 2020

**Revised:** 11 November 2020

**Accepted:** 12 November 2020

### \*Correspondence:

Dr. Akshay Lamba,

E-mail: [aslamba@gmail.com](mailto:aslamba@gmail.com)

**Copyright:** © the author(s), publisher and licensee Medip Academy. This is an open-access article distributed under the terms of the Creative Commons Attribution Non-Commercial License, which permits unrestricted non-commercial use, distribution, and reproduction in any medium, provided the original work is properly cited.

### ABSTRACT

Ulnar hemimelia is a rare postaxial partial or complete longitudinal deficiency of ulna. It has an estimated incidence of 1/100,000-150,000 live births, with a male to female ratio of 3:2. There is usually ulnar deviation of hand and shortening of forearm. Radial head subluxation and fixed flexion deformity of the hand may be associated with it. Complex carpal, metacarpal, and digital abnormalities including absence of triquetrum, capitate and three fingered hand (tridactyly) are additional findings commonly found in association. Here, we present a case of a 17-year-old female with left sided ulnar club hand due to isolated partial ulnar aplasia.

**Keywords:** Aplasia, Ectromelia, Hemimelia, Ulna, Upper extremity deformities, Congenital

### INTRODUCTION

Ulnar hemimelia is a rare congenital upper limb anomaly characterized by complete or partial absence of the ulna bone. Isidore Geoffroy Saint-Hilaire coined the term "hemimelia" in the early 19th century, while in 1951, O'Rahilly suggested the term "paraxial hemimelia" for the longitudinal variety, because either the preaxial or postaxial side of the limb is involved.<sup>1</sup> Incidence is estimated at 1/100,000-150,000 live births, with a male to female ratio of 3:2. Ulnar hemimelia is rarer than its radial counterpart. It occurs in about 1 in 1.5 million population. Ulnar ray longitudinal deficiency has been embryologically shown to be due to a deficiency of the Sonic Hedgehog that is the main controller of the anteroposterior axis of limb development.<sup>4</sup> There is usually shortening of forearm and ulnar sided deviation of the hand, which leads to its another name ulnar clubhand. Usually found unilaterally. Such rarity in its occurrence leads to controversy and dilemma in proper way of management of these patients. Ulnar hemimelia patients usually have fixed flexion deformity of elbow joint. The

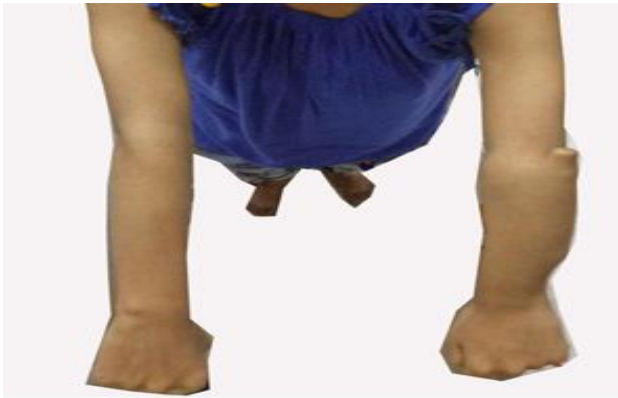more absence of ulna causes more severe flexion deformity. Usually there is associated radial head subluxation.<sup>1-3</sup> There may be some associated skeletal anomalies like syndactyly.

Here, we present a report of a patient with left sided ulnar club hand who was managed conservatively with good functional outcome.

### CASE REPORT

A 17-year-old female patient presented to us with deformed left upper limb. There was no history of intake of any teratologic drug by mother during the antenatal period. The patient was born through normal vaginal delivery at full term. There was no history of a congenital skeletal anomaly in parents or any of the siblings. On examination, there was shortening of forearm on the effected side (Figure 1). Radial head was grossly subluxated and palpable as a rounded bony mass continuous with radius. There was no restriction of motion at elbow but range of motion was restricted at wrist with

decreased wrist flexion. There was no associated hand anomaly.

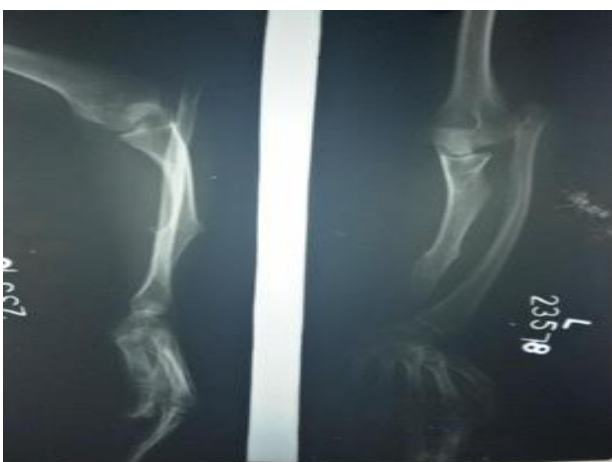


**Figure 1: Forearm is shortened on the left and radial head is grossly subluxated.**



**Figure 2: Range of motion at the elbow is not restricted.**

Radiological imaging revealed a deformed misshapen ulna with absence of its distal end, ulnar deviation of hand and radial bowing. Radial head was subluxated and proximally migrated (Figure 3).



**Figure 3: Radiograph showing deformed forearm, longitudinal ulnar deficiency distally, subluxated radial head and ulnar deviation of hand.**

### Treatment

A regular and well-defined physiotherapy plan was developed to maximize the use of the limb and prevent development of contractures but no surgery was planned.

### DISCUSSION

Ulnar hemimelia is a postaxial complete or partial longitudinal deficiency of ulna. It may be an isolated finding or it may be associated with complex carpal, metacarpal, and digital abnormalities. Various classification systems have been used, depending on the deformities in elbow joint, ulna, carpal, metacarpal and digits. Bayne classification which was later on extended by Havenhill and Goldfarb gives 6 different types from type 0 to type 6. Type 1 with dysplastic ulna is the most common followed by type 0 with normal ulna and involvement of carpus or hand only. Type 2 is the one with partial aplasia of ulna which was present in our case (Figure 1). Type 3 patients have complete ulnar aplasia. Type 4 has radiohumeral synostosis and type 5 comprises of phocomelic deficiency.<sup>9-12</sup>

The triquetrum and the capitate are frequently absent in these patients. Radiohumeral joint fusion is also a frequent association. Postaxial (ulnar-sided) deficiency of metacarpals and digits is a common finding in these patients. Three-fingered hand (tridactyly) is the most common hand anomaly followed closely by mono-digital hand.<sup>1</sup> Cases with digital anomalies, camptodactyly and postaxial syndactyly have also been reported in literature.<sup>13</sup> In general, the severity of ulnar dysplasia correlates with the degree of hand and wrist anomalies.

Rarely, ulnar hemimelia may also be associated with syndromes unlike the radial clubbed hand that has been much more frequently associated with congenital syndromes. It may be a part of Poland syndrome, Klippel-Feil syndrome, Goltz-Gorlin syndrome, Cornelia De Lange syndrome, or Femur Fibula Ulna syndrome.<sup>5,7</sup> The radius is typically longer than the ulna in patients with achondroplasia, and in patients with mucopolysaccharidosis, the distal ulna and radius can be hypoplastic and may slope toward each other.<sup>6,8</sup> In syndromic cases the clinical course and the prognosis depends on the severity of the syndrome.

### CONCLUSION

Ulnar hemimelia is a rare postaxial partial or complete longitudinal deficiency of ulna. It presents with congenital shortening of forearm, ulnar sided deviation of the hand, fixed flexion deformity of elbow joint and radial head subluxation. There may also be some associated skeletal anomalies of the hand. In the extended Bayne classification, isolated dysplastic ulna is the most common type. Early recognition is essential to maximize the range of motion at elbow and wrist by preventing contractures and surgical correction in appropriate cases.

*Funding: No funding sources*

*Conflict of interest: None declared*

*Ethical approval: Not required*

## REFERENCES

1. Frantz CH, O'Rahilly R. Ulnar Hemimelia. *Artificial Limbs.* 1971;15:25-35.
2. Drachman DB, Sokoloff. The role of movement in embryonic joint development. *Develop Biol.* 1966;14:401-20.
3. Duken J. Über der Beziehungen zwischen Assimilationshypophalangie und Aplasie der Interphalangealgelenke. *Virchows Arch Path Anat Physiol.* 1921;233:204-25.
4. Al-Qattan MM, Al-Thunyan A. Ulnar Deficiencies. In: Abzug J, Kozin S, Zlotolow D. (eds). *The Pediatric Upper Extremity.* Springer, New York, NY. 2015.
5. Agrawal AK, Kosada D, Patel S, Patel J, Desai S, Patwa JJ. Ulnar hemimelia in deformed left forearm treated with Ilizarov fixator. *Int J Orthop Sci.* 2017;3:1013-6.
6. Panda A, Gamanagatti S, Jana M, Gupta AK. Skeletal dysplasias: a radiographic approach and review of common non-lethal skeletal dysplasias. *World J Radiol.* 2014;6:808-25.
7. Palmucci S, Attinà G, Lanza ML. Imaging findings of mucopolysaccharidoses: a pictorial review. *Insights Imaging.* 2013;4:443-59.
8. Aucourt J, Budzik JF, Manouvrier S, Mezel A, Cagneaux M, Boutry N, et al. Congenital upper limb malformations: pictorial review. *ECR 2011/C-2085.*
9. Al-Qattan MM, Al-Sahabi A, Al-Arfaj N. Ulnar ray deficiency: a review of the classification systems, the clinical features in 72 cases, and related developmental biology. *J Hand Surg Eur.* 2010;35:699-707.
10. Bayne LG. Ulnar club hand (ulnar deficiencies). In: Green DP (Ed.) *Operative hand surgery.* New York: Churchill Livingstone. 1982;245-57.
11. Goldfarb CA, Manske PR, Busa R, Mill J, Carter P, Ezaki M. Upper-extremity phocomelia reexamined: a longitudinal dysplasia. *J Bone Joint Surg Am.* 2005;87:2639-48.
12. Havenhill TG, Manske PR, Patel A, Goldfarb CA. Type '0' ulnar longitudinal deficiency. *J Hand Surg Am.* 2005;30:1288-93.
13. Özdemir M, Turan A, Kavak RP. Ulnar hemimelia: a report of four cases. *Skeletal Radiol.* 2019;48:1137-43.

**Cite this article as:** Lamba A, Kumar N, Krishna C, Chhabra S. Ulnar longitudinal deficiency: a rare case report and review. *Int J Res Orthop* 2021;7:159-61.