

Case Report

Synovial chondromatosis: a rare cause of knee pain and swelling

Raja Bhowmik*, Narasimha Reddy, N. Srinivasan

Department of Orthopaedics, Mallareddy Institute of Medical Sciences, Hyderabad, Telangana, India

Received: 04 September 2020

Accepted: 08 October 2020

***Correspondence:**

Dr. Raja Bhowmik,

E-mail: rajabhowmik89@gmail.com

Copyright: © the author(s), publisher and licensee Medip Academy. This is an open-access article distributed under the terms of the Creative Commons Attribution Non-Commercial License, which permits unrestricted non-commercial use, distribution, and reproduction in any medium, provided the original work is properly cited.

ABSTRACT

Synovial chondromatosis (SC) is a rare, benign, metaplastic, monoarticular disorder of synovial membrane and bursae of large joints. It commonly affects the large joints such as the knee, hips, wrist, ankle and shoulder. Here we report a case of SC of right knee in a 60-year-old female presenting with chief complaints of pain, swelling, restriction of movement in right knee since 1 year after a fall at home. X-ray of right knee revealed multiple calcified loose bodies. The final diagnosis was established by correlating radiologic findings with the histopathology of the excised specimen. Patient was successfully treated by open partial synovectomy of knee using anterior approach in a single step procedure.

Keywords: Chondromatosis, Synovial osteochondromatosis, Chondrosarcoma

INTRODUCTION

Synovial chondromatosis (SC), is a benign joint disease characterized by the formation of intra-articular cartilaginous nodules. The resulting nodules can detach from the synovial lining, becoming free bodies which may undergo secondary calcification and ossification.¹ Further active growth and enlargement of these loose bodies can occur due to nourishment by synovial fluid.² Once ossified, the free bodies cause degradation of the articular cartilage. This disease commonly presents between the ages of 20 and 70 and is twice as likely to affect men. Clinically, SC also presents with joint pain, swelling and a limited range of motion. The process may occur in two forms: primary synovial chondromatosis (also referred to as reichel syndrome) and secondary synovial chondromatosis.³ Synovial chondromatosis is also called as chondrometaplasia.⁴ Synovial chondromatosis most commonly involves knee joint with a frequency of 55%–65%. Other places that are involved frequently include other joints such as hip, elbow, shoulder, and ankle. It rarely involves temporomandibular joint.⁵

CASE REPORT

We report a case of a 60-year-old female, housewife by occupation who was treated by a physician for 1 year for right knee pain and swelling with nonsteroidal anti-inflammatory medications (NSAIDs) and rest. She presented to the orthopaedics outpatient department with c/o of diffused pain, swelling, restriction of movement in right knee since 1 year after a fall at home. O/E, overlying skin was normal, mild swelling noted around the knee joint line anteriorly, no local rise in temperature, McMurray and Apley compression tests were positive. No instability was found, multiple nodular swellings of various sizes smallest being approx. 2x2cm and largest being approx. 3x4cms was palpated on anterior aspect of right knee joint line inside the suprapatellar pouch, patellar tap negative. Grinding sound during joint movement present, right knee range of motion was 45-90 degree. X-ray of right knee revealed multiple calcified loose bodies, periosteal reaction, reduced knee joint space in medial compartment. The laboratory results included rheumatoid factor (weakly positive), antinuclear-antibodies (negative), human immunodeficiency virus (negative), hepatitis B surface

antigen (negative), hepatitis C virus (negative), C-reactive protein (<0.04 mg/L), erythrocyte sedimentation rate (6 mm/h), haemoglobin (11.9gms/dl), white blood cell count (8.4 μ L), synovial fluid cultures (negative) and gram stain (negative).

After discussing the risks and the benefits of the procedure with the patient's family, surgery was planned for the patient. Under spinal anaesthesia, the patient was placed in supine position on the operating table, a well-padded tourniquet was applied to mid-thigh. The operating limb was exsanguinated and the tourniquet was inflated. Parts painted and draped. Using anteromedial parapatellar approach (von langenbeck) with parapatellar arthrotomy, the knee joint was exposed, the patella was retracted laterally and the knee was flexed to gain a good view of the anterior compartment of the joint and the suprapatellar bursa. The knee joint was extensively evaluated and loose bodies in the joint capsule was removed which were sent to pathology for histopathological evaluation. The chondral surfaces were inspected, few loose bodies were found adherent to chondral surface which was removed and the joint surface freshened, the synovial lining of the joint was found to be hypertrophied and hence subtotal synovectomy done.

After all loose bodies were extracted, the patient's incisions were closed with ethilon suture and was placed in sterile dressings with a negative suction drain. The patient was treated on intravenous cefuroxime for 3 days and oral cefuroxime for 4 days post operatively. Sutures were removed at postoperative day 10 and range of movement exercise started from 2 weeks onwards. The histopathological report confirmed the diagnosis of synovial osteochondromatosis. The patient was discharged in hemodynamically stable and with a healthy healing wound.

Pathological findings

Here, in (Figure 1) shows antero-posterior, lateral x ray of right knee showing multiple loose bodies. (Figure 2) shows intraoperative image showing hypertrophied synovium and eroded joint surface.

Here, (Figure 3) shows the gross appearance is that of a multilobulated synovium with multiple white or bluish nodules that are composed of hyaline cartilage attached to the synovium of varying size.

Figure 4 shows microscopically, the metaplastic synovium shows cartilaginous nodules beneath the surface lining of the synovial membrane. They may be highly cellular and of moderate pleomorphism. The nodules are variably cellular with the chondrocytes seen in clusters, a very characteristic finding.

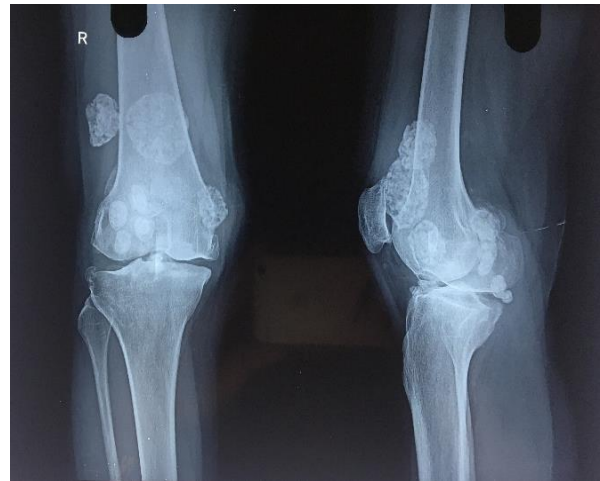

Figure 1: Antero-posterior, lateral x-ray of right knee showing multiple loose bodies.

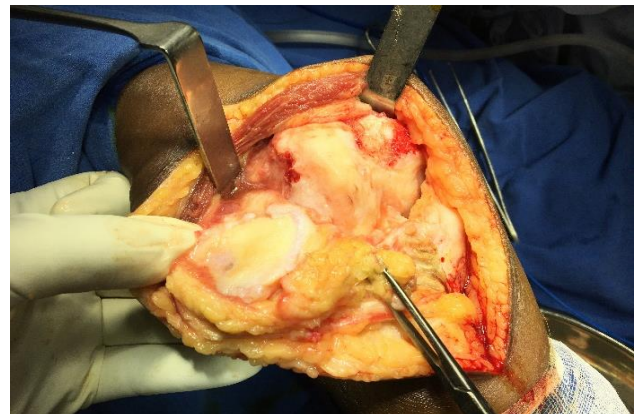

Figure 2: Intraoperative image showing hypertrophied synovium and eroded joint surface.

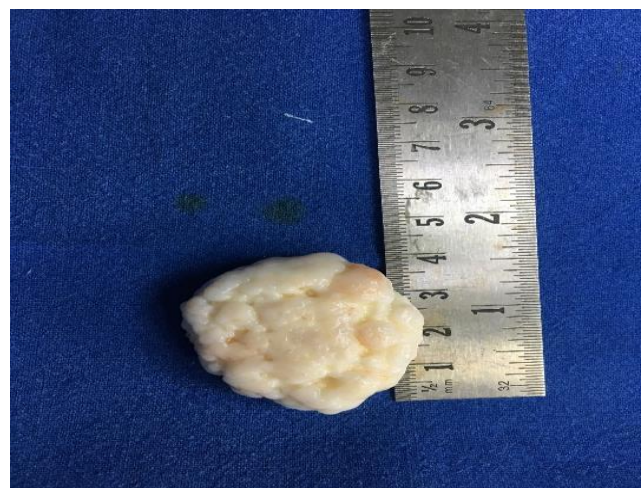

Figure 3: Gross appearance is that of a multilobulated synovium with multiple white or bluish nodules that are composed of hyaline cartilage attached to the synovium of varying size.

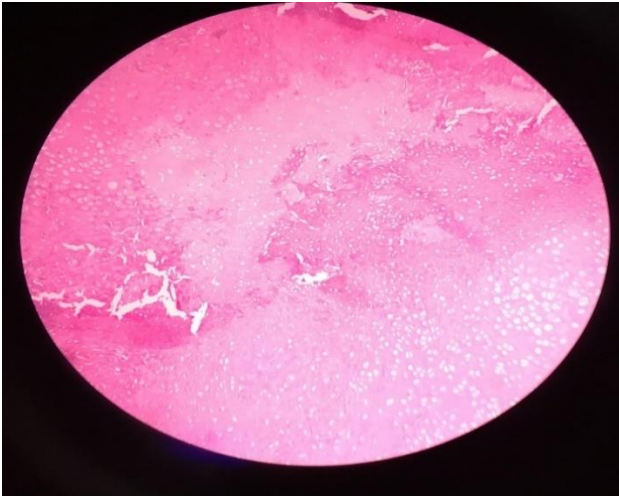


Figure 4: Microscopically, the metaplastic synovium shows cartilaginous nodules beneath the surface lining of the synovial membrane. They may be highly cellular and of moderate pleomorphism. The nodules are variably cellular with the chondrocytes seen in clusters, a very characteristic finding.

DISCUSSION

Synovial chondromatosis (SC), first described by Reichel in 1906, it is a rare benign disorder characterized by chondroid metaplasia with multinodular proliferation of the synovial lining of a diarthrodial joint, bursa, or tendon sheath. The disease is classified into two types, primary and secondary, with secondary SC typically occurring in the setting of trauma or joint disorder, most commonly osteoarthritis. Milgram described three phases in the disease process of synovial chondromatosis as follows: Phase 1: metaplasia of synovium with active synovitis and absence of loose bodies. Phase 2: active synovitis with the formation of loose bodies, which are still cartilaginous. Phase 3: loose bodies tend to calcify and synovitis subsides. The patient generally presents with pain, swelling and restriction of movements and normally presents in their third to fifth decades, though there are reports of its occurrence in childhood. Synovial chondromatosis is twice more common in males. The knee joint is commonly involved joint, but it has been reported in shoulder, elbow, and other joints.⁷ Delay in diagnosis of synovial chondromatosis can occur due to slow progression of disease with calcification of free cartilage fragments at late stage.⁸ The presentation is mostly unilateral, but bilateral involvement has also been seen.

Diagnosis is based on clinical findings and imaging studies which includes plain radiograph, ultrasound, computed tomography, and magnetic resonance imaging (MRI). Radiographs show multiple calcified bodies of variable sizes, distributed throughout the joint, or less commonly, within bursae or tendon sheaths.⁹ CT is useful only if the cartilaginous nodules have calcified. MRI shows soft-tissue and the extent of involvement in more anatomic detail than any other imaging modalities and is the optimal

modality for imaging SC. On MRI, the characteristic appearance for SC includes a mass with internal nodules that is hypointense/isointense to muscle on T1- and high signal on T2- weighted images. Histopathological finding aids in confirmation which shows foci of hyaline cartilage studded throughout the hyperplastic sub synovial layer of connective tissue. Arthritic changes are seen in secondary synovial chondromatosis at presentation. Radiographs in this patient were suggestive of synovial chondromatosis.

Differential diagnosis of synovial chondromatosis can be benign or malignant. Benign lesions such as synovial haemangioma, pigmented villonodular synovitis, and lipoma arborescens and malignant lesions such as synovial chondrosarcoma and synovial sarcoma.¹⁰

The treatment options for extra articular SC are surgical removal of loose bodies with or without removal of synovial membrane. As the loose bodies arise from the synovium, some authors have reported recurrence of SC when synovial membrane is not excised.¹¹ Open surgery or arthroscopic intervention can be performed with resection of the diseased synovium and removal of any loose intra-articular bodies. Recurrence is frequent after partial synovectomy; hence, total synovectomy has been suggested as the preferred treatment.¹² In this patient complete removal of loose bodies was done anterior to the knee joint, Complete removal of diseased synovium was ensured to reduce chances of recurrence. Post-operative management includes a progressive range of motion exercise and strengthening of peri-articular muscle groups. Radiotherapy is beneficial in patient with recurrent lesions and inhibition of FGF-9 has been suggested as a nonoperative method of treating primary synovial chondromatosis. Secondary synovial chondromatosis is managed with anti-inflammatory drugs with the additional management with surgery required only when inflammatory joint symptoms or mechanical symptoms prohibit adequate joint function. Complications of synovial chondromatosis can be recurrence, secondary osteoarthritis and malignant transformation.

CONCLUSION

Curvilinear or rounded calcified lesions within close vicinity of joint should always be investigated for possibility of SC. Opinion of clinical, radiological, and histological findings should be correlated in every case and the patient is treated accordingly.

Funding: No funding sources

Conflict of interest: None declared

Ethical approval: Not required

REFERENCES

1. Adelani MA, Wupperman RM, Holt GE. Benign synovial disorders. J Am Acad Orthop Surg. 2008; 16:268-75.

2. Crotty JM, Monu JU, Pope Jr TL. Synovial osteochondromatosis. *Radiol Clin North Amer.* 1996;34(2):327-42.
3. Fletcher CD, Unni KK, Mertens F, editors. *Pathology and genetics of tumours of soft tissue and bone.* Iarc. 2002.
4. Miller MV, King A, Mertens F. Synovial chondromatosis. *WHO Tumors of Bone and Soft Tissues.* *Int Agen Resear Canc Pre.* 2002:245.
5. Fuller E, Bharatha A, Yeung R, Kassel EE, Aviv RI, Howard P, et al. Synovial chondromatosis of the temporal mandibular joint. *Canad Assoc Radiol J.* 2011;62(2):151-3.
6. Campanacci M. *Bone and Soft Tissue Tumors.* 2nd Edition. New York: Springer-Verlag Wien; 1999.
7. Dwidmuthe SC, Nemade AS, Agrawal S, Pathak A. Rare case of extra-articular synovial chondromatosis of biceps tendon sheath in 8 years male child-a literature review. *J Orthop Case Rep.* 2014;4:33-6.
8. Trias A, Quintana O. Synovial chondrometaplasia: Review of world literature and a study of 18 Canadian cases. *Can J Surg.* 1976;19:151-8.
9. Murphey M D, Vidal J A, Fanburg-Smith J D, Gajewski D A. Imaging of synovial chondromatosis with radiologic-pathologic correlation. *Radiograph.* 2007;27:1465-88.
10. Wittkop B, Davies AM, Mangham DC. Primary synovial chondromatosis and synovial chondrosarcoma: A pictorial review. *Eur Radiol.* 2002;12:2112-9.
11. Ogilvie-Harris DJ, Saleh K. Generalized synovial chondromatosis of the knee: a comparison of removal of the loose bodies alone with arthroscopic synovectomy. *Arthrosc.* 1994;10(2):166-70.
12. Amin MU, Qureshi PS, Ghaffar A, Shafique M. Primary synovial osteochondromatosis of the surapatellar pouch of knee, Correlation of imaging features with surgical findings. *J Radiol Case Rep.* 2010;4:7-14.

Cite this article as: Bhowmik R, Reddy N, Srinivasan N. Synovial chondromatosis: a rare cause of knee pain and swelling. *Int J Res Orthop* 2020;6:1346-9.