

Original Research Article

A retrospective study of neurological recovery following posterior stabilization for spine instability in tertiary care hospital, Chengalpattu district

R. Selvaraj*, K. Nagappan, Aravind Kumar, K. Vivek

Department of Orthopaedics, Karpaga Vinayaga Institute of Medical Sciences and Research Centre, Chinnakolmbakkam, Tamil Nadu, India

Received: 19 August 2020

Accepted: 05 September 2020

***Correspondence:**

Dr. R. Selvaraj,

E-mail: arvindr84@gmail.com

Copyright: © the author(s), publisher and licensee Medip Academy. This is an open-access article distributed under the terms of the Creative Commons Attribution Non-Commercial License, which permits unrestricted non-commercial use, distribution, and reproduction in any medium, provided the original work is properly cited.

ABSTRACT

Background: Spinal instability is defined as the loss of the ability of the spine under physiological loads to maintain relationships between vertebrae in such a way that the spinal cord or nerve roots are not damaged or irritated, and deformity or pain does not develop. The objective was to study the neurological recovery following posterior stabilization for lumbar spine instability.

Methods: This retrospective study was conducted in the Department of Orthopaedics, Karpaga Vinayaga Institute of Medical Sciences and Research Centre, Chengalpattu district, Tamil Nadu, India. (KIMS & RC). Study duration was from January 2020 to February 2020 (2 months). Patients admitted with spinal instability with neurological deficit, treated with instrumentation and fusion will be study participants were 30 patients.

Results: In our study, Denis pain scale showed that 40% of patients had minimal pain, 40% of patient had moderate pain and 20% had moderate to severe pain with significant changes in daily activities, the Denis work assessment scale showed that 33.33% of patients had unable to return to the previous job but can able to work full time with job modification.

Conclusions: The most important factor responsible for prognosis and neurological recovery is the neurological status at the time of injury. Surgical decompression and stabilization with fusion improves the neurological recovery especially in incomplete cord lesions.

Keywords: Spinal instability, Neurological recovery, Denis pain scale, Frankel grade

INTRODUCTION

Spinal injuries in general are devastating. 90% percent of these injuries involve the thoracolumbar region. Thoracolumbar fractures occur from all forms of trauma including fall from height, road traffic accidents, and crush injuries.¹ They result from vertical compression to the slightly flexed spine, a rotational or shear component, or some extension force that can cause a different fracture pattern.² Twenty percent of them are associated with neurological deficits, a significant cause of morbidity and mortality. The common mode of spine injury is a fall from height in our population or a road accident. These are

either a worker climbing a coconut tree or a painter standing on scaffolding. Most of them involve patients in the young, active age group.³ There has also been enough work done on the use of steroids to reduce the secondary injury to the neural elements. Despite these advancements, managing these fractures still pose a challenge to orthopedic surgeons. Surgical decompression and posterior instrumented fusion in spinal injuries enables the patient to become ambulant without much pain and gives a fair chance of neurological recovery when the compressed neural elements are released.⁴ It also increases of the longevity of the patient and decreases the morbidity due to prolonged recumbency in case of complete cord

lesions Moreover operative management helps in executing better nursing care to paraplegics otherwise whose quality of life will decline.⁵

METHODS

This retrospective study was conducted in the Department of Orthopaedics, Karpaga Vinayaga Institute of Medical Sciences and Research Centre, Chengalpattu district, Tamil Nadu, India (KIMS & RC). Study duration was from January 2020 to February 2020 (2 months).

Patients admitted with spinal instability with neurological deficit, treated with instrumentation and fusion will be study participants were 30 patients. This prospective study included 10 unstable burst fractures, 3 anterior wedge compression fractures, and 2 fracture-dislocations. The unstable fracture was defined by clinical and radiological parameters. They include burst fractures with any one of the following criteria: the neurological deficit; more than 50% axial compression and; more than 25% angulation, wedge compression fractures involving middle column with neurological deficit, and fracture-dislocations with neurological deficit. The study includes 13 males and 2 females. The age group involved in our study ranged between 17 years and 59 years. All the patients were admitted to the emergency ward and resuscitated appropriately. A complete clinical and neurological examination was done. In our study, only 3 patients presented to us within 8 hours and they had been given methylprednisolone as per national acute spinal cord injury study (NACIS) III protocol. The level of spine injury was assessed clinically and radiologically. The

spinal injuries were classified based on the Denis classification system in our study.

Inclusion criteria

Unstable burst fracture with neurological deficit, fracture dislocation with neurological deficit, and anterior wedge compression fracture with neurological deficit.

Exclusion criteria

Fractures without neurological deficit including stable burst fracture, stable anterior wedge compression fracture, and chance fracture, late presentation with large pressure sores, elderly with severe osteoporosis, and poor anesthetic risk.

The patient's neurological deficit was quantified as per Frankel's et al grading. Out of 15 patients, 7 patients were paraplegics and 8 had paraparesis. According to Frankel's et al grading, 7 patients with grade A, 2 patients with grade B, 5 patients with grade C and 1 patient with grade D. All the patients underwent magnetic resonance imaging (MRI) to know the status of the cord, the integrity of the posterior longitudinal ligament, presence of disc herniations and the degree of canal compromise. All the burst and fracture-dislocations patients had computed tomography (CT) scan imaging to detect retropulsion of fractured fragments, canal compromise, and for assessing pedicle dimensions. Ultrasonogram (USG) abdomen was done and visceral injuries were ruled out. These patients underwent posterior decompression with short-segment posterior instrumentation and intertransverse fusion.

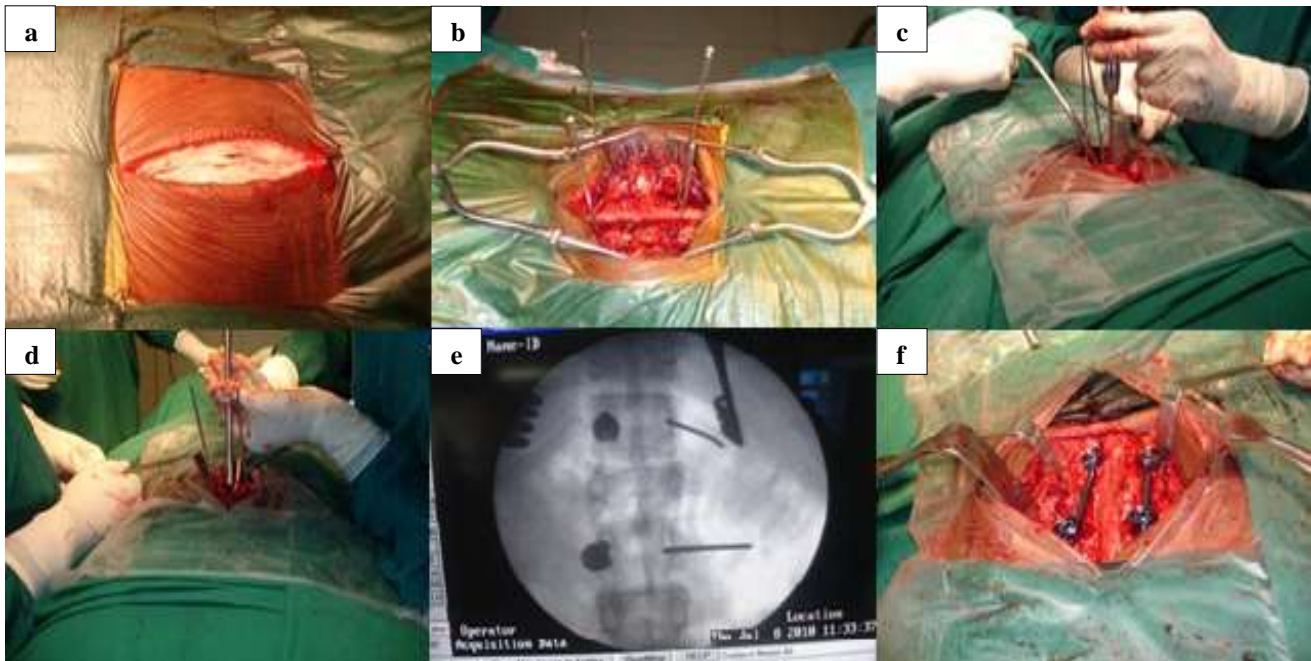


Figure 1: Intraoperative pictures (a) skin incision, (b) identification of pedicles, (c) entry with awl, (d) insertion of screws, (e) pedicle screws in situ, and (f) pedicle screws with rods.

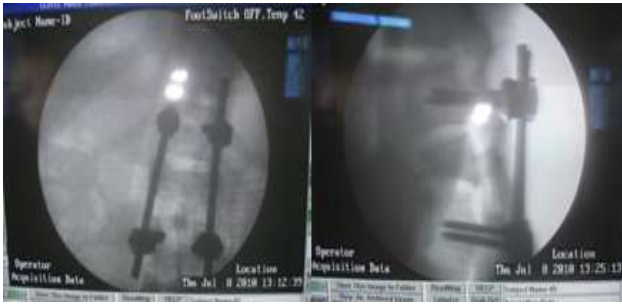

Figure 2: Pedicle screw confirmation in C arm.

All the patients were turned sideways periodically in the immediate post-operative period. The drainage tube was removed at 48 hours. They were allowed to sit after wearing Taylor’s brace with back support on the 5th postoperative day. Suture removal was done on the 10th day. Active assisted and passive exercises were taught to keep the joints supple. Clean intermittent self-catheterization was taught in the post-operative period. All the patients were advised to continue Taylor’s brace for the first 3 months after the surgery. They were followed up every month until 6 months and then every 2 months during the next 6 months. The minimum follow up in our study is 3 months and the maximum follow up is one year and 3 months. During the follow-up period, the pain and working ability were assessed using Denis pain and work assessment scale and also evaluated clinically and radiologically for the following.

Statistical analysis

The data were expressed using descriptive statistics such as mean, standard deviation, frequency and percentage. A comparison of continuous variables between groups was done using independent sample t-test/analysis of variance (ANOVA). Categorical variables were analyzed by the chi-square test for their significant association. P-value <0.05 were considered statistically significant. The following observations were made from the statistical data obtained from our study.

RESULTS

In our study most of the patients did not have steroids as they presented late to our institution (n=12). The most common level of injury in our study was L2 in 5 cases (33.34%), followed by D12 in 3 cases (20%), L1 in 3 cases (20%), D11 in 2 cases (13.33%) and L3 in 2 cases (13.33%) (Table 1).

In our study all the cases underwent posterior decompression with posterior stabilization and fusion. All the patients were operated between 8 and 20 days of the initial injury. Neurologic function improved by at least one Frankel grade in thirteen (86.66%) of the fifteen patients with neurological deficits. Neurologic function improved by at least one Frankel grade in five patients and two grades in three patients with incomplete neurologic

deficits. Neurologic function improved by at least two Frankel grades in four and three grades in one of the seven patients with complete neurologic deficits. Neurologic function remained at the preoperative level in two patients with complete neurologic deficits. One patient who died 3 weeks after surgery (case no. 4), another patient had a dural tear (case no. 5) repaired intraoperatively. These two patients had 0% improvement postoperatively. In our study, 12 cases had bladder involvement, out of which 5 of them had recovered. There was a significant association between the preoperative Frankel grading and the bladder involvement (p-value=0.016) with the bladder being involved in severe Frankel grades (for e.g. Frankel grade A and B). Statistically, there was no correlation between the bony level and the recovery of the bladder (p value=0.202) (Table 2).

Table 1: Age wise distribution of cases.

Age (in years)	No. of cases	Percentage
11-20	2	13.33
21-30	6	40.00
31-40	4	26.66
41-50	2	13.33
51-60	1	6.66
Total	15	100

Table 2: Percentage of the cases in Frankel grade.

Type of lesion (Frankel grade)	No. of cases	Percentage
A	7	46.66
B	2	13.34
C	4	26.66
D	2	13.34
E	0	0
Total	15	100

The associated injuries in our study population which include unilateral calcaneal fractures in three patients, closed ulna fracture in one patient, clavicle fractures in two patients, and rib fracture without haemo pneumothorax in two patients. All the associated fractures were treated by non-operative methods. In our study Denis pain scale showed that 40% of patients had minimal pain, 40% of patient had moderate pain and 20% had moderate to severe pain with significant changes in daily activities, the Denis work assessment scale showed that 33.33% of patients had unable to return to the previous job but can able to work full time with job modification, 26.67% of patients cannot able to work full time and 40% of patients were completely disabled (Table 3).

We had 3 cases of grade I bedsore which were managed by antibiotics, dressings and periodical turning of patients, 3 patients had urinary tract infection managed by appropriate parenteral antibiotics and bladder wash with povidone-iodine and normal saline. We had a case of post-operative superficial wound infection which was settled

with regular dressings and antibiotics. Two cases developed paralytic ileus which was managed by intravenous fluids and Ryles tube aspiration. We had a case of dural tear which was repaired intraoperatively and did not have cerebrospinal leak postoperatively. These patients were followed and none had a postoperative cerebrospinal leak. We had one death in our study which occurred one month after discharge due to comorbid conditions. We had one case of misplacement of screw-in our study which was revised later (Table 4).

Table 3: Pre-operative and post-operative neurological status.

Pre-op neurological status	Post-op neurological status
Frankel grade A-7 cases (46.66%)	A and D (1 case)
	A and C (4 cases)
	A and A (2 cases)
Frankel grade B-2 cases (13.34%)	B and D (2 cases)
Frankel grade C-4 cases (26.66%)	C and E (1 case)
	C and D (3 cases)
Frankel grade D-2 cases (13.34%)	D and E (2 cases)

Table 4: Complications.

Denis pain scale	No of patients (%)
P1	0
P2	6 (40)
P3	6 (40)
P4	3 (20)
P5	0
W1	0
W2	0
W3	5 (33.34)
W4	4 (26.66)

DISCUSSION

Dorsolumbar spinal injury with the neurological deficit is an overwhelming crisis leading to considerable morbidity and mortality. Debate exists over the exact modality of treatment and timing of intervention. All aspects of management aim at preventing secondary injury to the spinal cord of which mechanical compression is one of the most important reversible factors. Non-operative care avoids anesthetic risk and morbidity of surgery but increases the risks of prolonged recumbency and hospital stay.⁶ The current surgical management corrects the deformity, enhances the neurological recovery, and allows early mobilization and return to work, with minimal complication. With improved investigations and advanced stabilization systems and intraoperative monitoring of cord function, the outlook for patients with thoracolumbar fractures with neurological deficits has improved and can be enhanced if an optimum environment for neurological recovery is provided.⁷ The primary management of

patients with these injuries is decompression and stabilization.

W5 **6 (40)**

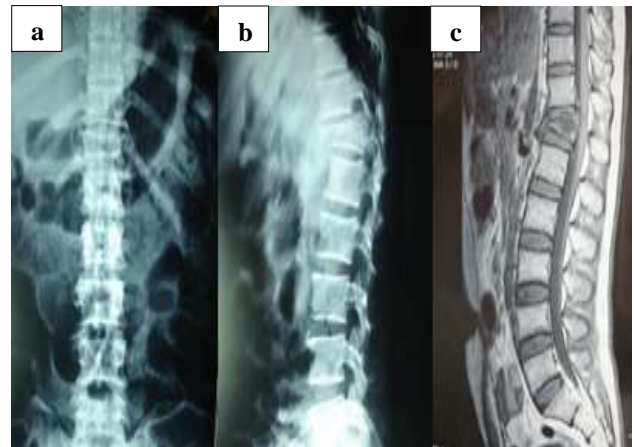


Figure 3: Case 1 (a) and (b) pre-operative x ray shows burst of D12, and (c) MRI shows burst of D12, compression of the cord.

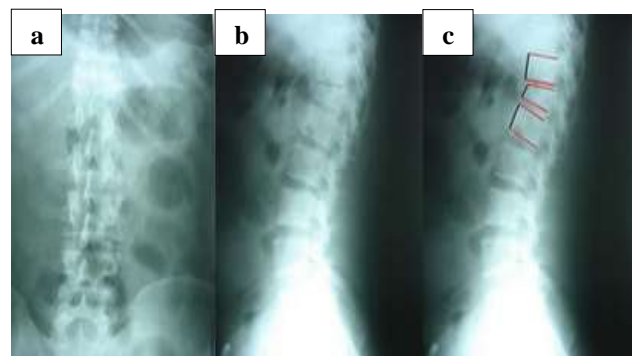


Figure 4: Case 2 (a), (b) and (c) pre-operative x-ray shows anterior wedge compression of D12.

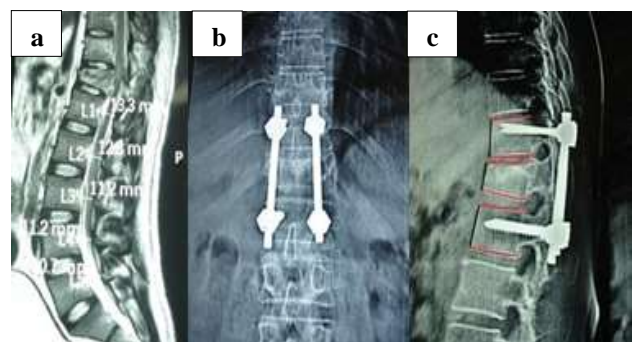


Figure 5: (a) MRI showing wedge compression of D12 compressing the cord, (b) and (c) immediate post-op.

In our study, all the cases underwent posterior decompression, short segment stabilization with pedicle screws, and fusion. This was performed within 3 weeks of injury with an average of 14 days.⁸ From our study, it was found that males in the age group of 20-40 years more

commonly sustain spinal injuries. They form the most important socioeconomic group. The most common mode of violence is an accidental fall from a height, while vehicular accidents account for a few. When compared with a primitive system like the ones which force the lamina apart or straighten the spine, the pedicle screw systems with large fixation screws implanted through the pedicle into the vertebral body are better biomechanically.⁹ They are the only device which allows three-column fixation of the vertebral column and in areas where the lamina have been removed. They provide excellent stability in the fractured spine. A short segment fixation with pedicle screw achieves reasonable stability till the segment is fused.¹⁰ This is so because a pedicle screw achieves a three-column fixation and proper stability than the other posterior systems that were used previously. The main advantage of short-segment posterior instrumentation is that it preserves the motion segment resulting in less spinal stiffness and also avoiding flat back syndrome.¹¹ Jacobs et al reported that the use of short-segment posterior spinal instrumentation without restoration of the anterior column for the treatment of unstable thoracolumbar burst fractures has been associated with a high rate of early implant failure and progressive deformity. Short-segment pedicle screw fixation allows for spinal stabilization while simultaneously preserving as many motion segments as possible. In our study, all the cases underwent only posterior decompression, posterior stabilization, and posterolateral fusion. We had not done anterior procedures. Still, they had a good neurological recovery.¹² The midline spinal fusion technique performed earlier was biomechanically disadvantageous because the graft being situated far from the center of rotation experiencing tensile forces when the spine is flexed can induce excessive motion causing the graft to migrate before it can incorporate and consolidate.¹³ This caused higher rate of pseudoarthrosis. The most commonly employed method of fusion, the posterolateral technique addresses many of these flaws. It involves the fusion of the transverse processes and the facet joints of adjacent vertebrae. It allows the graft to be placed in closer proximity to the center of vertebral rotation than the midline fusion, thereby decreasing the tensile loads and graft migration.¹⁴ Both these factors increase the chances of obtaining a solid fusion. In our study, implant-related failure and deformity were reduced because of the addition of posterolateral fusion along with short-segment pedicle screw system. Fusion was done with the bone graft taken from the decorticated lamina and spinous processes and hence additional separate donor site morbidity was avoided.¹⁵ Knoeller et al reported that the neurological function improved by at least one Frankel grade in 83% of the patients with complete neurological deficit in his study. But in our study, 73% improvement in neurological function by one Frankel grade was observed in patients with complete neurological deficits.¹⁶ The most important factor responsible for prognosis and neurological recovery is the neurological status at the time of injury. Surgical decompression and stabilization with fusion improve neurological recovery, especially in incomplete cord

lesions. Out of 15 cases, 8 cases with incomplete lesions have recovered well when compared to complete lesions in our study.¹⁷ Denis pain scale showed 44% of patients had no pain and 17% had moderate pain to severe pain two years after surgery. While in our study 40% of patients had minimal pain, 40% of patients had moderate pain and 20% had moderate to severe pain with significant changes in daily activities.¹⁸ In our study, Denis's work assessment scale showed that 33.33% of patients had unable to return to the previous job but can able to work full time with job modification, 26.67% of patients cannot able to work full time and 40% patients were completely disabled.¹⁹ We had one case of misplacement of screw in our study which was revised later, two cases of dural tear which were repaired intraoperatively. We did not have the wrong level or worsening of neurological status after surgery. There were no noncontiguous or missed lesions in our study. All the associated fractures were treated by non-operative methods.²⁰

CONCLUSION

The enthusiasm of fixing and fusing the unstable spine is well rewarded with reduced fracture pain, making the patient sit up and avoiding the complications of recumbency like a pressure sore, urinary infections, deep vein thrombosis, pneumonitis and aids in neurological recovery, especially in partial neurological deficit patients. Though we did have a few complications they did not prevent those patients from experiencing the above advantage.

Funding: No funding sources

Conflict of interest: None declared

Ethical approval: The study was approved by the institutional ethics committee

REFERENCES

1. Aebi M, Etter C, Kehl T. Stabilization of the lower thoracic and lumbar spine the internal spine skeletal fixation system. Indication, technique, and first results of treatment. *Spine*. 1987;12:544-51.
2. Broom MJ, Jacobs RR. Current Status of Internal Fixation of Thoracolumbar Fractures. *J Orthop Trauma*. 1989;3:148.
3. Butt MF, Farooq M, Mir B, Dhar AS, Hussain A, Mumtaz M. Management of unstable thoracolumbar spinal injuries by short-segment spinal fixation. *Int Orthop*. 2007;31:259-64. *J Bone Joint Surg (Am)*. 1983;65:461-73.
4. Danisa OA, Shaffrey CI, Jane JA, Whitehill R, Wang GJ, Szabo TA, et al. Surgical approaches for the correction of unstable thoracolumbar burst fractures: a retrospective analysis of treatment outcomes. *J Neurosurg*. 1995;83:977-83.
5. Denis F. Spinal Instability As Defined by the Three-Column Spine Concept in Acute Spinal Trauma. *Clin Orthop*. 1984;189:65-76.

6. Denis F. The three columns of the spine and its significance in the classification of acute thoracolumbar spinal injuries. *Spine.* 1983;8:817-31.
7. Dick W, Kluger P, Magerl F, Woersdorfer O, Zach G. A new device for internal fixation of thoracolumbar and lumbar spine fractures: the fixator internet. *Paraplegia.* 1985;23:225-32.
8. Gertzbein S. Scoliosis Research Society. Multicenter spine fracture study. *Spine.* 1992;17:528:40.
9. Gurwitz GS, Dawson JM, McNamara MJ, Federspiel CF, Spengler DM. Biomechanical analysis of three surgical approaches for lumbar burst fractures using short-segment instrumentation. *Spine.* 1993;18:977-82.
10. Holdsworth F. Fractures, Dislocations, and Fracture-Dislocations of the Spine. *J Bone Joint Surg Am.* 1970;52:1534-51.
11. Holdsworth FW. Fractures, dislocations, and fracture-dislocations of the spine. *J Bone Joint Surg (Br).* 1963;45:6-20.
12. Jacobs RR, Casey MP. Surgical management of thoracolumbar spinal injuries. *Clin Orthop Relat Res.* 1984;189:22-35.
13. Jeffrey WP, Joel RL, Eldin EK, Robert WG. Successful Short-Segment Instrumentation and Fusion for Thoracolumbar Spine Fractures A Consecutive 4 1/2-Year Series. *Spine.* 2000;25:1157-69.
14. Kaneda K, Abumi K, Fujiya M. Burst Fractures With Neurologic Deficits of the Thoracolumbar-Lumbar Spine. Results of Anterior Decompression and Stabilization With Anterior Instrumentation. *Spine.* 1984;9:788-95.
15. Kelly RP, Whitesides TE. Treatment of lumbodorsal fracture-dislocations. *Ann Surg.* 1968;167:705.
16. Knoeller SM, Seifred C: Historical perspective: a history of spinal surgery. *Spine.* 2000;25:2838-43.
17. Langrana NA, Harten RD RD, Lin DC, Reiter MF, Lee CK. Acute thoracolumbar burst fractures: a new view of loading mechanisms. *Spine.* 2002;27:498-508.
18. Laser JA, Estes WJ. Distal short segment fixation of thoracolumbar and lumbar injuries. *Iowa Orthop J.* 1998;18:87-90.
19. T, Karaikovic E, Gaines RW. The load sharing classification of spine fractures. *Spine.* 1994;19:1741-4.
20. McHenry LC Jr. *Garrison's History of Neurology.* Springfield, IL: CC Thomas. 1969: 3-24.

Cite this article as: Selvaraj R, Nagappan K, Kumar A, Vivek K. A retrospective study of neurological recovery following posterior stabilization for spine instability in tertiary care hospital, Chengalpattu district. *Int J Res Orthop* 2020;6:1274-9.