

## Case Report

# Open femoral neck fracture of 14 years old boy treated by emergency internal fixation with additional osteomuscular pedicle graft: case report

Hendra C. Kumara\*, Ariya M. Nasution, Bayu S. Jiwandono,  
Anung B. Satriadi, Pamudji Utomo

Department of Orthopaedic and Traumatology, Faculty of Medicine, Sebelas Maret University, Professor Dr. R. Soeharso Hospital, Surakarta, Central Java, Indonesia

**Received:** 23 August 2020

**Accepted:** 01 October 2020

**\*Correspondence:**

Dr. Hendra C. Kumara,

E-mail: [hendrack@gmail.com](mailto:hendrack@gmail.com)

**Copyright:** © the author(s), publisher and licensee Medip Academy. This is an open-access article distributed under the terms of the Creative Commons Attribution Non-Commercial License, which permits unrestricted non-commercial use, distribution, and reproduction in any medium, provided the original work is properly cited.

### ABSTRACT

The incidence of femoral neck fractures in pediatric patients is rare, including <1% in all cases of fractures in children. The mechanism of injury is a high-energy injury that can cause a fracture in the femoral neck, open fracture cases are rare. Avascular necrosis is the most common complication. We report a fourteen year old boy who was in a road-traffic accident and had a Gustillo Anderson grade IIIA open femoral neck fracture. On the X-ray findings, we classified the type of fracture into Delbet type II. We decided to do the debridement and ORIF accompanied by an osteomuscular pedicle graft using a quadratus femoris muscle tendon fixed with 3 interfragmentary screws. Short-term evaluation shows a clinical union picture and is still well reduced without any signs of infection. Long-term evaluation of the bone healing process is needed and recognizes complications in the form of avascular necrosis of the femoral head.

**Keywords:** Open femoral neck fracture, Osteomuscular pedicle graft, OMPG

### INTRODUCTION

Femoral neck fractures in the age group of children are rare. The incidence is <1% of all fracture cases in children.<sup>1</sup> Open fractures are even more rare. The mechanism of injury of this type of fracture was resulting from high and very-high energy injury, such as road-traffic accident, fall from height.<sup>2-4</sup>

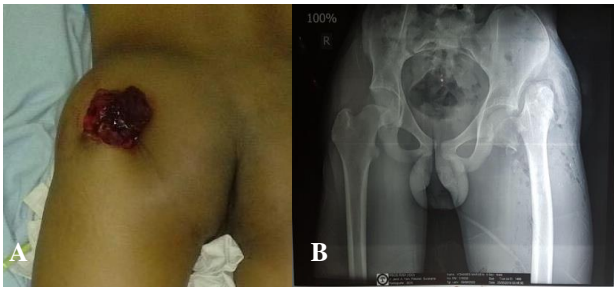
The challenges faced by orthopedic surgeon include quite frequent complications, namely avascular necrosis, even though the actions and interventions carried out are adequate.<sup>3</sup>

The choice of action, operative or conservative, must be considered wisely.<sup>4</sup> ORIF suggest become a choice of treatment with good clinical outcome and fewer rate of complication regarding of paying attention and maintain vascularization of pediatric femoral head damaged by fracture.<sup>4</sup>

### CASE REPORT

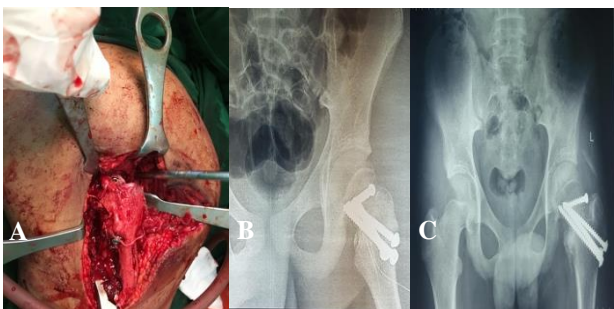
We report a case, where a 14-year-old boy came to the emergency department, after had a road-traffic accident 10 hours since the injury without any head injury or other body part injury. Physical examination revealed an open wound with exposure of greater trochanter to the left gluteal area with contamination in the form of ground and

sand (Figure 1). A plain X-ray examination was carried out and we assessed the patient as Gustillo Anderson grade IIIA open femoral neck fracture with the classification of Delbet type II fracture (Figure 1).



**Figure 1: A) Clinical appearance and B) plain X ray pelvis AP in the ER.**

Then, handling emergency measures are considered. We decided to take emergency action in the form of emergency debridement with open reduction and internal fixation with multiple screwing of the femoral neck. Additional procedure is performed after reduction and fixation. Osteomuscular pedicle graft using quadratus femoris muscle with small chip of bony pedicle, with open wounds can be closed primary (Figure 2).



**Figure 2: A) Pedicle graft insertion from the gluteus minimus muscle into the femoral head, B) Postoperative X ray photos and C) 3 months post-operative X-ray.**

Postoperative X-ray evaluation shows adequate anatomic reduction with a good position of implant screw fixation. Combined antibiotics are given for 5 days post-operatively.

Follow-up was done at 1 week, 1 month, 2 months, and 3 months postoperatively and clinical evaluation was carried out and documented. The patient was able to mobilize non-weightbearing walking with the aid of bilateral axilla crutches with well-healed surgical wounds.

Radiological evaluation every month shows the progression of fracture healing by the formation of callus around the fracture site. The position of reduction and fixation is still considered good, without any signs of loosening (Figure 2).

## DISCUSSION

Femoral neck fractures in children are always a result of high energy trauma because children's femoral necks are denser and harder compared to adult femoral columns. As a result, this fracture is usually associated with other concurrent injuries that must also be treated.

In our study, 53% of fractures were caused by RTA and 36% due to falls from height. This data matches the incidents reported in the literature. As existing literature, the majority of femoral neck fractures in children are classified as type II Delbet is the most common occurred, followed by type III and type IV.<sup>5</sup>

The low incidence of this case may be the reason why universal management protocols are not yet available. After being first presented by Cromwell in 1885, only a few reports were published until half of the 20th century, and all these patients were treated non-operatively with cast immobilization.<sup>5</sup>

Type II fractures must be treated with anatomic reduction and stable fixation to minimize the risk of late side effects. In type II fractures without much shift, good to reasonable results have also been reported with conservative treatment. In fractures with marked shifts, conservative treatment results are unsatisfactory. The high incidence of AVN, coxa vara or secondary displacement.

Canale and Bourland reported a decrease in complications in all, undisplaced or displaced, type II fractures, after reduction and internal fixation by pins or screws. Heiser states that if necessary, to bridge the physique, it is preferable to do so with a smooth Kirschner to prevent physical premature closure. Anterior capsulotomy can reduce the occurrence of AVN in these fractures. When open reduction must be carried out, the Watson-Jones approach is taken.<sup>5,6</sup>

The risk of AVN depends on several factors, including age, initial transfer rate, type of fracture, time for surgery, and method of fixation. The most important factor is the possible severity of femoral head vascularization at the time of trauma.<sup>4,5</sup>

AVN develops in about 17% to 47% of cases. is because adult pelvis has intraosseous blood vessels that supply the femoral head, whereas pediatric veins cannot pass through the physis. Therefore, blood supply to the femoral head is very important in a child and can be easily damaged when a fracture occurs. As mentioned by Ratliff, the development of AVN adversely affects the prognosis.<sup>4</sup>

Osteomuscular pedicle graft is the recommended procedure for femoral neck with non-union with 95% success rate. But the procedure applied to pediatric patients is quite rare because the cases are also very rare.<sup>1</sup>

In this case, the procedure is applied to an emergency case setting, where open fracture contamination is a risk factor that has the potential to reduce the success of the osteomuscular pedicle graft.

Clinical outcomes in short-term evaluations have shown good results, characterized by the progression of bone healing in accordance with normal bone healing time, and good clinical ROM.

## CONCLUSION

Stable fixation with good anatomic reduction is still an option in cases of femoral neck fractures in pediatric patients. And it has been proven to produce good clinical outcomes and high union rates. Osteomuscular pedicle graft procedure aims to increase and restore vascularization or blood supply from the femoral head which is damaged due to fracture.

*Funding: No funding sources*

*Conflict of interest: None declared*

*Ethical approval: Not required*

## REFERENCES

1. Daragadd M. Meyer's muscle pedicle bone graft a novel procedure in treatment of neglected fracture neck of femur in pediatric age group-a case report.

- Journal of Clinical and Diagnostic Research. 2016;10(9):RD03-5.
2. Lam SF. Fractures of the neck of the femur in children. J Bone Joint Surg Am. 1971;53:1165.
3. Song KS. Displaced fracture of the femoral neck in children open versus closed reduction. J Bone Joint Surg. 2010;92-B:1148-51.
4. Bali K, Sudesh P, Patel S, Kumar V, Saini U, Dhillon MS. Pediatric femoral neck fractures: our 10 years of experience. Clin Orthop Surg. 2011;3(4): 302-8.
5. Bimmel R, Bakker A, Bosma B, Michielsen J. Paediatric hip fractures: a systematic review of incidence, treatment options and complications. Acta Orthopædica Belgica. 2010;76(1):7-13.
6. Sink E, Kim YJ. Fractures and traumatic dislocations of the hip in children. In: Flynn JM ed. Rockwood and Wilkins. Fracture in Children. 8th ed. Phillidelphia: Lippincott Williams & Wilkins; 2014.

**Cite this article as:** Kumara HC, Nasution AM, Jiwandono BS, Satriad AB, Utomo P. Open femoral neck fracture of 14 years old boy treated by emergency internal fixation with additional osteomuscular pedicle graft: case report. Int J Res Orthop 2020;6:1303-5.