

## Original Research Article

# Functional outcome of minimally invasive plate osteosynthesis with the use of locking plate in fracture distal end of tibia

Prashant Kamble<sup>1</sup>, Nandan Marathe<sup>1\*</sup>, Sudhir Sharan<sup>2</sup>, Ayush Sharma<sup>3</sup>, Ashwin Sathe<sup>1</sup>,  
Abhinav Jogani<sup>1</sup>

<sup>1</sup>Department of Orthopedics, Seth GS Medical College and KEM Hospital, Parel, Mumbai, Maharashtra, India

<sup>2</sup>Department of Orthopedics, LTMMC and LTMGH, Sion, Mumbai, Maharashtra, India

<sup>3</sup>Central Railway Hospital, Byculla, Mumbai, Maharashtra, India

**Received:** 02 August 2020

**Revised:** 14 September 2020

**Accepted:** 15 September 2020

### \*Correspondence:

Dr. Nandan Marathe,

E-mail: [nandanmarathe88@gmail.com](mailto:nandanmarathe88@gmail.com)

**Copyright:** © the author(s), publisher and licensee Medip Academy. This is an open-access article distributed under the terms of the Creative Commons Attribution Non-Commercial License, which permits unrestricted non-commercial use, distribution, and reproduction in any medium, provided the original work is properly cited.

## ABSTRACT

**Background :** Distal tibia fractures or pilon fractures are usually the result of combined compressive and shearing forces, which may lead to instability of the metaphysis. Poor vascularity, lack of muscle cover and frequent intra-articular extension often make these fractures very challenging to manage. There are plenty of options available to treat a distal tibia fracture which includes intramedullary nailing, external fixation, open reduction and internal fixation and minimally invasive plate osteosynthesis (MIPO). The aim of this study was to evaluate the results of MIPO with respect to the healing of fracture site, the incidences of complications and to conclude whether MIPO circumvents the problems of formal open reduction and fixation with other implants.

**Methods:** A series of forty patients with fracture of the distal tibia on preoperative X-rays were treated with minimally invasive plate osteosynthesis using pre-contoured locking plates from June 2014 to October 2018 and followed up at regular intervals with X-rays and monitoring for complications.

**Result:** The functional scores were evaluated using Teeny and Wiss clinical rating system for ankle joints. Thirty-two patients had an 'Excellent' or 'Good' outcome. One patient was diagnosed with a soft tissue complication and delayed union and 3 patients were diagnosed with malunion without significant functional disability at follow up.

**Conclusion:** Minimally invasive plate osteosynthesis with pre-contoured locking plates is associated with high union rate and good functional outcomes. It is an effective treatment modality for distal tibia fractures.

**Keywords:** Distal tibia, Tibia fracture, Internal fixation, MIPO

## INTRODUCTION

Distal tibial fractures, also known as pilon fractures or plafond fractures, occur in the weight-bearing region of the distal tibia. These fractures constitute about 5 to 10 percent of the tibial fractures. Distal tibia fractures are commonly seen with motor vehicle accidents, fall from heights, industrial injuries and are the result of combined compressive and shearing forces.<sup>1</sup> The complexity of these fractures is increased by frequent intra-articular extension,

comminution, compromised soft tissue cover over the region and precarious blood supply. An attempt for open reduction, internal fixation can result in increased disruption of blood supply of the region leading to complications like wound healing problems, infections and non-unions.<sup>2</sup> Distal tibial fractures are difficult to treat with closed reduction and nailing because of their proximity to the ankle joint and difficulties in fixation. To bypass these problems, MIPO has been introduced, enabling the fixation of these complex fractures with

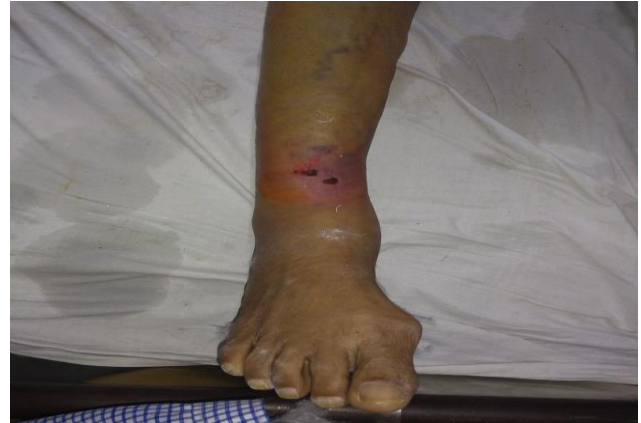minimal disruption of overlying soft tissues.<sup>3-5</sup> MIPO aims to achieve correct limb length and rotational, angular alignment without disrupting the fracture hematoma or causing further periosteal damage. Healing takes place by formation of callus from fracture hematoma and periosteum. Reviewed the outcomes of 40 patients with distal tibia with/without fibula fracture treated with principles of MIPO. The aim of this prospective study was to determine the functional outcome and complications of minimally invasive plate osteosynthesis in cases with closed distal end tibia fracture.

## METHODS

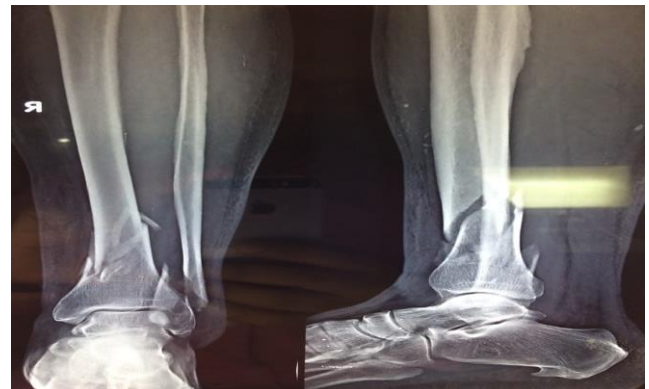A series of forty patients with distal tibia fractures treated with minimally invasive open reduction and stabilization with pre-contoured locking plates between June 2014 and October 2018 at a tertiary care hospital were prospectively analyzed. Adult patients over 18 years of age, with closed fractures of the distal tibial metaphysis and diaphysis without intra-articular fracture extension were included in the study. Patients with open fractures, neurovascular deficits, compartment syndrome and polytrauma patients were excluded from the study. This study was approved by the ethics committee of the institution and informed consent were taken from all the participants.

Classified the closed injuries according to Oestern tscherne soft tissue injury classification (Figure 1). Grade 0 and 1 injuria were operated within 48 hours, however in those patients with grade 2, 3 injury, sufficient time was given for soft tissue healing prior to surgical intervention. Preoperative anterior-posterior and lateral X-ray views were taken at the time of presentation (Figure 2). CT scans were done to check for intra-articular extension of the fracture. Analgesics, anti-inflammatory drugs, splinting, elevation and other anti-oedema measures were followed during the preoperative period. Not used external fixator in any patient and all patients were immobilized using above knee POP slab prior to surgery. After subsidence of the oedema, the patients were treated with minimally invasive closed reduction and internal fixation using pre-contoured locking plates, under antibiotic coverage. All the patients were operated in supine position, under pneumatic tourniquet with aseptic precautions and image guidance.<sup>6</sup> In those with associated fibula fracture, fibula was reduced first and fixed with an intramedullary K-wire. Tibia was reduced subsequently with manual traction and manipulation under C-arm fluoroscopy. Once the reduction was acceptable, a 2-3 cm incision was taken on medial malleolus (Figure 3) protecting the saphenous vein and nerve and a subcutaneous plane was prepared with curved hemostat and blunt chisel without causing periosteal damage. One 4.5 mm pre-contoured locking plate was pushed along the epi-periosteal plane (Figure 4, 5). Reduction and plate position were confirmed under fluoroscopy and once it was in acceptable position, the plate was fixed with multiple locking screws taking separate stab incisions over the plate. All patients were operated by a single surgeon who is also the lead author of

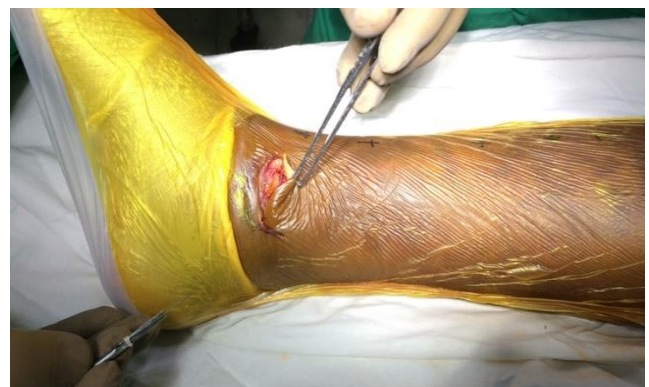this paper. Post-operatively, the patients were put on physiotherapy exercises (knee and ankle range of motion exercises) gradually to prevent ankle and knee joint stiffness. The patients were discharged on postoperative day 3 after a post-operative X-ray (Figure 6). Suture removal was done two weeks after the surgery. After suture removal, the patients were allowed partial weight bearing with crutches for 6 weeks followed by gradual full weight bearing.



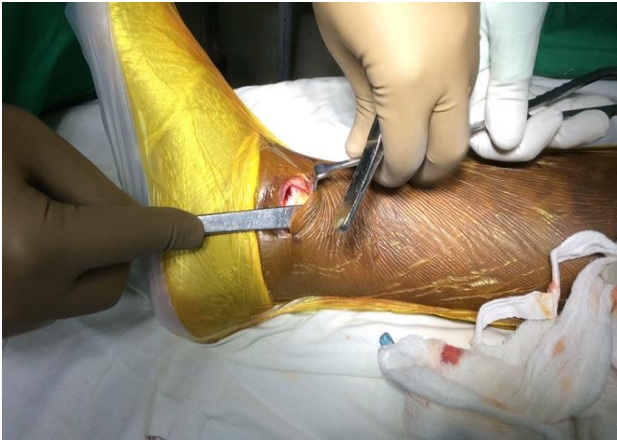**Figure 1: Pre-operative precarious soft tissue coverage (classified according to Oestern tscherne classification).**



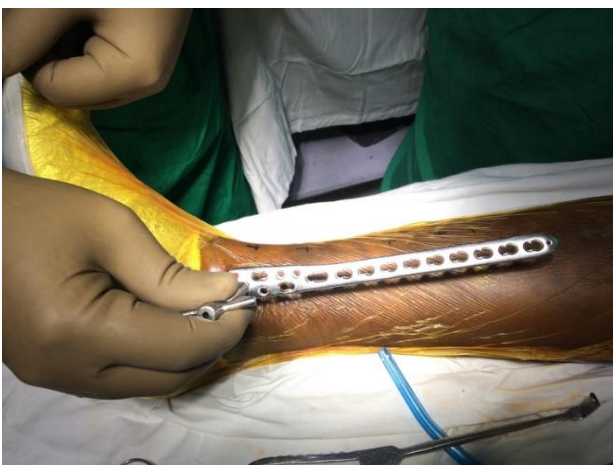**Figure 2: Pre-operative AP and lateral radiograph.**



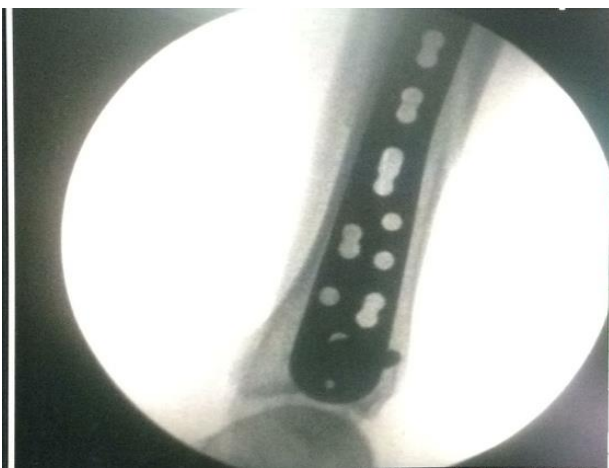**Figure 3: Intra-operative mini-incision taken over medial malleolus.**



**Figure 4: Subcutaneous epi-periosteal plane dissected using a periosteum elevator.**



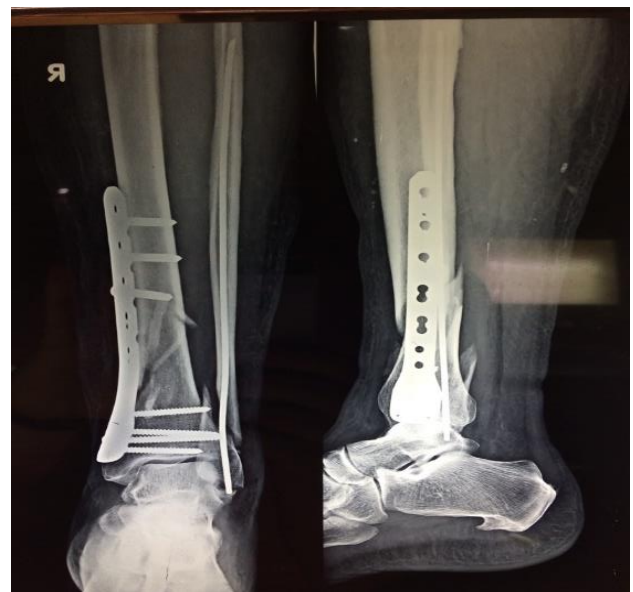**Figure 5: Plate pushed along epi-periosteal plane.**



**Figure 6: Intraoperative radiograph to confirming plate position and reduction.**

Patients were followed up and X-rays were done at fourth week, eighth week, and twelfth week postoperatively or until bone union was achieved (whichever was earlier) (Figure 7). Thereafter, X-rays were repeated as and when required. The postoperative assessment was done for the

ankle range of motion, pain grading (-no pain, + occasional pain, ++ pain after walking a distance, +++ pain at rest), loss of motor power or weakness and incidence of complications. Functional results were assessed using the clinical rating system by Teeny and Wiss.<sup>7</sup> All the patients with a normal ankle function without interference in work, no pain or swelling, and a full range of motion were classified as 'excellent'. The patients with some swelling, but no or occasional pain, slight restriction of full flexion otherwise normal and no interference in day-to-day work were classified as 'good'; patients with pain after exercise, swelling, small restriction in range of motion at the ankle and hampering the patient in the day-to-day activities were classified as 'fair' and those with severely hampered day-to-day activities, pain at rest and severely restricted range of motion were classified as 'poor'. These results were compared with the results from other studies.



**Figure 7: Immediate post-operative AP and lateral X-ray on day 3.**

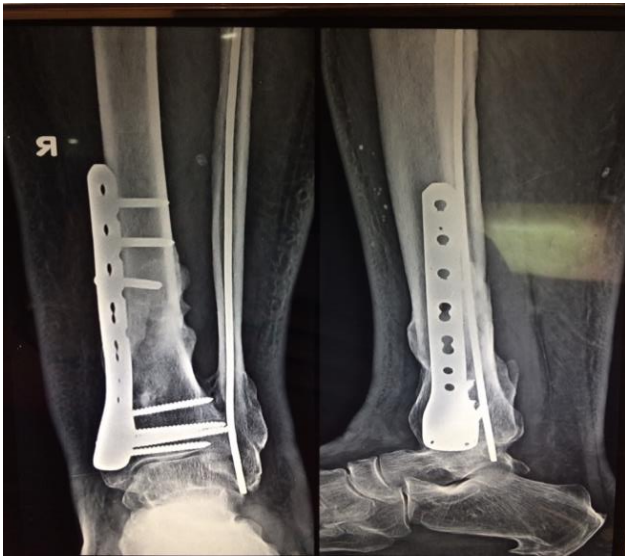Statistical analysis: SPSS 17.0 was used to analyze data and p value of  $\leq 0.05$  was taken to indicate statistical significance. Used Microsoft office excel (2013) software for the master-chart and to draw graphs.

## RESULTS

Amongst the forty patients, twenty-seven (67.5%) were males and thirteen (22.5%) were females. Three patients were in the age group of 20-30 years, twelve were in 30-40 years' age group, eighteen patients belonged to the age group of 40-50 years, six patients were between 50-60 years and only one patient more than 60 years (Figure 8). The youngest patient in the study was 23 years old. The mean age was 43 years. Twenty-three patients (57.5%) had a right tibia fracture and seventeen (42.5%) had a left tibia fracture. Most common mode of injury was motor vehicle accident (twenty-nine patients-72.5%), followed by fall from height (nine patients-22.5%) and direct trauma or fall

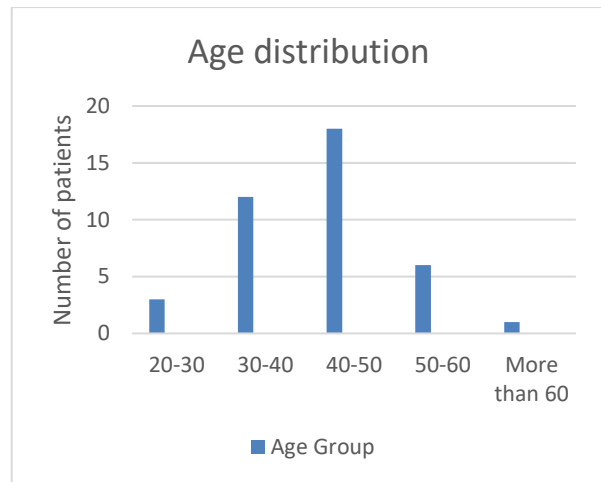


of a heavy object (two patients-5%). None of these patients required any other surgical intervention apart from the intervention for tibia fracture. Most of the fractures were classified as AO Type-A1 (twenty-three patients), thirteen patients were classified under AO Type-A2, four patients were classified under AO Type-A3 (Figure 9).<sup>8</sup> Twenty-eight patients (70%) had an associated ipsilateral fibula fracture, 13 of which were treated with a closed reduction and intramedullary nail for the same. All patients were operated within one week of the injury and the mean time between trauma to surgery was 3 days.

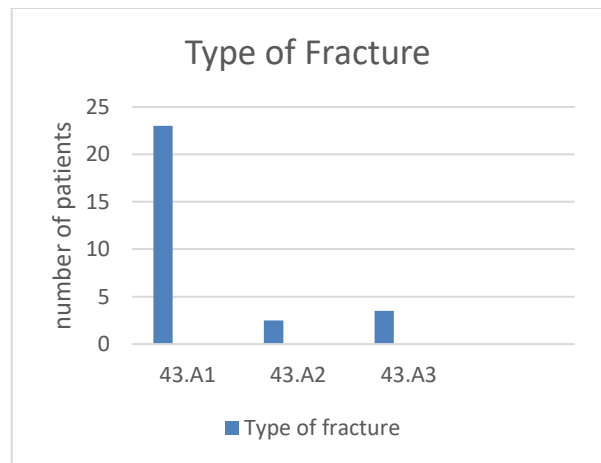


**Figure 8: X-ray taken at 6 months follow-up for bony union.**

The average duration of surgery was 1 hour 13 minutes and average blood loss was 75 ml. During the postoperative period, one patient developed wound dehiscence. The patient was treated with antibiotics, formal debridement and wash. The patient developed a soft tissue defect which required a flap coverage by the plastic surgeon from the same institute of study. The duration for the bone union was less than 10 weeks in twenty-four patients, 10-12 weeks in twelve patients. Three patients showed bone union between 12 to 14 weeks. One patient with soft tissue problems was diagnosed with a delayed union and united at 28 weeks without further orthopedic intervention. All except 3 fractures united anatomically ( $<5^{\circ}$  varus/valgus,  $<5^{\circ}$  rotation,  $<1$  cm shortening). The mean range of motion at the ankle joint was  $25^{\circ}$  of dorsiflexion and  $38^{\circ}$  of plantar flexion. Twenty-three patients had no pain at the end of one year, ten had an occasional pain, six patients had pain after exercise, only one patient complained of pain at the fracture site or ankle joint by the end of one year. Fifteen patients (37.5%) had an ‘Excellent’ outcome on Teeny and Wiss clinical rating system. Eighteen patients (45%) had a ‘good’ outcome, six patients (15%) had a ‘fair’ outcome and only one patient (2.5%) had a ‘poor’ outcome for the ankle joint (Figure 10). At the final follow up, 3 patients presented with mal-union ( $8^{\circ}$  valgus,  $6^{\circ}$  and  $8^{\circ}$  varus), but with no significant functional disability.



**Figure 9: Age distribution of the study population.**



**Figure 10: Classification according to type of fracture.**

## DISCUSSION

Distal tibia fractures are often resulting of vehicular accidents and are often comminuted. Treatment options are closed reduction and above knee cast for displaced or minimally displaced fractures and surgical stabilization for displaced or unstable fractures. Surgical fixation techniques use various implants such as formal open reduction and internal fixation with plates, closed reduction and internal fixation with intramedullary nails, minimally invasive plate osteosynthesis with pre-contoured locking plates and external fixators for compound fractures. Each modality of treatment has its own advantages and its disadvantages. Closed reduction and cast immobilization require a longer duration of treatment which most often leads to stiffness of the adjacent joints. Though nailing is less invasive compared with traditional plating, achieving reduction and fixation can be difficult because of the shorter distal fragment.<sup>9-11</sup> Traditional open reduction and plating is associated with wound complications and higher infection rate. MIPO has emerged as a newer modality of treatment which seeks to circumvent the disadvantages seen with other modalities

of treatment because it minimizes soft tissue compromise, decreases devascularization of fracture fragments, fracture hematoma is preserved, has lesser risk of infection and re-fracture.<sup>12</sup>

In this series, results of forty cases of fracture distal tibia treated with minimally invasive plate osteosynthesis were studied over two years and followed up. The results were compared with those from previously published literature. In this series, most of the patients were males (67.5%; Male: Female ratio 2:1), most probably because of the fact that the fracture is a common occurrence in vehicular accidents (72.5 percent) which are more common amongst the male population. This was comparable with the series by Gerber and Ganz (M:F ratio 2:1) but another series by Helfet et al. (M:F ratio 1:1.9) showed discrepancy with the present series.<sup>12,13</sup> In this series, the mean average age at presentation was 43 years. The fracture was seen, most commonly, in the active age group of 30-50 years. The age incidence is comparable with other series by Helfet et al. (43 years); and Gerber and Ganz (50 years).<sup>13</sup>

In this series, most of the fractures were classified as AO Type-A1 (57.5%), AO Type-A2 (32.5%) and AO Type-A3 (10%). All the fractures were AO Type-A fractures which are the most common fracture-type seen overall. The most common associated injury with the distal tibia fracture was ipsilateral fibula fracture (seen in 70% cases). Thirteen of the twenty-eight patients required open reduction and internal fixation with reconstruction plates in order to achieve the length of the fibula, anatomical reduction of the fibula and ankle stability. Amongst the thirteen patients treated with fibular fixation, eight patients had 'excellent' outcomes and five had 'Good outcomes' at the end of one year. Amongst the fifteen patients treated without fibular fixation, seven patients had 'excellent' outcomes and eight patients had 'good' outcomes with none of the patients having a fair or poor outcome (p value of 0.45 by Fisher's exact test - not significant). The study 'The role of fibular fixation in distal tibial fractures.'<sup>14</sup> concludes that fibular fracture fixation is not essential unless a syndesmotic injury is diagnosed. Our study has similar findings, with all fibular fractures not requiring fixation when treated with minimally invasive distal tibial plate osteosynthesis for the distal tibial fracture. However, our study does not evaluate the role of fibular fixation in cases with syndesmotic injuries. Only one patient developed a soft tissue defect which required a flap coverage by the plastic surgeons and the fracture united late after about seven months.

The average duration of surgery was 1 hour and 13 minutes, was not significantly different from the duration required for traditional open reduction and internal fixation. This was possibly because of the larger number of C-arm images required with an image intensifier during minimally invasive plate osteosynthesis compared to traditional open reduction and plating. This was comparable to a study by Devkota et al, which also showed similar operative times.<sup>15</sup> The mean blood loss during the

surgery for distal tibial fracture using minimally invasive plate osteosynthesis was 75 ml which is significantly less compared to the traditional open reduction internal fixation with plates. This is possibly due to the smaller incisions and non-usage of negative suction drains in cases of MIPO for distal tibial fractures. One of the disadvantages of this method is the increased radiation exposure, however with experience the need for imaging reduces.

Only one patient developed delayed union and none of the patients developed non-union. These were comparable with other studies, by Helfet et al, who reported no complications and; Gerber and Ganz et al, in which there was one case with delayed union and one case of wound infection.<sup>12,13</sup> The rates of complications related to wound healing seem to be less with minimally invasive plate osteosynthesis because of the lesser soft tissue handling and lesser dissection involved in this procedure. In this series, it took an average of 10 weeks to begin full weight-bearing (8-14 weeks) in uncomplicated cases. This was comparable to the results in other series which showed earlier weight-bearing with 10.7 weeks in the series by Helfet et al, and 11 weeks in the series by Gerber and Ganz et al.<sup>12,13</sup> In the present series, a complete bone union was achieved by 7 to 13 weeks after surgery with an average of 10 weeks. This was earlier compared to other modalities of treatment like plaster casting which required 19.4 weeks in a series by Kay et al, AO plating which required 16.4 - 19.7 weeks for union in the series by Linden et al, and external fixator which required 15.6 weeks in the series by De Bastiani et al.<sup>16,17</sup> When all the cases in the study were taken into account (including the cases with complications) the average number of weeks for bone union increased to around 10.5 weeks. The earlier rate of union with minimally invasive plate osteosynthesis is because of preservation of the hematoma at the fracture site and the principle of biological plating which provides a stable fixation, yet allowing micromotion at the fracture site promoting early union.

In this series, the average ankle range of motion was 38° of Plantar flexion and 25° of dorsiflexion. Thirty-three patients had 'excellent' or 'good' outcomes at the end of one year, six patients had 'fair' outcomes and only one patient had a 'poor' result on the Teeny and Wiss clinical ankle rating system. The one patient who had a poor result had gone through multiple procedures for the complication. Because of the long periods of immobilization, the patient had a significantly reduced range of motion at the ankle joint as well as pain which frequently hampered their activities of daily living. These findings suggest that majority patients who do not develop complications have good or excellent outcomes. As minimally invasive plate osteosynthesis addresses the problem to decrease the complications, the results get converted to a better functionality of the ankle and the foot. The study by Cheng et al. has found no significant differences between the treatment outcomes when

minimally invasive plate osteosynthesis was compared with traditional open reduction and internal fixations.<sup>18</sup>

However, one of the limitations of our study is that it is non-comparative. The results have been compared to the results of other studies in the past. A well-designed clinical trial, comparing different modalities of treatment, with a larger sample size and longer duration of follow-up is necessary to compare various modalities of treatment and also to prove the superiority of minimally invasive plate osteosynthesis with pre-contoured locking plates over other forms of treatment.

This study concludes that there is no difference in the duration of surgery compared to other modalities of treatment from other studies. There appears to be lesser blood loss with minimally invasive plate osteosynthesis. The rates of wound healing problems and other complications are lesser compared to complications seen with various modalities of treatment in the other studies. However, our study does not evaluate patients with syndesmotic injuries. The bone union and weight-bearing occur earlier than that seen with other modalities. The proportion of patients having an excellent, good or fair outcome at the end of one year by Teeny and Wiss clinical rating system is significantly larger than patients having poor functional results after minimally invasive plate osteosynthesis.

*Funding: No funding sources*

*Conflict of interest: None declared*

*Ethical approval: The study was approved by the institutional ethics committee*

## REFERENCES

1. Rockwood CA, Bucholz RW, Green DP, Court-Brown CM, Heckman JD, Tornetta P. Rockwood and Green's Fractures in Adults: Wolters Kluwer Health/Lippincott Williams and Wilkins. 2010;2213.
2. Borrelli J Jr, Prickett W, Song E, Becker D, Ricci W. Extraosseous blood supply of the tibia and the effects of different plating techniques: a human cadaveric study. J Orthop Trauma. 2002;16(10):691-5.
3. Brumback RJ, McGarvey WC. Fractures of the tibial plafond. Evolving treatment concepts for the pilon fracture. Orthop Clin North Am. 1995;26(2):273-85.
4. Oh CW, Kyung HS, Park IH, Kim PT, Ihn JC. Distal tibia metaphyseal fractures treated by percutaneous plate osteosynthesis. Clin Orthop Relat Res. 2003;408:286-91.
5. Collinge C, Sanders R, DiPasquale T. Treatment of complex tibial periarticular fractures using percutaneous techniques. Clin Orthop Relat Res. 2000;375:69-77.
6. Leunig M, Hertel R, Siebenrock KA, Ballmer FT, Mast JW, Ganz R. The evolution of indirect reduction techniques for the treatment of fractures. Clin Orthop Relat Res. 2000;375:7-14.
7. Teeny SM, Wiss DA. Open reduction and internal fixation of tibial plafond fractures. Variables contributing to poor results and complications. Clin Orthop Relat Res. 1993;292:108-17.
8. Müller ME, Nazarian S, Koch P, Schatzker J. The comprehensive classification of fractures of long bones. Berlin: Springer Verlag. 1990.
9. Daolagupu AK, Mudgal A, Agarwala V, Dutta KK. A comparative study of intramedullary interlocking nailing and minimally invasive plate osteosynthesis in extra articular distal tibial fractures. Indian J Orthop. 2017;51(3):292-8.
10. Dogra AS, Ruiz AL, Thompson NS, Nolan PC. Diaphyseal distal tibial fractures--treatment with a shortened intramedullary nail: a review of 15 cases. Injury. 2000;31(10):799-804.
11. Robinson CM, McLauchlan GJ, McLean IP, Court-Brown CM. Distal metaphyseal fractures of the tibia with minimal involvement of the ankle. Classification and treatment by locked intramedullary nailing. J Bone Joint Surg Br. 1995;77(5):781-7.
12. Helfet DL, Suk M. Minimally invasive percutaneous plate osteosynthesis of fractures of the distal tibia. Instr Course Lect. 2004;53:471-5.
13. Gerber C, Mast JW, Ganz R. Biological internal fixation of fractures. Arch Orthop Trauma Surg. 1990;109(6):295-303.
14. Vasanad GH, Antin SM, Akkimaradi RC, Policepatil P, Naikawadi G. The Role of Fibular Fixation in Distal Tibial Fractures. J Clin Diagn Res. 2016;10(4):1.
15. Devkota P, Khan JA, Shrestha SK, Acharya BM, Pradhan NS, Mainali LP et al. Minimally invasive plate osteosynthesis for distal tibial fractures. J Orthop Surg. 2014;22(3):299-303.
16. van der Linden W, Larsson K. Plate fixation versus conservative treatment of tibial shaft fractures. A randomized trial. J Bone Joint Surg Am. 1979;61(6A):873-8.
17. De Bastiani G, Aldegheri R, Renzi Brivio L. The treatment of fractures with a dynamic axial fixator. J Bone Joint Surg Br. 1984;66(4):538-45.
18. Cheng W, Li Y, Manyi W. Comparison study of two surgical options for distal tibia fracture--minimally invasive plate osteosynthesis vs. open reduction and internal fixation. Int Orthop. 2011;35(5):737-42.

**Cite this article as:** Kamble P, Marathe N, Sharan S, Sharma A, Sathe A, Jogani A. Functional outcome of minimally invasive plate osteosynthesis with the use of locking plate in fracture distal end of tibia. Int J Res Orthop 2020;6:xxx-xx.