

## Original Research Article

# Functional outcome of instrumented and non-instrumented fusion in lumbar canal stenosis

Ansari Muqtadeer Abdul Aziz<sup>1</sup>, Nair Pradeepkumar Sasidharan<sup>1\*</sup>,  
Ansari Ishtyaque Abdul Aziz<sup>2</sup>, Venkatesh Dattatray Sonkawade<sup>1</sup>

<sup>1</sup>Department of Orthopaedics, Government Medical College and Hospital, Aurangabad, Maharashtra, India

<sup>2</sup>Department of Neurosurgery, MGM Medical College, Aurangabad, Maharashtra, India

**Received:** 17 July 2020

**Revised:** 02 August 2020

**Accepted:** 03 August 2020

### \*Correspondence:

Dr. Nair Pradeepkumar Sasidharan,

E-mail: [nairpradeep1234@gmail.com](mailto:nairpradeep1234@gmail.com)

**Copyright:** © the author(s), publisher and licensee Medip Academy. This is an open-access article distributed under the terms of the Creative Commons Attribution Non-Commercial License, which permits unrestricted non-commercial use, distribution, and reproduction in any medium, provided the original work is properly cited.

## ABSTRACT

**Background:** Lumbar canal stenosis (LSS) is a source of significant morbidity and economic burden in the Indian population. Spinal canal compression is the sine qua non of lumbar canal stenosis but whether instrumentation should be done or not is the major dilemma. In this study, we aim to compare the functional outcome of instrumented versus non-instrumented fusions for the treatment of lumbar stenosis along with the post-operative complications and cost-effectiveness of both procedures.

**Methods:** This study was conducted at a tertiary-care medical college and hospital, Aurangabad specializing in post-graduate training, where all patients who underwent surgical treatment between May 2016 and May 2018 were included. Patients were assessed using the modified Oswestry disability index (MODI) and visual analogue scale (VAS). These evaluations were done at 3, 6, 12 and 24 months.

**Results:** We found similar pain relief and stabilization in both the groups in the initial post-operative period, but after 2 years, there was a significant difference ( $p=0.0001$ ) between the two groups in terms of VAS (back) and MODI score. Complication rate was higher in instrumented patients.

**Conclusions:** Patient selection is the most important thing in the management of lumbar canal stenosis. We believe that, with the flowchart on the management of lumbar canal stenosis, it would help choosing patients better as to who would require instrumented fusion. Non-instrumented fusions might cost less and have fewer complications, but the overall outcome of the patient in the future should be kept in mind.

**Keywords:** Lumbar canal stenosis, Modified Oswestry disability index, Instrumented lumbar fusion

## INTRODUCTION

Lumbar canal stenosis is a progressive disorder that involves the entire spinal motion segment compressing the neural elements with the resulting venous congestion and hypertension causing intermittent neurogenic claudication (pain occurring in the legs with less than 100 metres of walking) requiring frequent rests to walk a distance. Sensori-motor disturbances and bowel/bladder involvement may be seen in rare cases.<sup>1</sup> Lumbar canal

stenosis is an anatomical diagnosis rather than a pathological one. Stenosis can occur centrally or in the lateral recess either due to a hypertrophied ligamentum flavum, degenerated disc, bony spurs, arthritis or tumours of the spine. Non-operative treatment can be offered to the patients in the form of analgesics, activity modification, braces and epidural steroids which might help the patient in decreasing the pain to some extent. However, with sustained symptoms and failure of conservative treatment over a long time, surgical

management becomes the need of the hour.<sup>2</sup> To relieve the pressure on the spinal cord and nerve roots, decompression laminectomy is done. The critical decision regarding management is the next step after decompression, whether fusion is necessary and if necessary, whether it should be instrumented or non-instrumented. Many surgeons have tried to find an answer to this question and provide a surgical solution which is best suited to the patient. There are proponents of both instrumented and non-instrumented fusion with varying results.<sup>3,4</sup> Another important aspect while deciding the most appropriate management is the cost of the procedure.<sup>5</sup> So in this study we attempt: to compare functional outcome of instrumented versus non-instrumented fusions for the treatment of lumbar stenosis and to assess the post-operative complications and cost-effectiveness of both procedures.

## METHODS

All patients admitted in a tertiary-care medical college and hospital, Aurangabad specializing in post-graduate training with lower back pain for surgery between May 2016 to May 2018 were evaluated for 24 months post-surgery. Symptomatic degenerative lumbar stenosis affecting patient lifestyle was the main indication for surgery. Pain, function and quality of life were evaluated according to modified Oswestry disability index (MODI) (Table 1) and VAS.<sup>6-9</sup> Pre-operative X-rays of lumbar spine (Upright antero-posterior and lateral view), CT and MRI scans were taken for assessing and confirming the clinical findings. General work-up of the patient was done (Complete blood count, Liver function test, kidney function test, blood sugar level, prothrombin time, arterial doppler of the affected limb, serology testing, 2-D echocardiography) along with any specific investigations if advised by physician and anaesthetist.

**Table 1: Modified Oswestry disability index.**

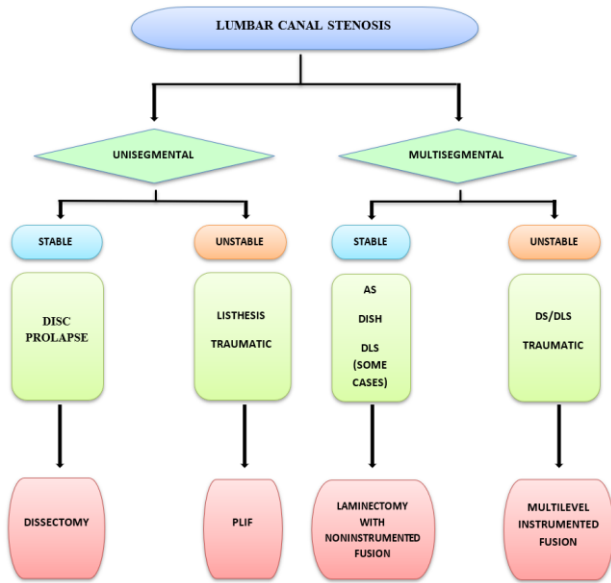
S. no.	Criteria	0	1	2	3	4	5
1	Pain intensity	-	-	-	-	-	-
2	Personal care	-	-	-	-	-	-
3	Lifting	-	-	-	-	-	-
4	Walking	-	-	-	-	-	-
5	Travelling	-	-	-	-	-	-
6	Sitting	-	-	-	-	-	-
7	Standing	-	-	-	-	-	-
8	Sleeping	-	-	-	-	-	-
9	Social life	-	-	-	-	-	-
10	Employment/ homemaking	-	-	-	-	-	-

### Surgical technique

Patient selection was done according to the flowchart given in Figure 1. Patient was positioned prone with padding done over the chest and hips. Hips are placed in

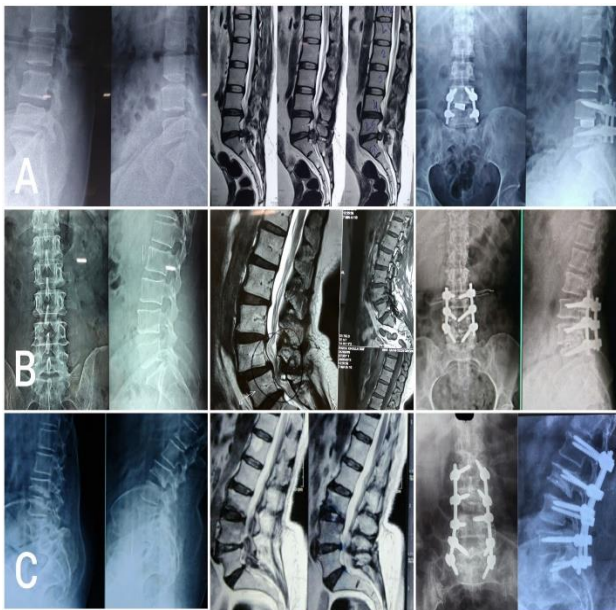
extension and knees are flexed to decrease nerve tension and patient is taped down to the table. Face is supported without any pressure placed on the face and eyes. Intravenous antibiotic (injection linezolid 600 milligrams Intravenously) was administered 30 minutes prior to incision. Shaving of skin hair over surgical site was done 10 minutes before surgery. Foley's catheterization was done. The procedure was carried out under general anaesthesia. Painting of surgical site was done with betadine scrub (7.5%). Draping of surgical site was done. The involved intervertebral disc was visualized with fluoroscopy and marked. A midline incision was taken over the marked disc extending 5 centimetres proximally and distally. Dissection is carried down in the midline through the skin, subcutaneous tissue and fascia to the tip of spinous process. Using electrocautery and with the help of a Cobb's elevator, the muscles are detached subperiosteally in a caudal to cephalad direction to expose the posterior elements. The pars interarticularis was identified and polyaxial pedicular screws were inserted in the vertebra on both sides of the disc, the position of which was then confirmed on fluoroscopy. A working rod was cut and contoured to allow placement over the screws. The spinous process at the affected disc was then removed and Laminectomy was done on the side with more neurological symptoms with the help of a plier. The spinal cord was visualized and packed with gauze pieces and remaining laminectomy is completed.

Foraminotomy was performed and the nerve root was decompressed. Annulotomy was done with the help of blade no. 11 by retracting the thecal sac medially. The entire annulus and nucleus was then removed with curettes and the endplate was prepared. The disc space was thoroughly irrigated with saline. Bone graft was then packed against the anterior annulus followed by insertion of a cage filled with bone graft in such a way that the cage was positioned at the level of midbody of the vertebra or slightly anteriorly so that lordosis is maintained. The remaining space was then filled with bone graft again (in non-instrumented fusion, only bone graft was placed in the disc space). Bone graft can be prepared from the pieces of posterior elements removed or can be taken from the iliac crest. Position of the cage and screws was again confirmed on fluoroscopy and final tightening of the rod was done with mild compression. Gauze pieces are removed and the wound was irrigated with saline. The exposed spinal cord and nerve root was covered with bone wax. An uncharged drain was kept and the wound was closed in layers. Dressing was done. Post-operative X-rays were taken (Figure 2). Patient was kept in intensive care unit (ICU) after surgery for one day for observation of vital parameters. Foley's catheter was removed after 12 hours. Drain was removed after 12-24 hours. Intravenous antibiotics were given for three days followed by five days of oral antibiotics. Patient was mobilized the morning after surgery and discharged three to four days post-operation.



**Figure 1: Management of lumbar canal stenosis.**

AS- ankylosing spondylitis, DISH- diffuse idiopathic skeletal hyperostosis, DLS- degenerative lumbar canal stenosis, DS- degenerative scoliosis, PLIF- posterior lumbar interbody fusion.



**Figure 2: Instrumented lumbar fusion. (A) Pre-operative X-ray, MRI image and post-operative X-ray of PLIF done in a 54 year old male, (B) pre-operative X-ray, MRI image, post-operative X-ray of 2 segment fusion at L3, 4 level, (C) pre-operative X-ray, MRI image, post-operative X-ray of 4 segment fusion at L2-L5 level.**

**Statistical analysis**

Statistical analysis was done on Microsoft excel sheet using SPSS 25, Null hypothesis, paired and unpaired t-test, using Microsoft excel 2010 and Microsoft word 2010.

**RESULTS**

Majority of the patients were in the age group of 50-70 years with the mean age being 57 years and a female preponderance was seen. Our patient group was relatively younger than other similar studies done (Table 2 and 3). Instrumented fusion accounted for about 70% of the total cases. Complications too were greater in the instrumented patients. Two patients developed post-operative infection which was contained using higher antibiotics. 1 patient developed dural tear which was repaired and the patient had an uneventful post-operative recovery. 4 patients also developed adjacent segment degeneration which was found exclusively in instrumented fusion in our study. Out of those four patients, two patients underwent revision surgery and fusion was done at the adjacent unstable segment. The other two patients refused revision surgery. Among the twelve patients who underwent non-instrumented fusion, only one diabetic patient developed complication in the form of post-operative infection which was controlled with insulin and higher antibiotics and follow-up of the patient was taken with good recovery of the patient (Table 4, 5 and Figure 3).

**Table 2: Age distribution of patients.**

Age of patient (in years)	No. of cases	Percentage
31-40	06	15
41-50	07	17.5
51-60	16	40
61-70	08	20
71-80	03	7.5

**Table 3: Sex distribution of patients.**

Sex of patient	No. of cases	Percentage
Male	17	42.5
Female	23	57.5

**Table 4: No. of instrumented and noninstrumented fusions.**

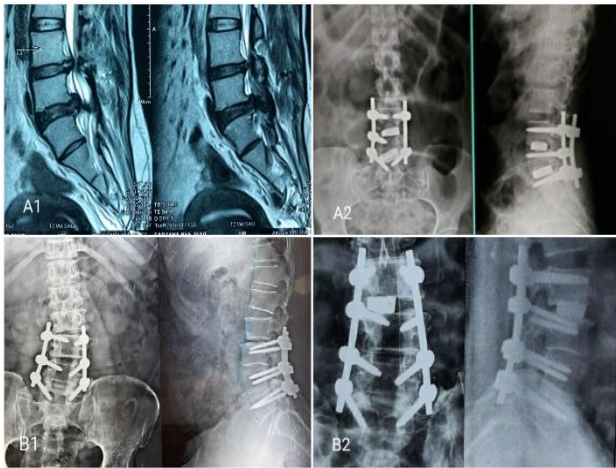Fusion	No. of cases	Complications	Percentage
Instrumented	28	7*	25
Non-instrumented	12	1	8.33

\*including ASD.

**Table 5: Adjacent segment degeneration.**

Levels of ASD	No. of cases		In older patients		In multiple level fusion (>2)	
	I	N	I	N	I	N
1	2	0	2	0	1	0
2 or more	2	0	2	0	2	0

I-instrumented, N-Non-instrumented, good outcome- more than 50% improvement in MODI and VAS.



**Figure 3: Complications of lumbar fusion. (A1 and A2) MRI of failed 2 level discectomy after 1 year managed with 2 level posterior interbody lumbar fusion revision surgery. (B1 and B2) 2 level instrumented fusion at L3-4-5 which developed adjacent segment degeneration (juxtafusion instability) at L2-3 level after 2 years managed with interbody fusion at that level.**

Most of the surgeries done were one level disc fusion amounting for 32 out of 40 cases. As the number of disc spaces fused increased, the expected outcome attained after 2 years was less than ideal (Table 6).

We evaluated the results of VAS and MODI in instrumented and non-instrumented patients with special focus on their outcome 2 years after surgery. While patients in both categories did quite well in the immediate post-operative period, there was a significant ( $p < 0.05$ ) detrimental change in the VAS score of the back and MODI score after 2 years in non-instrumented fusions (Table 7).

**Table 6: Levels of intervertebral spaces fused.**

Levels	No. of cases		Good outcome at 24 months		Percentage	
	I	N	I	N	I	N
1	20	10	16	6	80	60
2	4	2	3	1	75	50
>2	4	0	2	0	50	-

I-instrumented, N-non-instrumented.

**Table 7: VAS and MODI before and after surgery.**

	VAS (back)		VAS (leg)		MODI (%)	
	I	N	I	N	I	N
<b>Pre-operative</b>	6.75±0.97	6.3±1.23	5.2±1.02	5±1.35	66.3±9.25	62.6±8.72
<b>Post-operative (after 6 months)</b>	1.89±0.69	3.25±1.22	0.92±0.72	1.48±0.69	14.7±5.82	19.1±6.89
<b>Post-operative (after 2 years)</b>	2.01±0.95	5.5±0.74	1.12±0.89	2.03±1.25	16.5±7.28	41±5.37
<b>P-value between post-operative values</b>	0.7267	0.0001	0.5512	0.1957	0.3114	0.0001

I-instrumented, N-Non-instrumented.

## DISCUSSION

Conservative treatment used to be the order of the day earlier but with better understanding of the spinal anatomy, advanced imaging and better results, spine surgeries even for degenerative conditions have increased substantially.<sup>10</sup>

In our study, most of our patients belonged to the younger age group as opposed to other studies where the mean age ventured to the higher side.<sup>11,12</sup>

There is a plethora of operative options for lumbar canal stenosis with each offering its fair share of pros and cons. It all depends on the expertise of the surgeon to do a particular procedure.<sup>13</sup> In our institute, for all unstable spines detected on radiography, we added an element of stability by doing some sort of fusion in all our patients.<sup>14</sup> Interbody fusion has shown to improve symptoms with better post-operative spine stability by maintaining disc space after removal of the disc.<sup>15</sup>

Complications of instrumented fusion are definitely greater than that of noninstrumented ones.<sup>16,17</sup> These include a greater operative time, exposure to radiation (fluoroscopy), more bleeding during operation and increased surgery cost.<sup>18</sup> Other complications include injury to the dura, nerve root and blood vessels during surgery and an increased risk of screw pull-out and adjacent segment degeneration (ASD) post-surgery. ASD is an important entity seen on the radiographs. The spinal column is made up of different motion segments which work together to distribute the forces along the spine. Because of fusion, the cranial and caudal segments are mobilized more to make up for the lack of movement at the fused segments. We found that four patients with instrumented fusion documented ASD. All these patients were more than 50 years and three out of those four patients had more than 2 level fusions. Thus, older patients and long segment fusions have a higher risk of development of ASD.<sup>19,20</sup>

These complications sure puts noninstrumented fusion at a higher pedestal but that comes at its own costs. Patients undergoing either fusion techniques show similar pain

relief in the immediate post-operative period, but in the long run, with instrumented fusion, patients had a longer period of relief from back pain and neurological symptoms, improving the patient's quality of life. Eight patients who were treated with noninstrumented fusion had severe backpain after 2 year of operation. This led us to conduct this study to improve our knowledge on this topic.<sup>21-23</sup> Also in all failed surgeries of discectomy, laminectomy or non-instrumented fusions revision surgery would be required and as a rule, all these patients should undergo instrumented fusion.<sup>24</sup>

To further champion the cause of using instrumented fusions, newer advances have been made in the design of screws effectively increasing the pull-out strength of the screws in the form of differential threaded screws and cement impregnated screws. These screws provide a better hold in the pedicle and prove extremely user friendly.

With the improvement seen in the MODI and VAS score even after 2 years in instrumented patients, it is safe to say that instrumented fusion offers a chance to live a sustained pain free life with great satisfaction in almost all the patients.

## CONCLUSION

Patient selection is the most important thing in the management of lumbar canal stenosis. We believe that, with the flowchart on the management of lumbar canal stenosis, it would help choosing patients better as to who would require instrumented fusion. Each procedure should be done according to the needs of the patient. We would like to continue following up the patients and look for long term outcome of these patients thus refining our knowledge on the role of instrumented versus non-instrumented fusion in lumbar canal stenosis.

*Funding: No funding sources*

*Conflict of interest: None declared*

*Ethical approval: Not required*

## REFERENCES

- Gardocki RJ, Park AL. In: Azhar FM, Beaty JH, Canale ST(Eds). *Campbell's Operative Orthopaedics*. Thirteenth edition. Philadelphia. Elsevier; 2017: 1644-1727.
- Katz JN, Lipson SJ, Lew RA, Grobler LJ, Weinstein JN, Brick GW, et al. Lumbar laminectomy alone or with instrumented or noninstrumented arthrodesis in degenerative lumbar spinal stenosis: patient selection costs, and surgical outcomes. *Spine*. 1997;22(10):1123-31
- McCulloch JA. Microdecompression and Noninstrumented Single-level Fusion for Spinal Canal Stenosis With Degenerative Spondylolisthesis. *Spine*. 1998;23(20):2243-52.
- Fischgrund JS. The argument for instrumented decompressive posterolateral fusion for patients with degenerative spondylolisthesis and spinal stenosis. *Spine*. 2004;29(2):173-174.
- Aichmair A, Burgstaller JM, Schwenkglens M, Steurer J, Porchet F, Brunner F, et al. Cost-effectiveness of conservative versus surgical treatment strategies of lumbar spinal stenosis in the Swiss setting: analysis of the prospective multicenter Lumbar Stenosis Outcome Study (LSOS). *Eur Spine J*. 2017;26(2):501-9.
- Davidson M, Keating JL. A comparison of five low back disability questionnaires: reliability and responsiveness. *Phys Ther*. 2002;82(1):8-24.
- Fairbank JC, Pynsent PB. The Oswestry Disability Index. *Spine*. 2000;25(22):2940-52.
- Nishant, Chhabra HS, Kapoor KS. New modified english and hindi oswestry disability index in low back pain patients treated conservatively in Indian population. *Asian Spine J*. 2014;8(5):632-8.
- Haefeli M, Elfering A. Pain assessment. *Eur Spine J*. 2006;15:17-S24.
- Keorochana G, Laohacharoensombat W, Wajanavisit W, Chanplakorn P, Woratanarat P, Chatchaipun P, et al. Functional outcome after decompression and instrumented arthrodesis in degenerative lumbar spinal stenosis: factors influencing unsuccessful outcome change. *J Med Association Thailand*. 2011;94(12):1487-94.
- Liao JC, Chiu PY, Chen WJ, Chen LH, Niu CC. Surgical outcomes after instrumented lumbar surgery in patients of eighty years of age and older. *BMC Musculoskelet Disord*. 2016;17(1):402.
- Marbacher S, Mannion AF. Patient-rated outcome of lumbar fusion in patients with degenerative disease of the lumbar spine. *Spine*. 2016;41(10):893-900.
- Fehlings MJ. Treatment options for lumbar spinal stenosis. *J Neurosurg*. 2010;13(1):36-8.
- Ghogawala Z, Dziura J, Butler WE. Laminectomy plus Fusion versus Laminectomy Alone for Lumbar Spondylolisthesis. *N Engl J Med*. 2016;374(15):1424-34.
- Aziz AM, Aziz AI. Short-term functional evaluation of posterior lumbar interbody fusion done for degenerative spondylolisthesis at L4-L5 level. *J Orthop Traumatol Rehabil*. 2020;12:17-22.
- Fritzell P, Hägg O, Nordwall A. Swedish Lumbar Spine Study Group. Complications in lumbar fusion surgery for chronic low back pain: comparison of three surgical techniques used in a prospective randomized study. A report from the Swedish Lumbar Spine Study Group. *Eur Spine J*. 2003;12(2):178-89.
- Rompe JD, Eysel P, Hopf C. Clinical efficacy of pedicle instrumentation and posterolateral fusion in the symptomatic degenerative lumbar spine. *Eur Spine J*. 1995;4:231-7.
- Kuntz KM, Snider RK, Weinstein JN, Pope MH, Katz JN. Cost-effectiveness of fusion with and without instrumentation for patients with degenerative spondylolisthesis and spinal stenosis. *Spine*. 2000;25(9):1132-9.

19. Fox MW, Onofrio BM, Onofrio BM, Hanssen AD. Clinical outcomes and radiological instability following decompressive lumbar laminectomy for degenerative spinal stenosis: a comparison of patients undergoing concomitant arthrodesis versus decompression alone. *J Neurosurg.* 1996;85(5):793-802.
20. Li CD, Yu ZR, Liu XY, Li H. Influence Factors of Adjacent Segment Degeneration After Instrumented Lumbar Fusion. *Zhonghua Wai Ke Za Zhi.* 2006;44(4):246-8.
21. Andersen T, Christensen FB, Niedermann B, Helmig P, Høy K, Hansen ES, et al. Impact of instrumentation in lumbar spinal fusion in elderly patients: 71 patients followed for 2-7 years. *Acta Orthop.* 2009;80(4):445-50.
22. Greenway FE, Papadopoulos MC. Fusion surgery for lumbar spinal stenosis?. *J Spine Surg.* 2016;2(2):154-7.
23. Robinson Y, Michaëlsson K, Sandén B. Instrumentation in lumbar fusion improves back pain but not quality of life 2 years after surgery. A study of 1,310 patients with degenerative disc disease from the Swedish Spine Register Swespine. *Acta Orthop.* 2013;84(1):7-11.
24. Elgafy H, Vaccaro AR, Chapman JR, Dvorak MF. Rationale of revision lumbar spine surgery. *Global Spine J.* 2012;2(1):7-14.

**Cite this article as:** Aziz AMA, Sasidharan NP, Ansari IAA, Sonkawade VD. Functional outcome of instrumented and non-instrumented fusion in lumbar canal stenosis. *Int J Res Orthop* 2020;6:981-6.