

Original Research Article

Importance of calculating various casting indices in predicting radiological outcomes of paediatric forearm fractures

Pyntngen Kharbamon^{1*}, Binoti A. Sheth², Pankaj Pawar², Siddhart Parekh³,
Rishabh Jaiswal⁴, Umesh Kanade⁵

¹Consultant Orthopedic Surgeon, Woodland Hospital, Shillong, Meghalaya, India

²Department of Orthopaedics, Lok Manya Tilak Medical College and Hospital, Sion, Mumbai, Maharashtra, India

³Consultant Orthopedic Surgeon, Unity Hospital, Vasad, Gujarat, India

⁴Department of Orthopaedics, Nanavati Super Speciality Hospital, Mumbai, Maharashtra, India

⁵Department of Orthopedics, Bharti Vidyapeeth Medical College and Hospital, Pune, Maharashtra, India

Received: 14 June 2020

Revised: 31 July 2020

Accepted: 01 August 2020

*Correspondence:

Dr. Pyntngen Kharbamon,

E-mail: pkbamon@gmail.com

Copyright: © the author(s), publisher and licensee Medip Academy. This is an open-access article distributed under the terms of the Creative Commons Attribution Non-Commercial License, which permits unrestricted non-commercial use, distribution, and reproduction in any medium, provided the original work is properly cited.

ABSTRACT

Background: The present study is aimed at determining the importance of various casting indices in predicting the outcome of paediatric forearm fractures treated with closed reduction and plaster application in our department.

Methods: Thirty children, aged 5 to 15 years, with closed forearm fractures not requiring surgical fixation were included to assess their casting indices and radiological outcomes using X-rays. After satisfactory casting, patients were followed up weekly till 6 weeks with anteroposterior (AP) and lateral X-ray.

Results: Acceptable reduction was achieved in 26 cases, while re-manipulation was done in 4 cases. Cast Index ranged from 0.80 ± 0.09 at first week to 0.78 ± 0.09 at 6 weeks, Padding Index was 0.30 ± 0.04 at first week and increased to 0.31 ± 0.03 at 6 weeks, Canterbury Index was 1.07 ± 0.24 at first week and 1.07 ± 0.78 at 6 weeks, Gap Index 0.15 ± 0.02 remained the same throughout, and Three Point Index changed from 0.81 ± 0.08 at first week to 0.77 ± 0.18 six weeks. Radial bow of children showed no significant change at various time points of assessment. Rotational mal-alignment was observed in 5 patients, one had a 0.5 cm radial overlap, while none had an ulnar overlap. Radial angulation was observed in five and six children on AP and lateral X-ray respectively. Ulnar angulation was seen in two and one child on AP and lateral X-ray respectively.

Conclusions: Continued use of these casting indices to assess paediatric forearm cast adequacy is supported by this study.

Keywords: Casting indices, Paediatric forearm fracture, Prognosis

INTRODUCTION

Forearm fractures are very common among children, constituting about 40% of all paediatric fractures.¹ They can be the quite challenging as well because of their treatment complexity and risk of complications. Many

shaft injuries in children are effectively treated with closed fracture care but can result in failure. Loss of reduction after closed fracture treatment has been reported in 25 to 39% of cases.² Risk factors associated with re-displacement include non-anatomical reduction, position of forearm after manipulation, surgeon

experience, lack of support, and excess padding.³ But inadequate casting technique has been considered the major cause.⁴ Traditionally assessed subjectively, plaster cast quality is now assessed with the help of various indices so as to provide an objective evaluation of the plaster cast. With the help of antero-posterior (AP) and lateral plain radiographs, these cast indices are based on measurements that use radiological measurements to estimate the quality of cast placement. The present study is aimed at measuring various casting indices for paediatric forearm fractures treated with closed reduction and correlate these indices with radiological outcome of these fractures.

METHODS

Study design and sampling

In this longitudinal study, children with forearm fractures presenting to the emergency of and operated in the Department of Orthopaedics at Lokmanya Tilak Municipal General Hospital and Medical College, Mumbai from June 2016 till May 2017 were included to assess their casting indices and radiological outcomes using AP and lateral X-rays. We included children aged 5 to 15 years, with closed fractures not requiring surgical fixation who presented to our department during the study period. Children who had pathological fractures, associated head injury, associated neurovascular injury, established non-union from previous fractures, unsatisfactory initial reduction, incomplete series of x-rays, bilateral fractures and those with congenital anomalies were excluded from the study. Parents of the children eligible to participate were explained the purpose of the study and informed consent form and child assent form was filled before being included in the study. The study was approved by the Institutional Ethics Committee.

Conservative management of forearm fractures

All fractures in the study were managed conservatively by closed reduction. Fractures were reduced and an assistant held the limb in position of reduction, in a manner that was unobtrusive to the application of the cast. Stockinet was measured, extending 10 cm beyond the limits of the cast and threaded 2-3 inches wide over the upper limb. Soft roll padding was applied gently but snugly, starting from distal to proximal with 50% overlap between successive turns, extending 2-3 cm beyond the edges of the cast. Padding was applied in 2 layers, but was increased over areas of bony prominence or if significant swelling was anticipated. Plaster Of Paris (POP) cast was applied from distal to proximal i.e., from knuckles of the hand (distal palmar crease anteriorly) and covered lower two thirds of arm. Cast was applied snugly compressing padding thickness by 50%. Check X-rays were done after application of cast to confirm the acceptability of reduction. Following cast application, neurovascular status and X-ray was checked and patients

were counselled about signs of neurovascular compromises. All cracks and weak areas were reinforced with more POP locally. Limb elevation was advised to reduce swelling and pain. Physiotherapy of muscles within the plaster and joints outside the plaster was started to ensure early rehabilitation. The patients were reviewed after 1 week and X-ray was done to reaffirm maintenance of reduction.

Radiological assessment

Patients after casting were sent for X-ray for reaffirmation of fracture reduction. Once satisfied, they were further followed up through weekly visits in the OPD. The patients were advised a true AP and lateral x-ray. Each weekly X-rays were assessed for radial bow, rotational mal-alignment, angulation in both sagittal and coronal plane, overlap in both sagittal and coronal plane and displacements. The various casting indices that were measured were Cast index, Padding index, Canterbury index, Gap index and Three-point index.⁵⁻⁸ Sequential measurement of these indices are taken at each visit and data tabulated. Each index is described below

Cast index

The cast index was proposed by Chess et al and is calculated on the basis of the cast geometry at the fracture site, such that Cast index = inner diameter of the cast at fracture site in lateral view/ inner diameter of the fracture cast at fracture site in AP view (Figure 1, Cast index = x/y).⁵

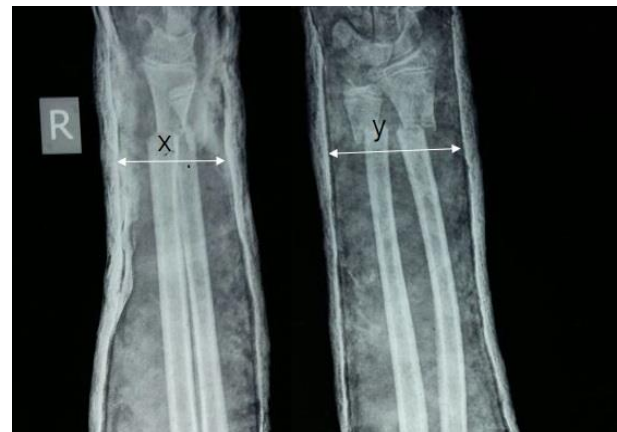

Figure 1: Calculating the cast index.

Padding index and canterbury index

The Padding index and Canterbury index were designed by Bathia and Housden to help in the assessment of the cast technique for treatment of both diaphyseal and distal metaphyseal forearm fractures in children.⁶ It is calculated as Padding index= dorsal gap at fracture site in lateral view/ maximum interosseous space in AP X-ray view. Canterbury index is the sum of Cast index and Padding index (Figure 2).

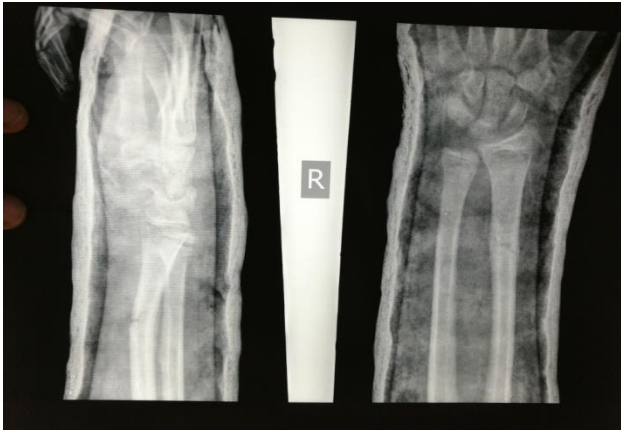

Figure 2: Calculating the padding index.

Gap index

The Gap index is a recently defined radiographic measurement by Malviya et al based on ratios of the gaps in the cast at the level of the fracture to the entire inside width of the cast in two planes (Figure 3).⁷

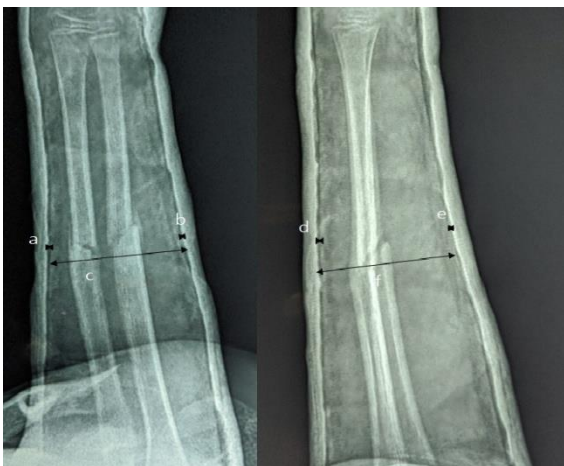

Figure 3: Calculating the gap index.

Gap index = [(radial gap at fracture site) + (ulnar gap at fracture site)/inner diameter of cast in AP view] + [(dorsal gap at fracture site) + (volar gap at fracture site)/inner diameter of cast in lateral view]

- (a) Is the radial gap at the fracture site in AP view
- (b) Is the ulnar gap at the fracture site in AP view
- (c) Is the inner diameter of the cast in AP view
- (d) Is the dorsal gap at the fracture site in lateral view
- (e) Is the volar gap at the fracture site in lateral view
- (f) Is the inner diameter of the cast in lateral view

Three point index

The three point index was recently defined by Alemdaroglu et al, can be used in predicting redisplacement of extraarticular distal end radius

fractures and differs from the other indices because it not only takes into account the gaps at the fracture site, it also uses the gaps proximal and distal to the fracture sites, which are important points to maintain reduction against common displacement forces (Figure 4).⁸

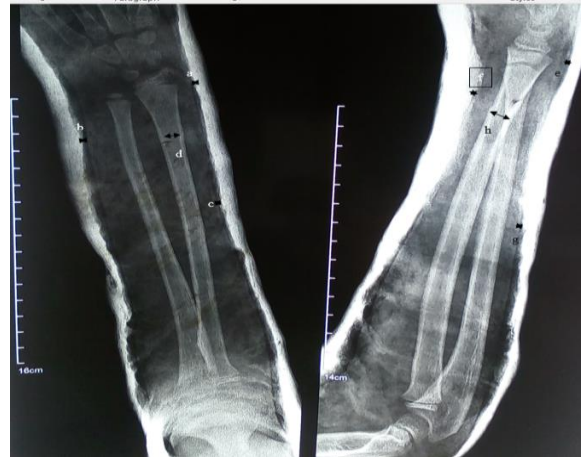

Figure 4: Calculating the three point index/

It is determined by:

[(distal radial gap + ulnar gap at fracture site) + proximal radial gap/ transverse distance of cortical contact on AP plane] + [(distal dorsal gap + distal volar gap at fracture site) + proximal dorsal gap/transverse distance of cortical contact on lateral plane]

- (a) Is the distal radial gap on AP view
- (b) Is the ulnar gap at the fracture site on AP view
- (c) Is the proximal radial gap on AP view
- (d) Is the transverse distance of cortical contact in AP view
- (e) Is the distal dorsal gap on lateral view
- (f) Is the volar radial gap at the fracture site
- (g) Is the proximal dorsal gap on lateral view
- (h) Transvers distance of cortical contact on lateral view.

Data collection and data analysis

Data were compiled and analysed in SPSS version 23 (IBM, New York). The qualitative variables were described in percentages and the quantitative variables were expressed in mean values with standard deviation. The Student t-test for paired samples was used to evaluate the differences between the mean values measured by the two observers. We tested normality of the data using the Shapiro Wilk test.

We used Repetitive Measurement Variance Analysis or the Friedman test to determine whether the casting indices had statistically significant changes over the period of assessment. We accepted a value of p<0.05 as statistically significant.

RESULTS

Of the 30 children enrolled in the study, 18 were males. Mean age of the patients was 8.86±2.56 years, ranging from 5 years to 14 years. Most common type of forearm fracture noted with midshaft ulnar fracture at 47% followed in a decreasing order of occurrence by midshaft radius fracture at 20%, midshaft radius ulna at 17% distal radius fracture at 10% and 3% each for proximal ulna & distal ulna fracture (n=14) (Figure 5). Cast Index ranged from 0.80±0.09 at first week to 0.78±0.09 at 6 weeks, without any significant change (p value =0.66) (Table 1). Padding Index was 0.30±0.04 at first week and increased to 0.31±0.03 at 6 weeks, though the change was statistically not significant (p value =0.66). Canterbury Index was 1.07±0.24 at first week and 1.07±0.78 at 6 weeks, demonstrating no significant change during the study period. Similarly, Gap Index also showed no significant change during the course of observations (p value =0.64). Lastly, Three Point Index changed insignificantly from 0.81±0.08 at first week post-

operatively to 0.77±0.18 six weeks post-operatively. Furthermore, radial bow of children showed no significant change at various time points of assessment.

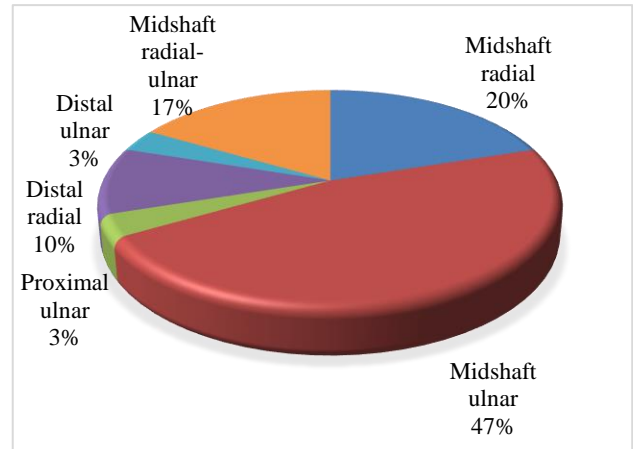


Figure 5: Distribution of patients according to the type of their forearm fracture.

Table 1: Comparing various casting indices assessed at different time points.

Index	Assessment time point				P value*
	1 week	2 weeks	3 weeks	6 weeks	
Cast index	0.80±0.09	0.79±0.08	0.79±0.087	0.78±0.09	0.66
Padding index	0.30±0.04	0.29±0.03	0.29±0.03	0.31±0.03	0.66
Canterbury index	1.07±0.24	1.08±0.08	1.07±0.05	1.07±0.78	0.67
Gap index	0.15±0.02	0.15±0.02	0.15±0.02	0.15±0.02	0.64
Three Point index	0.81±0.08	0.81±0.12	0.081±0.12	0.77±0.18	0.66

Rotational mal-alignment was observed in 5 patients, 2 had mid-shaft ulnar fracture while 3 patients had mid-shaft radio-ulnar fracture, maximum rotation being 5 degrees. One patient with mid- shaft radius and mid-shaft ulnar fracture showed 0.5 cm radial overlap on AP X-ray, while none had ulnar overlap. On AP X-ray, five patients showed radial angulation, of which 3 had mid-shaft radius ulna fracture, 1 had mid- shaft radius fracture while 1 had distal radius fracture, maximum radial angulation being 30 degrees and minimum as 5 degrees. On lateral X-ray, 6 children showed radial angulation, 4 with midshaft radius ulnar fracture, 1 was with mid-shaft radius fracture and 1 was with distal radius fracture, maximum angulation being 25 degrees with a minimum of 5 degrees. Ulnar angulation was seen in 2 children on AP X-ray while 1 child showed ulnar angulation on lateral X-ray. Radial displacement was seen on AP X-ray in 3 children with mid-shaft radius fracture and 1 child with mid-shaft radius-ulnar fracture showed radial displacement. The maximum displacement seen was 100% in one of the child at first, second and third week and minimum was 5% at 3 weeks. On lateral X-ray, 3 children showed radial displacement with 2 of these having mid-shaft radioulnar fracture and 1 child having mid- shaft radius fracture. The maximum displacement on lateral X-ray was 100%, seen in 1 child while one

child showed 50% displacement at the first, second week and 40% at third week and one child showed displacement of 10% at first week and 5% displacement at second and third week. Ulnar displacement was seen in 2 children with mid-shaft ulnar fracture and 1 child with proximal ulnar fracture on AP X-ray. Both the mid-shaft fractures showed 100% displacement while the third child showed 25-degree displacement till 2 weeks. None of the children showed ulnar displacement on lateral X-ray.

DISCUSSION

Success of conservative management of pediatric forearm fractures depends on meticulous casting techniques and ensuring reduction and measurements of various casting indices are maintained on each weekly follow up visit. All cases in our study were treated conservatively with closed reduction and application of plaster cast for a period of 6 weeks. Union was achieved in all cases. Acceptable reduction was achieved in 26 cases in which various casting indices were maintained within the normal limits with no loss of reduction on subsequent visits. In the remaining 4 cases, re-manipulation was done to achieve acceptable reduction. Re-displacement within the cast is the most common complication of closed

method. Quality of manipulation and cast application is viewed as an important modifiable risk factor for re-displacement. Among the long list, cast-index was the first casting index to be used clinically.

Chess and colleagues, who described the CI for the first time, recommended CI of 0.7, which in our study ranged from 0.80 ± 0.09 at first week to 0.78 ± 0.09 at 6 weeks. Bohm et al found no difference in re-displacement rates of below elbow versus above elbow casts based on CIs above or below 0.70.⁹ A randomized controlled trial by Webb et al concluded that adequate reduction is maintained with a CI of 0.71.¹⁰ The mean CI in their study was 0.79 ± 0.07 for children requiring re-manipulation. Sheikh et al hypothesized that CI of less than 0.8 is more difficult to achieve in the proximal forearm but that this does not necessarily adversely affect the risk of fracture re-displacement.¹¹ This is based on the fact that proximal forearm has more soft tissue as compared with the distal forearm and therefore a cast that is more elliptical in cross section is less likely. However, a "less elliptical" proximal forearm cast (i.e., one with a higher CI) may still provide adequate three-point fixation. Though not investigated in the present study, weight of the children also has an effect on the CI. Kamath et al in his study concluded that in addition to obesity, excessive padding and soft tissue swelling could allow re-displacement.¹² Similar observations were made by Malviya et al who suggested that in young normally chubby children there is very little control over this otherwise useful tool.

The gap index, padding index and their sum the Canterbury index are other popular indices. Bhatia and Housden, who came up with the padding and Canterbury index suggested that fractures with a CI of >0.8 , a padding index of 0.3, and a Canterbury index of 1.1 are more prone to re-displacement. The authors also acknowledged that the gap index was more sensitive, while CI and padding index showed more specificity. Similar observations were made by Labronici et al.¹³ However, on comparison padding had superior properties like a lower false result rate, higher sensitivity, higher positive predictive value, and lower negative likelihood ratio as compared to Canterbury index. Furthermore, the authors concluded that the three-point index and the Canterbury index were unnecessary, as the authors calculated that in 79% of cases, the cast and gap indices will suffice to predict the possibility of loss of reduction after manipulation of paediatric distal forearm fractures.

There are a few limitations of our study. Observing a small patient population for a short duration may introduce bias, though the objectivity of these indices is well established. Also we did not take in to consideration the level and severity of fracture, involvement of a single or both forearm bones, and the fracture configuration while assessing the outcomes. Anthropometric parameters like child's weight and diameter of the

forearm, which may be confounding, were also not included in the analysis.

CONCLUSION

Our data show that casting is an excellent method of treating forearm fractures provided a well moulded cast is applied. Serial evaluation of x-rays confirming normal limits of various casting indices helped us in confirming the maintenance of fracture reduction within the cast.

Funding: No funding sources

Conflict of interest: None declared

Ethical approval: The study was approved by the institutional ethics committee

REFERENCES

1. Landin LA. Epidemiology of children's fractures. *J Pediatr Orthop B*. 1997;6:79-83.
2. Devalia KL, Asaad SS, Kakkar R. Risk of redisplacement after first successful reduction in paediatric distal radius fractures: sensitivity assessment of casting indices. *J Pediatr Orthop B*. 2011;20:376-81.
3. Zamzam MM, Khoshhal KI. Displaced fracture of the distal radius in children: factors responsible for redisplacement after closed reduction. *J Bone Joint Surg Br*. 2005;87:841-3.
4. Charnley J. The closed treatment of common fractures. Baltimore: Williams and Wilkins; 1968.
5. Chess D, Hyndman J, Leahey J, Brown D, Sinclair A. Short Arm Plaster Cast for Distal Paediatric Forearm Fractures. *J Paedi Orthop*. 1994;14(2):211-3.
6. Bhatia M, Housden P. Redisplacement of paediatric forearm fractures: Role of plaster moulding and padding. *Injury*. 2006;37(3):259-68.
7. Malviya A, Tsintzas D, Bache C, Gibbons P, Glithero P. Gap index-A good predictor of failure of plaster cast in distal forearm fractures. *Injury Extra*. 2007;38(1):11-12.
8. Alemdaroğlu K, İltar S, Aydoğan N, Say F, Kılınc C, Tiftikçi U. Three-point index in predicting redisplacement of extra-articular distal radial fractures in adults. *Injury*. 2010;41(2):197-203.
9. Bohm ER, Bubbar V, Yong-Hing K, Dzus A. Above and below-the-elbow plaster casts for distal forearm fractures in children: a randomized controlled trial. *JBJS*. 2006;88(1):1-8.
10. Webb GR, Galpin RD, Armstrong DG. Comparison of short and long arm plaster casts for displaced fractures in the distal third of the forearm in children. *J Bone Joint Surg Am*. 2006;88:9-17.
11. Sheikh HQ, Malhotra K, Wright P. Cast index in predicting outcome of proximal pediatric forearm fractures. *Indian journal of orthopaedics*. 2015;49(4):398.
12. Kamat AS, Pierse N, Devane P, Jonathan Mutimer J, Horne G, et al. Redefining the Cast Index: The

Optimum Technique to Reduce Redisplacement in Pediatric Distal Forearm Fractures. *J Pediatr Orthop.* 2012;32:787–91.

13. Labronici PJ, Ferreira LT, dos Santos Filho FC, Pires RE, Gomes DC, da Silva LH, et al. Objective assessment of plaster cast quality in pediatric distal forearm fractures: Is there an optimal index?. *Injury.* 2017;48(2):552-6.

Cite this article as: Kharbamon P, Sheth BA, Pawar P, Parekh S, Jaiswal R, Kanade U. Importance of calculating various casting indices in predicting radiological outcomes of paediatric forearm fractures. *Int J Res Orthop* 2020;6:1016-21.