

Original Research Article

A study of surgical management of idiopathic congenital talipes equinovarus by posteromedial soft tissue release

T. Parameshwari¹, Ketavath Thulasiram^{1*}, D. Narender¹, N. Kalyani², Anjaneyulu K.³

¹Department of Orthopaedics, Government Medical College, Mahbubnagar, Telangana, India

²Civil Assistant Surgeon, TSVVP District Hospital, Tandur, Telangana, India

³Department of Orthopaedics, S. V. S. Medical College, Mahbubnagar, Telangana, India

Received: 14 May 2020

Revised: 30 June 2020

Accepted: 01 July 2020

*Correspondence:

Dr. Ketavath Thulasiram,

E-mail: tulasi9984@gmail.com

Copyright: © the author(s), publisher and licensee Medip Academy. This is an open-access article distributed under the terms of the Creative Commons Attribution Non-Commercial License, which permits unrestricted non-commercial use, distribution, and reproduction in any medium, provided the original work is properly cited.

ABSTRACT

Background: Idiopathic congenital talipes equinovarus is a complex deformity that is difficult to correct. The treatment of club foot is controversial and continues to be one of the biggest challenges in paediatric orthopaedics. Most orthopaedicians agree that the initial treatment should be non-surgical but if it fails, advise surgical treatment in the form soft tissue release for better results. The study was done with the aim to study a short term follow up of 14 patients treated to assess the efficacy of the treatment modality.

Methods: 14 patients underwent the posteromedial soft tissue release (PMSTR) at Department of Orthopaedics, S. V. S. Medical College during the period from October 2013 to September 2015. Patients were followed up regularly up to one and half year. Severity of foot deformities were graded according to Denis-Brown classification.

Results: Out of 14 cases there were 10 males (71.4%) and 4 females (28.6%) for the sex ratio of 2.5:1 male to female. The youngest child was 6 months old and oldest child was 3 years old. In bilateral cases both feet were operated at an interval of 7 to 10 days. Good results were seen in 15 feet (71%), fair: in 04 feet (19%) and poor: in 02 feet (10%).

Conclusions: The PMSTR method is a safe and cost-effective treatment for congenital idiopathic clubfoot and radically decreases the need for extensive corrective surgery. Non-compliance with orthotics after surgery and surgery at late age are causes for failure of technique.

Keywords: Idiopathic clubfoot, PMSTR, Hemi-cincinnati incision

INTRODUCTION

Club foot is a rather vague term which has been used to describe different abnormalities, but over the years it has become synonymous with commonest congenital talipes equinovarus (CTEV). Club foot is classified into two major groups; idiopathic club foot where aetiology is not known in vast majority of cases and secondary club foot where some underlying cases such as arthrogryposis multiplex congenita (AMC) can be found.¹

In addition to foot examination, a general examination should be carried out to detect associated malformations in

other parts of the body. Normally, the foot of a new born child can be dorsiflexed until the dorsum touches the anterior aspect of the shin of the tibia. This is a good screening test for detecting the milder variety of club foot.²

With regards to management, treatment consists of correction of deformity, and its maintenance. Correction can be achieved by non-operative or operative methods. Maintenance is continued until the foot grows to a reasonable size, so that deformity does not recur. Methods of correction of deformity can be non-operative or operative.³

Non-operative methods can be manipulation alone or manipulation and Plaster of Paris (PoP). Under manipulation and PoP, there are two philosophies of treatment; Kite's and Ponsetti's. In more severe deformities which are not corrected by conservative methods or in those that recur, operative treatment is required. Soft tissue release operations may be sufficient in younger children (younger than 3 years), but bony operations are required in elder children. The following operations are performed; postero-medial soft tissue release (PMSTR), limited soft tissue release, tendon transfers, Dwyer's osteotomy, Dilwyn-Evan's procedure, Wedge tarsectomy, triple arthrodesis and Ilizarov's technique.

Over the years many different forms of treatment ranging from gentle manipulation and strapping, serial plaster corrections, forcible manipulations including the use of mechanical devices to surgical correction have been tried.

Although some success with non-surgical treatment has been reported in the literature, results have often been less than optimal, with partial corrections, recurrence and other complications.⁴⁻⁸ This has led to a trend toward surgical intervention, usually within the first year of life.⁹⁻¹³ However, surgical treatment also carries significant risks, and the potential for complications is great.

There has been much debate in the past as to whether a conservative or operative treatment was more effective in the treatment of clubfoot. Those feet usually which have had numerous manipulations and operations are stiff, deformed and rigid due to scar tissue formation.

The study centres around the surgical management of CTEV by postero medial soft tissue release through hemi-cincinnati approach.

Objectives

To study the results achieved by surgical management of idiopathic CTEV by posteromedial soft tissue release. To correct the deformity, so that the child has a foot of normal shape and full mobility with a plantigrade, pliable and cosmetically acceptable foot by the time the child attains the age of walking.

METHODS

Clinical material

This clinical study was conducted in the Department of Orthopaedics, S. V. S. Medical College, Mahbubnagar, Telangana State between July, 2013 and December 2015. During this period, 21 feet of 14 patients were studied.

The study was conducted with due emphasis for clinical observation and analysis of results after the surgical management of congenital talipes equinovarus by posteromedial soft tissue release.

Inclusion criteria

Inclusion criteria were children of age 6 months to 3 years having only idiopathic and atypical moderate and severe club foot. Deformities that don't respond to conservative treatment by serial manipulation and casting. All patients of CTEV, who are treated with ponseti method but deformities recurred.

Exclusion criteria

Exclusion criteria were patients of CTEV, who are treated with ponseti method with satisfactory correction, residual or resistant club foot in older children, club foot secondary to cerebral palsy, arthrogryphosis multiplex congenita, myelodysplasia (or) congenital dislocation of hip. Patients unfit for surgery.

Method of selection

A detailed history is elicited from the patient's parents including consanguinity, laterality, and position of child in family, antenatal history, other congenital deformities and family history of clubfoot.

All the feet were graded according to the severity of deformity based on Denis-Brown classification.¹⁴

- *Grade I:* Adduction of forefoot.
- *Grade II:* Adduction with inversion of whole foot and equines deformity.
- *Grade III:* Adduction of forefoot with inversion of whole foot, but no equines.

In this study out of 21 feet, 12 feet were graded as grade II and 9 feet as grade III. Feet with grade I deformity were not included in this study. All cases were treated surgically, after failure of conservative treatment. No case has undergone any previous surgery.

The minimum age at the time of surgery was 6 months and maximum age was 3 years. A preoperative assessment of patients was done by clinical evaluation.

Clinical examination

Clinical examination was done in the order of inspection, palpation, measurements, movements, associated congenital abnormalities and special tests dorsiflexion test, plumb line test and scratch test.¹⁵

Investigations

Routine examination of blood including TC, DC, ESR, Hb%, CT, BT. Routine urine examination, HIV-I, II and HBsAg were done in all patients.

Surgical technique

Patients were given general anaesthesia, and placed in supine position with limb flexion and external rotation, tourniquet; pneumatic tourniquet.

Incision

Hemi-cincinnati incision was medial half of the cincinnati incision starting from base of first metatarsal and stopping at just short of achilles tendon.

The tendo achilles, tibialis posterior, flexor digitorum longus, flexor hallucis longus and abductor hallucis were identified and exposed. The neurovascular bundle was located and protected. Superficial deltoid ligament and Spring ligament were released. The contracted tendons like tendo achilles, tibialis posterior, flexor digitorum longus and flexor hallucis longus were lengthened by Z-plasty and Abductor hallucis was identified and tenotomy done.

Posterior capsulotomy of ankle and subtalar joints was done. Master knot of Henry was identified and incised by tracing the flexor hallucis longus and flexor digitorum longus. Talonavicular joint was identified and capsulotomy done. Naviculo cuneiform, cuneiform first metatarsal joints capsulotomies were performed according to the severity of deformities. Intraoperative assessment of the correction was done.

Throughout the surgery normal saline soaked gauze pieces applied over surgical site to keep the field moist. Wound closed in layers after securing haemostasis. Sterile dressings applied. A well-padded above knee cast was applied with knee in 90° flexion and foot in held in plantigrade for two weeks.

Two weeks after surgery wound inspection was done and sutures removed. POP changed; foot was manipulated into maximum dorsiflexion and eversion for period of 3 months. Casts were changed once in 4 weeks for a period of 3 months. Patients were advised to wear Tarso pronator shoes continuously (for 24 hours except at the nape time and bathing). When the child started walking, we encourage to do so with CTEV boots.

The parents were informed to bring their child for follow up at 4 months, 8 months, 12 months and 18 months. At follow up all children were examined for limitation of foot mobility, residual deformities and recurrence of deformities.

Atrophy of calf muscles, small size of clubfoot and leg length discrepancy are not considered as these are part of the natural history of clubfoot.

In this study, for all bilateral cases of CTEV, we performed surgery on the second foot at an interval of 7-10 days.

Ethical considerations

Institutional ethics committee approval was taken prior to the start of the study from medical ethics committee, S. V. S. Medical College, Mahbubnagar. Informed written consent was taken from parents.

Statistical analysis

Data entry and analysis was done using Microsoft excel 2010 version. Data was presented in percentages and proportions.

RESULTS

Out of 14 cases there were 10 males (71.4%) and 4 females (28.6%) for the sex ratio of 2.5:1 male to female. Children were equally distributed in two categories; the youngest age is 6 months while old age stage 3 years. A positive family history was found in 1 patient (7.1%). No history of twins was observed in our series. All cases were full term normal delivery with no complications. No other associated congenital deformity was detected in present study.

Out of 14 cases, 7 cases showed bilateral (50%) and 7 cases unilateral (50%). In unilateral cases out of 7, right foot was involved in 4 cases (57%) and left foot in 3 cases (43%).

Age at surgery

The youngest child was 6 months old and oldest child was 3 years old. In bilateral cases both feet were operated at an interval of 7 to 10 days.

Follow up

Duration of follow up ranges from 3 months to 16 months with an average period of 11 months.

Complications

Skin necrosis; we had two feet with this complication, ended up with fair/poor result. Due to superficial infection. Plaster sores; one foot had plaster sore in our series which eventually healed without scarring. Residual deformities; two feet had mild residual varus. Over correction and pes planus; no patient had this complication in our series. Calcaneus deformity; study did not have this complication.

Final outcome

During the follow up period, each foot was evaluated cosmetically and functionally and rated accordingly. Good- clinically well aligned foot, no residual or very minimal adduction deformity and ankle dorsiflexion of more than 10° above the normal and ability to evert the foot to neutral position. Fair- correction acceptable in appearance with minimal residual deformity, ability to

dorsiflex the ankle to neutral position. Poor- activity limited residual deformity such as hindfoot, adduction, heel varus, inability to dorsiflex and evert the foot to neutral position etc.

Table 1: Demographic characteristics.

Demographic characteristic	Number	Percentage
Sex distribution		
Male	10	71.4
Female	04	28.6
Age distribution in months		
<9	07	50
≥9	07	50
Family history		
Present	01	7.1
Absent	13	92.9

Table 2: Clinical characteristics.

Clinical characteristic	Number	Percentage
Laterality		
Bilateral	07	50
Unilateral	07	50
Unilateral series		
Right side	04	57
Left side	03	43
Grades		
	Number of feet	
II	12	57.2
III	09	42.8

Table 3: Final results.

Results	No. of feet	Percentage
Good	15	71
Fair	04	19
Poor	02	10
Total	21	100

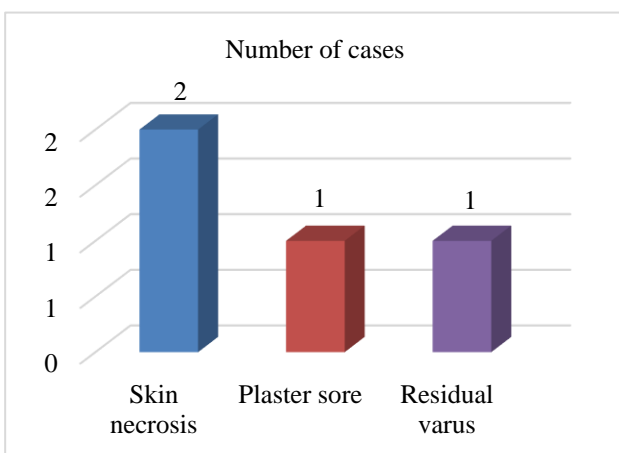


Figure 1: Complications.

In present study results were good in 15 feet (71%), fair in 04 feet (19%) and poor in 02 feet (10%). In our study it was observed that the results in the early age group 6-9 months are good when compared to the older age group. In early age group 13 feet were operated, 10 feet had good correction (77%). In older age group (above 9 months old), out of 18 feet 5 had good result (62.5%).

DISCUSSION

Clubfoot or congenital talipes equinovarus constitutes one of the more commonly presenting paediatric problems in orthopaedic Out Patient department.

A clinical study on one of the most common congenital deformity of foot i.e., CTEV was carried out in the Department of Orthopaedics, S. V. S. Medical College, Mahbubnagar to evaluate the results of the surgical management of idiopathic CTEV by posteromedial soft tissue release. In total, there were 14 children treated by posteromedial soft tissue release.

When the feet were divided on the basis of the age, it was seen that a large proportion of patients were below 9 months. The youngest patient who was included in this study was 6 months, the elder age 3 years. In our study there were 10 (71.4%) males and 4 females (28.6%) and the sex ratio of 2.5 males to 1 female. Incidence of males and females in present study is not very different from other reported studies. Rijal et al reported 76.2% males and 33.8% females.¹⁶ Changulani et al reported 75.7% males and 24.3% females.¹⁷

In our study there were 10 male and 4 female children i.e., 71.4 and 28.6 respectively which are in accordance with other studies.

As regards laterality, 7 of our cases were bilateral 50% and 7 were unilateral 50%. Rijal et al in their study reported 57.89% bilateral and 68.75% unilateral.¹⁶ Changulani et al in their study reported 52% bilateral and 48% unilateral.¹⁷

In the present study positive family history was ascertained in 14.88% of patients. However, review of literature revealed that the percentage of positive family similar incidence of 17.9% of positive family history has been observed by Turco.⁸

On the other hand, Morcuende et al has reported 22% patients having a positive family history of club foot deformity.³ During surgery we identified master knot of Henry below the navicular bone where FHL and FDL crossing each other. FHL, FDL and tibialis posterior muscles were identified and lengthened by Z-plasty. For correction of forefoot adduction and supination (cavus) release plantar fascia and abductor hallucis brevis was done. Subtalar, naviculocuneiform and ankle capsules are released.

After removal of last cast a foot abduction orthosis is prescribed to prevent recurrence of deformity to favour remodelling of joints with the bones in proper alignment. The orthosis consists of two straight last opened toe shoes connected by a bar that allows the shoes to be placed at shoulder width. The bar should hold the shoes at 70° of external rotation and 5-10° of dorsi flexion. In unilateral cases the normal foot lies at 40° external rotation. Maintaining the feet at shoulder width facilitates feet adduction. The orthosis is worn full time for at least 3-4 months, and after it is worn at night times for 2-4 years.

Compliance with the foot abduction brace has also been an issue. Those patients compliant with foot abduction brace wear had 100% success at final last follow-up. Non-compliance of children with foot abduction bar and even with clubfoot splints or foot as well as low educational level of parents are important factors to predict relapse after the surgical treatment.

Four patient's developed complications in the form of skin necrosis in two feet which are due to superficial infection, one patient developed plaster sore and one foot developed residual hand foot varus.

The results of our study were good in 71%, fair in 19%, poor in 10%. Turco has a result of excellent and good in 86%, fair in 9% and poor in 5%.⁸

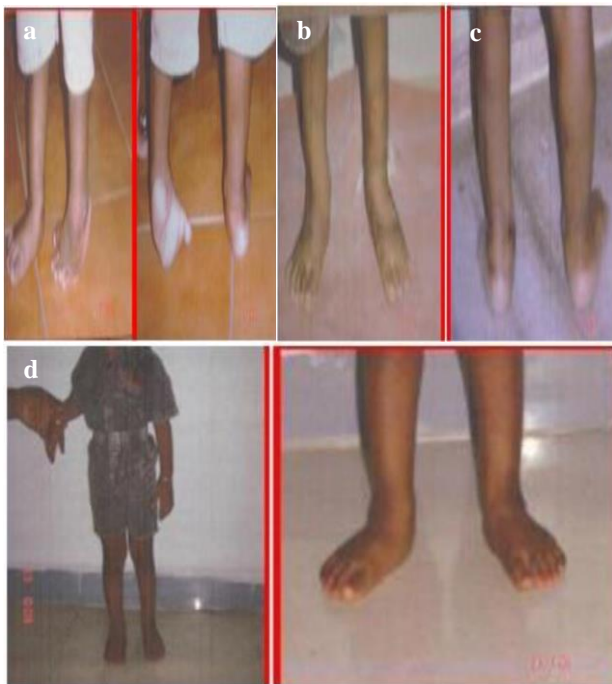

Figure 2: (a) Pre-operative, (b) 3 months follow-up, (c) 6 months follow-up and (d) 1 and half year's follow-up good correction.

We have not used the radiographic evaluation for assessing the correction because there is wide range of variations within the limits of normal. Normal values vary depending on the child's age.

Drawing lines through the middle of a small ossified mass is inaccurate especially since the mass is not necessarily the centre of the bone.

Furthermore, the positions of beam, the degree of dorsiflexion or plantar flexion and the adduction significantly affect measurements. We feel that counselling of parents is important to maintain regular follow-up and prevent relapse.

CONCLUSION

If the children with CTEV are treated early i.e., before he/she starts walking and bony changes appear, posteromedial soft tissue release with proper follow up and splinting gives a cosmetically normal looking and functionally acceptable pain free foot as seen in the study performed.

Identifying of master knot of Henry is a must to release Flexor hallucis longus and Flexor digitorum longus where these two tendons are crossing each other. Peri navicular release, subtalar and ankle capsulotomies are also important for full correction of deformities. The choice of treatment depends on various factors. The treating doctor has to assess the deformities and decide the treatment modality which is best suited for that patient. Duration of the study is not sufficient to predict the long-term results but early results are certainly encouraging. Maintenance of the corrected deformity with moulded orthosis is as important as deformity correction, parent motivation and compliance are very important for successful correction the deformity. Present study reveals that posteromedial soft tissue release for clubfoot is simple, safe and effective procedure.

Funding: No funding sources

Conflict of interest: None declared

Ethical approval: The study was approved by the institutional ethics committee

REFERENCES

1. Ponseti I, Jose A. Morcuende, Vincent Mosca, Shafique Pirani. Fred Dietz, John E. Herzenberg, Stuart Weinstein, Norgrove Penny, Michiel Steenbeek. Clubfoot: Ponseti Management, 2nd edition, Global- Help Publication; 2005.
2. Cummings JR, Davidson RS, Armstrong PF, Lehman W. Congenital clubfoot. J Bone Joint Surg Am. 2002;84(2):290-308.
3. Morcuende JA, Dolan LA, Dietz FR, Ponseti IV. Radical reduction in the rate of extensive corrective surgery for clubfoot using Ponseti method. J Pediatrics. 2004;113:376-80.
4. Aronson J, Puskarich CL. Deformity and disability from treated clubfoot. J Pediatr Orthop. 1990;10:109-19.

5. Karski T, Wosko I. Experience in the conservative treatment of congenital clubfoot in newborns and infants. *J Pediatr Orthop.* 1989;9:134-6.
6. Wesely MS, Barenfeld PA, Barrett N. Complications of the treatment of clubfoot. *Clin Orthop.* 1972;84:93-6.
7. McKay DW. New concept of and approach to clubfoot treatment: section-II correction of the clubfoot. *J Pediatr Orthop.* 1983;3:10-21.
8. Turco VJ. Resistant congenital clubfoot: one-stage posteromedial release with internal fixation: a follow-up report of a fifteen-year experience. *J Bone Joint Surg Am.* 1979;61:805-14.
9. Crawford AH, Marxen JL, Osterfeld DL. The Cincinnati incision: a comprehensive approach for surgical procedures of the foot and ankle in childhood. *J Bone Joint Surg.* 1982;64A:1355-8.
10. Carroll NC, Gross RH. Operative management of clubfoot. *Orthopedics.* 1990;13:1285-96.
11. Ippolito E, Fraracci L, Farsetti P. The influence of treatment on the pathology of clubfoot - CT study at maturity. *J Bone Joint Surg Br.* 2004;86(4):574-80.
12. Hutchins PM, Foster BK, Paterson DC, Cole EA. Long-term results of early surgical release in clubfeet. *J Bone Joint Surg Br.* 1985;67:791-9.
13. Cooper DM, Dietz FR. Treatment of idiopathic clubfoot: a thirty-year follow-up note. *J Bone Joint Surg Am.* 1995;77:1477-89.
14. Browne D. The pathology and classification of talipes. *Aust N Z J Surg.* 1959;29:85-91.
15. Catterall A. Clinical Assessment of Clubfoot Deformity. In: Simons G.W. (eds) *The Clubfoot.* New York, NY: Springer; 1994.
16. Rijal R, Shrestha BP, Singh GK. Comparison of Ponseti and Kite's method of treatment for idiopathic clubfoot. *Indian J Orthop.* 2010;44(2):202-7.
17. Changulani M, Garg NK, Rajagopal TS, Boss A, Nayagam SN, Sampath J, et al. Treatment of idiopathic clubfoot using the Ponseti method. *J Bone Joint Surg Br.* 2006;88:1385-8.

Cite this article as: Parameshwari T, Thulasiram K, Narender D, Kalyani N, Anjaneyulu K. A study of surgical management of idiopathic congenital talipes equinovarus by posteromedial soft tissue release. *Int J Res Orthop* 2020;6:933-8.